

Müller Cells as Players in Retinal Edema

Triamcinolone may stimulate fluid absorption from the retinal tissue.

BY ANDREAS BRINGMANN, MD

Macular edema is a major cause of vision loss. The accumulation of water within the macular tissue and in the subretinal space is associated with functional impairment of photoreceptors and retinal neurons. Water may accumulate within retinal cells (cytotoxic edema characterized by cellular swelling) and in interstitial spaces (extracellular edema resulting in cell compression). Systemic and retinal factors may contribute to the development of macular edema. Systemic disorders result in inflow of excess water

from the blood into the retinal tissue, either by increase in hydrostatic pressure (hypertension) or decrease in blood osmolarity (eg, in cases of hyponatremia and hypoalbuminemia).¹ Main retinal factors are ischemia-hypoxia (associated with oxidative stress) and local inflammation.²

VASCULAR LEAKAGE VS IMPAIRMENT IN FLUID CLEARANCE

Retinal ischemia-hypoxia and inflammation are associated with release of factors that promote breakdown of

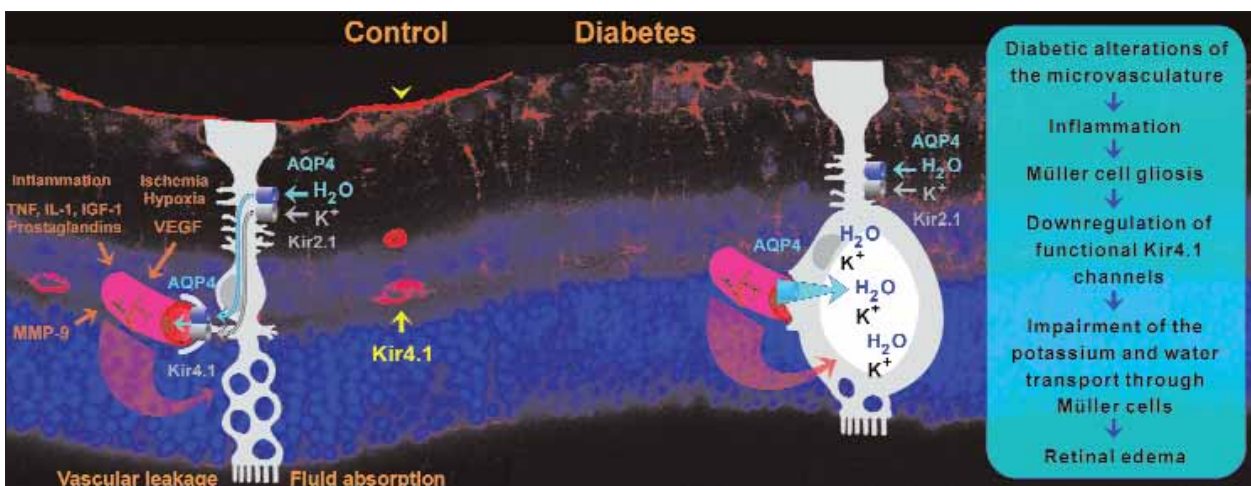


Figure 1. Disruption of Müller cell-mediated fluid clearance and (under certain conditions) Müller cell swelling may contribute to the development of diabetic retinal edema. In a rat model of diabetic retinopathy, the major potassium channel of Müller cells (Kir4.1), which is normally expressed around the retinal vessels (yellow arrow) and at the inner limiting membrane (yellow arrowhead) is downregulated. This disrupts the water transport through the cells, which is facilitated by water channels (AQP4), and coupled to potassium currents through potassium channels (Kir2.1, Kir4.1). Accumulation of potassium within the cells increases the intracellular osmotic pressure, resulting in water influx into the cells and cellular swelling.

the blood-retinal barrier (vascular endothelial growth factor [VEGF], various inflammatory factors, and matrix-metalloproteinases). Blood-derived fluid moves across the leaky pigment epithelium and vessel walls into the tissue (vasogenic edema). Generally, water accumulation within the retinal tissue results from an imbalance between the rate of fluid inflow into the retinal tissue and the rate of fluid absorption from the retina into the blood. It has been suggested that anomalies in vessel permeability must be accompanied by ineffective edema-resolving mechanisms to result in chronic edema. An impairment in the fluid-clearance mechanisms is a major cause of macular edema in patients without angiographic vascular leakage.² Diabetic macular edema develops when the active transport mechanisms of the blood-retinal barrier are dysfunctional.³

FLUID ABSORPTION FROM THE RETINAL TISSUE

Under normal conditions, water accumulates in the retinal tissue due to various reasons, including the uptake of nutrients from the blood, which is associated with water inflow into the tissue, and the production of water in the course of aerobic energy production. (The oxidative breakdown of one molecule of glucose results in the formation of 42 molecules of water.) The accumulation of metabolic water is strongest in the macular tissue because of the high density of highly metabolically active photoreceptors. Of all the cells of the body, photoreceptor cells probably have the highest rate of oxidative metabolism. There is a continuous redistribution of metabolic water from the retinal tissue into the blood carried out by Müller cells, which dehydrate the retinal parenchyma, and pigment epithelial cells, which dehydrate the subretinal space. The water transport through Müller and pigment epithelial cells is osmotically driven by transcellular currents of osmolytes, especially of potassium ions. To facilitate the transport process, the cells express potassium- and water-selective channels (aquaporins) in their membranes.

DYSFUNCTION OF MÜLLER CELLS

Chronic macular edema is characterized by an impairment in the fluid clearance from the retinal tissue. Because Müller cells dehydrate the retinal tissue, we determined the properties of the cells in animal models of various retinopathies known to be associated with development of edema (eg, ischemia,⁴ ocular inflammation, diabetes,⁵ and blue-light evoked retinal degeneration).⁶ We found that in all these cases the potassium currents across the Müller cell membranes are strongly

The observation that triamcinolone acetonide resolves macular edema also in patients who do not display angiographic vascular leakage suggests that it stimulates the fluid absorption from the retinal tissue.

decreased due to the downregulation of potassium channels, which are normally localized to Müller cell membranes that surround the blood vessels. An impairment of the potassium transport through Müller cells should also disrupt the regular osmotically driven water transport through the cells and, thus, the fluid clearance from the retinal tissue. We investigated the water transport across Müller cell membranes in osmotic cell swelling experiments. We found that Müller cells in tissue slices of pathologically altered retinas displayed cellular swelling during superfusion with a hyposmolar solution, whereas Müller cells of control retinas do not swell under such osmotic stress conditions. The swelling of Müller cells, which is not seen under normal conditions, reflects an alteration in the water transport through the cells. The results suggest that a disturbance in the potassium and water transport through Müller cells contributes to the development of retinal edema. Are these results applicable to the human situation? We found in preliminary experiments using retinal tissues from patients with choroidal melanoma that Müller cells with reduced potassium currents display osmotic swelling, while cells with normal potassium currents do not swell under osmotic stress conditions. An age-related decrease in potassium channel expression of human Müller cells⁷ may contribute to the higher incidence of macular edema in the elderly. In cases of macular edema caused by systemic disorders, a considerable amount of water that flows into the retinal parenchyma will directly move into the Müller cells, because the perivascular processes of Müller cells fill most of the space around the blood vessels. Under these conditions, the water flow from the blood into the tissue may overtax the capability of Müller cells to clear the retina from excess water.

MÜLLER CELL SWELLING

Impaired fluid clearance may result in cytotoxic edema characterized by cellular swelling. In the ischemic retina, both a rapid neuronal cell swelling and a slow Müller cell swelling were suggested to contribute to the

thickening of the retinal tissue.⁸ Swelling of retinal neurons follows from malfunction of mitochondria caused by reactive oxygen radicals, which results in dysfunctional ion transport across the neuronal membranes and a sustained activation of ionotropic receptors due to pathological increase in extracellular glutamate. Müller cell swelling results from the downregulation of potassium channels through which the cells normally extrude potassium into the blood vessels. Because the cells are capable of taking up excess potassium from the retinal interstitium but are unable to release the ions, potassium accumulates within the cells; the increase in the intracellular osmotic pressure will cause an osmotic influx of water from the blood into the cells, resulting in cellular swelling. We found that various other factors that are known to contribute to edema formation, such as oxidative stress and inflammatory factors like prostaglandins, contribute to the induction of Müller cell swelling.^{6,9} It remains to be determined, however, whether Müller cell swelling really contributes to the development of edema. In animal models of retinal hypoxia, vascular leakage is accompanied by cellular edema of Müller cells. Some previous electron microscopic studies suggest that in addition to ischemic changes in the retinal microvasculature, swelling of Müller cells contributes to the development of cystoid macular edema, with the cysts being formed by swollen and necrotic Müller cells,¹⁰ while other studies do not describe swollen Müller cells. In the brain, swelling of astrocytes (especially of their perivascular processes) usually occurs concomitantly in vasogenic edema. Most likely, the relative contribution of vasogenic edema and dysfunction of Müller cells to the formation of retinal edema varies in dependence on the specific conditions in individual patients.

STIMULATION OF FLUID CLEARANCE BY TRIAMCINOLONE ACETONIDE?

Resolution of retinal edema can be obtained by reducing the fluid inflow from the blood and by stimulation of the fluid clearance from the retinal tissue. The antiinflammatory steroid triamcinolone acetonide reduces vascular leakage via several mechanisms, including inhibition of the production and release of VEGF, inflammatory factors, and matrix metalloproteinases. We found that triamcinolone acetonide inhibits the osmotic swelling of Müller cells.⁹ Triamcinolone acetonide stimulates the release of endogenous adenosine from the retinal tissue; adenosine activates adenosine A1 receptors, which results in the opening of potassium channels in the Müller cell membranes. The outflow of potassium ions from the cells balances the osmotic gradient across the membranes and thus prevents cellular swelling. In swollen cells, the outflow of potassium ions

is associated with an efflux of water, resulting in shrinkage of the cells. We suggest that triamcinolone acetonide stimulates the fluid absorption from the retinal tissue because opening of ion channels in Müller cell membranes improves the transport of osmolytes and, thus, of water through the cells. The observation that triamcinolone acetonide resolves macular edema also in patients who do not display angiographic vascular leakage suggests that it stimulates the fluid absorption from the retinal tissue. Selective pharmacologic activation of A1 receptors may represent a method for rapid resolution of retinal edema. A similar resolution of subretinal edema can be achieved by pharmacologic activation of purinergic receptors on retinal pigment epithelial cells.¹¹ Release of endogenous adenosine and subsequent activation of A1 receptors is an important component of the retinal response to ischemic-hypoxic stress. Adenosine protects retinal neurons from hyperexcitation and glutamate toxicity. This effect will also prevent the glutamate-evoked swelling of retinal neurons as another component of edema formation. ■

Andreas Bringmann, PhD, is the head of the Research Laboratory at the Department of Ophthalmology and Eye Hospital, Faculty of Medicine, University of Leipzig, Germany. He reports no relevant financial relationships. Dr. Bringmann can be reached via e-mail at: bria@medizin.uni-leipzig.de.



1. Gardner TW, Antonetti DA, Barber AJ, LaNoue KF, Levison SW, The Penn State Retina Research Group. Diabetic retinopathy: more than meets the eye. *Surv Ophthalmol*. 2002;47:S253–S262.
2. Marmor MF. Mechanisms of fluid accumulation in retinal edema. *Doc Ophthalmol*. 1999;97:239–249.
3. Mori F, Hikichi T, Takahashi J, Nagaoka T, Yoshida A. Dysfunction of active transport of blood-retinal barrier in patients with clinically significant macular edema in type 2 diabetes. *Diabetes Care*. 2002;25:1248–1249.
4. Pannicke T, Iandiev I, Uckermann O, Biedermann B, Kutzera F, Wiedemann P, Wolburg H, Reichenbach A, Bringmann A. A potassium channel-linked mechanism of glial cell swelling in the postischemic retina. *Mol Cell Neurosci*. 2004;26:493–502.
5. Pannicke T, Iandiev I, Wurm A, et al. Diabetes alters osmotic swelling characteristics and membrane conductance of glial cells in rat retina. *Diabetes*. 2006;55:633–639.
6. Iandiev I, Wurm A, Hollborn M, et al. Müller cell response to blue light injury of the rat retina. *Invest Ophthalmol Vis Sci*. 2008;49:3559–3567.
7. Bringmann A, Kohen L, Wolf S, Wiedemann P, Reichenbach A. Age-related decrease of potassium currents in human retinal glial (Müller) cells. *Can J Ophthalmol*. 2003;38:464–468.
8. Bringmann A, Uckermann O, Pannicke T, Iandiev I, Reichenbach A, Wiedemann P. Neuronal versus glial cell swelling in the ischaemic retina. *Acta Ophthalmol Scand*. 2005;83:528–538.
9. Uckermann O, Kutzera F, Wolf A, et al. The glucocorticoid triamcinolone acetonide inhibits osmotic swelling of retinal glial cells via stimulation of endogenous adenosine signaling. *J Pharmacol Exp Ther*. 2005;315:1036–1045.
10. Yanoff M, Fine BS, Brucker AJ, Eagle RC. Pathology of human cystoid macular edema. *Surv Ophthalmol*. 1984;28:S505–S511.
11. Maminishkis A, Jalickee S, Blaug SA, Rymer J, Yerxa BR, Peterson WM, Miller SS. The P2Y2 receptor agonist INS37217 stimulates RPE fluid transport in vitro and retinal reattachment in rat. *Invest Ophthalmol Vis Sci*. 2002;43:3555–3566.