

Optical Coherence Tomography for Diabetic Macular Edema: Early Diagnosis, Classification and Quantitative Assessment

Afef Maalej*, Wathek Cheima, Khallouli Asma, Rannen Riadh and Gabsi Salem

Military Department of Ophthalmology (Tunis), Tunisia

Introduction

Reduction in visual acuity in association with diabetic retinopathy most commonly occurs from diabetic macular edema [1].

Traditional methods of assessing DME include contact and non-contact slit-lamp biomicroscopy, indirect funduscopy, fluorescein angiography and fundus stereo-photography. However, given the relative lack of ability of these methods to detect and to quantify DME, alternative objective methods have been applied.

The introduction of OCT allows an objective evaluation of DME with effectiveness in both qualitative and quantitative description of this pathology. That is why it becomes a standard tool in the management of patients with DME [2].

More than ten years after ETDRS, OCT greatly enhanced our ability to detect macular thickening and has brought new insights on the morphology of DME and on the presence of vitreo-retinal interface abnormalities.

With the precise and useful data given by OCT, we can better diagnose, catalogue and follow DME.

Methods

In a prospective trial, OCT scans were performed for 314 eyes of 174 diabetic patients during a period of 18 months (1st January 2009 to 30 June 2010), in the Military Department of Ophthalmology of Tunis, using a time domain OCT 3 (OTI/SLO).

Inclusion criteria were: Type 1 or 2 diabetes mellitus, clinical evidence of diabetic retinopathy whatever the stage with or without clinical or angiographic evidence of a macular edema. Eyes with significant media opacities that can result in poor OCT signal were excluded (corneal opacity, cataract, intravitreal haemorrhage...). Other exclusion criteria included eyes with other pathologies that can decrease visual acuity such as glaucoma, ischemic maculopathy, optic nerve disease, retinal detachment. Other causes of macular edema were excluded (retinal venous occlusion, intra-ocular surgery, inflammation, age related macular degeneration, serous chorioretinopathy...).

The review of medical records included age, gender, duration of diabetes, stage of diabetic retinopathy. A complete ophthalmologic examination was performed: Best corrected visual acuity in log MAR, slit lamp biomicroscopy fundus examination with a contact lens (Goldmann 3 mirrors lens). All eyes underwent at least one fluorescein angiographic evaluation of the macula and of the diabetic retinopathy. A time domain OCT 3 scan was performed through a dilated pupil by the same examiner who was masked to any clinical, angiographic or functional status of the patient. In all eyes, the macula was scanned in horizontal and vertical meridians using the standard linear cross hair pattern with a scan length of 3 mm and/or 6 mm centred through the fovea.

The foveal thickness was assessed by two methods:

- Manually, using the calliper tool, measuring the distance

between the anterior retinal profile line and the retinal pigment epithelium-choriocapillaris layer (Figure 1)

- Automated retinal thickness software algorithm: 3 types of Mapping are availables (grid, zones and contours) (Figure 2)

We considered as diabetic macular edema the eyes with a foveal thickness more than $182 \pm 23 \mu\text{m}$ and an extrafoveal thickness more than $212 \pm 20 \mu\text{m}$ (Chan 2006) [1].

Different morphological patterns of macular edema were described clinically, on fluorescein angiography and on OCT scans.

Statistics

The Chi 2 and Fisher exact test were carried out to assess the statistical difference or relation between two variables. A probability value (P value) less than 0.05 was considered as significant. Correlation coefficient (r) was calculated to assess the relation between visual acuity and retinal thickness and also to evaluate the correlation degree between data given by clinical examination, angiography and OCT.

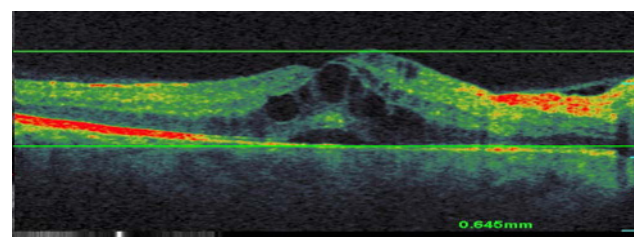


Figure 1: Manual method for macular thickness assessment.

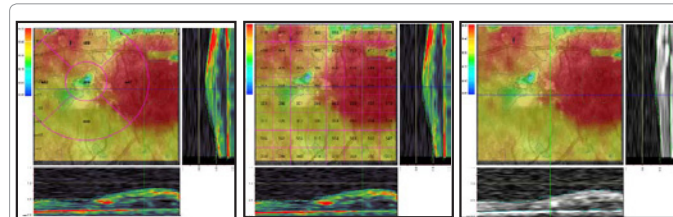


Figure 2: Automatic method for macular thickness assessment.

*Corresponding author: Afef Maalej, Military Department of Ophthalmology, Military Hospital of Tunis, Tunis 1008, Tunisia, E-mail: afefmaalej@yahoo.fr

Received December 08, 2011; Accepted February 26, 2012; Published February 29, 2012

Citation: Maalej A, Cheima W, Asma K, Riadh R, Salem G (2012) Optical Coherence Tomography for Diabetic Macular Edema: Early Diagnosis, Classification and Quantitative Assessment. J Clinic Experiment Ophthalmol S2:004. doi:10.4172/2155-9570.S2-004

Copyright: © 2012 Maalej A, et al. This is an open-access article distributed under the terms of the Creative Commons Attribution License, which permits unrestricted use, distribution, and reproduction in any medium, provided the original author and source are credited.

Results

95 men (54.6%) and 79 women (45.4%) were included in this study.

The age of patients ranged from 26 to 83 years ([mean ± standard deviation] 59 ± 6.3 years)

The mean duration of diabetes was 10 years and 3 months.

Stages of diabetic retinopathy are resumed in Figure 3.

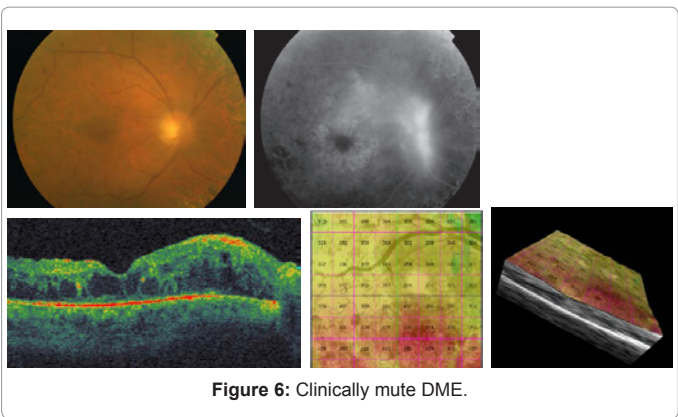
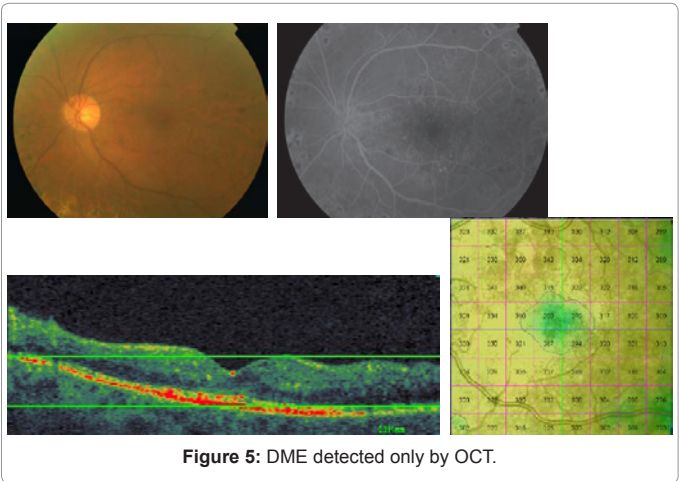
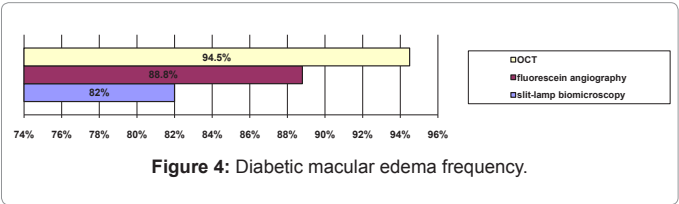
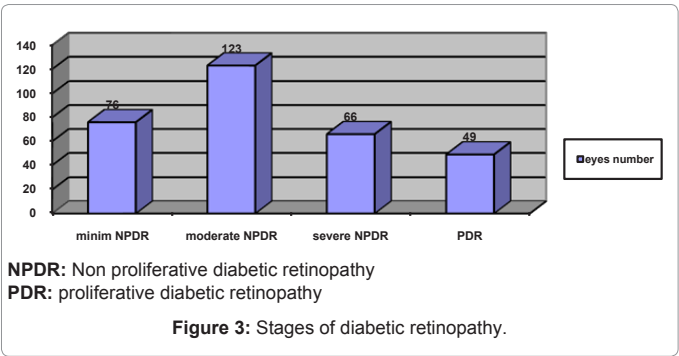
DME characteristics

The frequency of DME was depending on the diagnosis tool: with slit-lamp biomicroscopy, DME was found in 258 eyes (82.1%). An angiographic leakage was observed in 279 eyes (88.8 %). The highest frequency of DME was revealed on OCT 297 eyes (94.5 %) (Figure 4). It means that OCT showed 18 cases of DME without angiographic signs (Figure 5) and 39 cases clinically mutes (Figure 6).

The distribution of biomicroscopic and angiographic types of DME is shown in Tables 1 and 2.

OCT data

Central retinal thickness assessed manually was 502 ± 201 μm



Biomicroscopic Characteristics		Cases Number	Percentage (%)
Normal Macula		56	17.8
Doubtful thickening		49	15.6
Focal thickening +/- exsudation		87	27.7
Diffuse thickening	without cysts	51	16.3
	With cysts	71	22.6
Total		314	100

Table 1: Biomicroscopic features of DME.

Angiographic Characteristics		Cases Number	Percentage (%)
No leakage		35	11.1
Focal or multifocal DME		82	26.2
Diffuse DME	Without cysts	61	19.4
	cystoid	CC+ 58	18.5
		CC - 78	24.8
Total		314	100

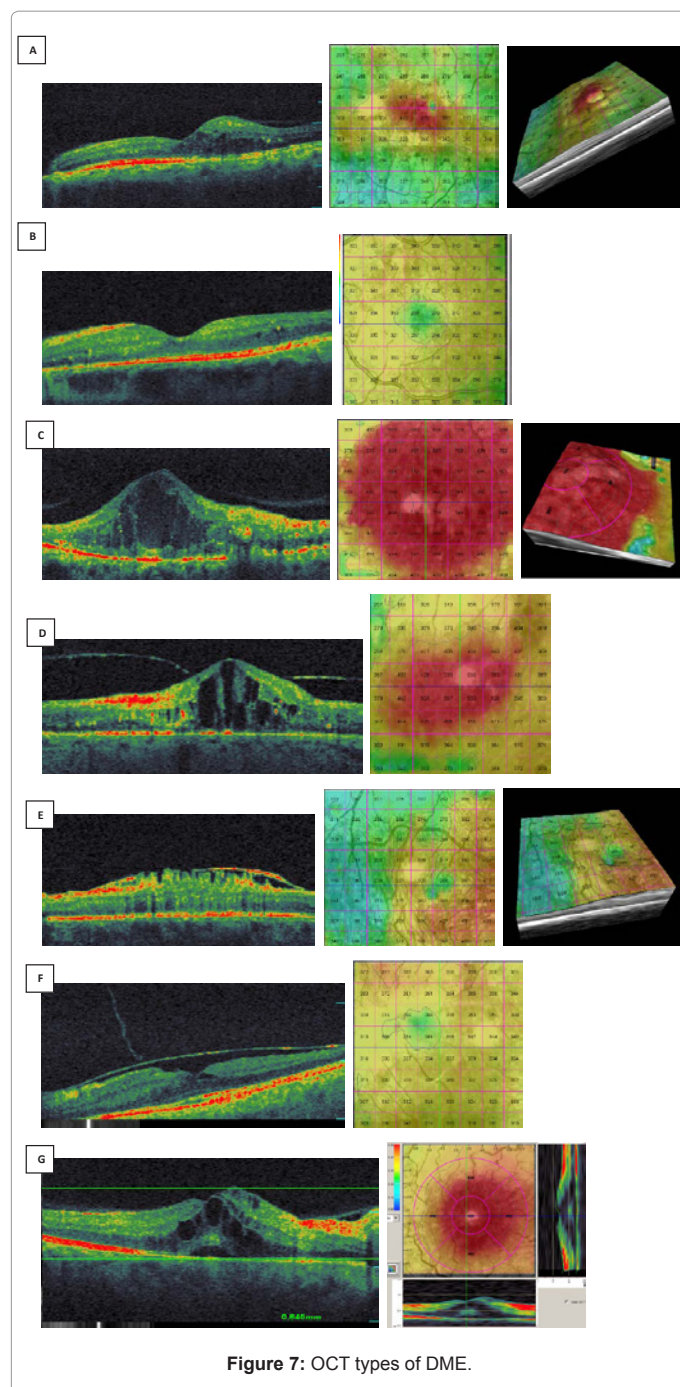
CC: central cyst

Table 2: Angiographic types of DME.

(range 181 to 1179 μm). It was 510 ± 211 μm (range 187 to 1184) on the mapping.

The detection of clinical thickening of the macula has been possible unless the foveal thickness is more than 1.33 times the normal retinal thickness values.

- OCT sensitivity to detect DME is very high (98.6 %)
- Evaluation of the OCT scans demonstrated five distinct patterns of DME (Figure 7)
- Type 1: focal macular thickening (30.3 %) (Figure 7A)
- Type 2: Diffuse thickening without cysts (20.9 %) (Figure 7B)
- Type 3: diffuse cystoid macular edema (35.7 %) (Figure 7C)
- Type 4: Tractional macular edema
- 4A: posterior hyaloid traction (7.1 %) (Figure 7D)
- 4B: epiretinal membrane (6 %) (Figure 7E)
- 4C: both posterior hyaloid and epiretinal membrane (3.2 %) (Figure 7F)
- Type 5: DME from one of the previous types associated to a macular serous retinal detachment (8.6 %). (Figure 7G)
- This serous retinal detachment was sub-clinic (detected only by OCT) in 23 eyes (85 %) (Figure 8).



Concerning the correlation between biomicroscopic evaluation and foveal thickness, there wasn't any significant relationship. (Fisher test: $p=0.3$). The correlation coefficient between this two variables was $r=0.32$ (Table 3).

The relationship between angiographic DME in his different features and a macular thickening on OCT was significant (Fisher test $p=0.0002$). The correlation coefficient is good: $r=0.62$ (Table 4).

Foveal thickness varied within the subgroups of DME. Types 3 and 4 were associated to the highest macular thickness.

Mean visual acuity (in log MAR units) was 0.51 ± 0.288 .

In assessing the relationship between visual acuity and macular thickness, a significant negative correlation was noted (Fisher test $p<0.0001$) $r=-0.87$ (Table 5).

Similar to macular thickness, mean visual acuity varied within the subgroups (Table 6).

Investigating the interaction between variables, that were found to be significant associated either with increased macular thickness and worse visual acuity, we concluded that the cystoids macular edema, mainly if there is a central cyst and the presence of tractional forces are associated to a worse anatomic and functional prognosis. The serous retinal detachment was found as a cause of decrease of the visual acuity.

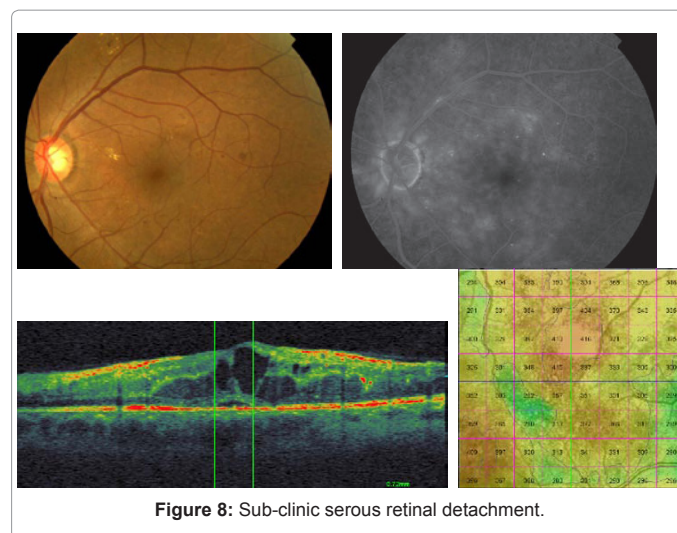
Discussion

Macular edema remains the most common reason for intervention by ophthalmologists in patients with diabetes confronting visual loss [2,3]. Mesuring macular edema is therefore of major importance in imaging patients with DME [4].

Until few years, assessment of macular thickness was subjective, relying on slit-lamp stereoscopic biomicroscopy of the fundus. Currently, with OCT, assessment becomes objective and more reliable [5]. But, witch method is better for assessing macular edema on OCT: automatic or manual? In deed, both measurements are reproducible but most studies showed that the macular thickness assessed on cartography was superior to the manual thickness [6-10]. This fact was confirmed in our study. The mapping can provide thickness in any point of the macular area. We can see variations in the thickness in colours and in three dimensions cartography. Therefore the physiologic aspect of DME can be assessed by fluorescein angiography, that is a kind of qualitative and functional evaluation, the anatomical features of DME such as extent of thickening, the retinal layers involved and associated aspects (serous retinal detachment, traction...) can be described and imaged with OCT offering a structural and quantitative analysis of DME [11].

OCT is more sensitive to small changes in retinal thickness than slit-lamp biomicroscopy [12,13]. We noted that clinic edema was suspected if the tomographic thickness exceeds 1.33 times the normal value.

Considering the emergence of new therapeutic modalities, such



Thickness (μm) \ DME Type	Normal Macula	Doubtful thickening	Focal edema +/-exsudation	Diffuse thickening		Total
				With cysts	Without cysts	
≤232	15	2	0	0	0	17
232-500	39	42	67	24	10	182
500-1000	2	5	19	40	36	102
>1000	0	0	1	7	5	13
Total	56	49	87	71	51	314

Table 3: Correlation between macular thickness and biomicroscopic types of DME.

Thickness (μm) \ DME type	No leakage	Focal or multifocal DME	Diffuse DME			Total
			No cysts	cystoid CC+	CC-	
<232	14	2	1	0	0	17
232-500	21	56	48	28	32	185
500-1000	0	24	10	23	42	99
≥1000	0	0	2	7	4	13
Total	35	82	61	58	78	314

Table 4: Correlation between macular thickness and angiographic types of DME.

as intravitreal corticosteroids and anti-VEGF injections or vitrectomy for DME, it seems worthwhile to propose a detailed and precise tomographic classification of DME [7,14].

Three OCT patterns of DME were reported by Otani and associates in 1999 [15]: sponge like swelling (88%), retinal edema with cystic spaces (47%), and retinal edema with subfoveal fluid accumulation (15%).

In 2004, Kang proposed a classification in 4 types [11]: type 1 thickening with homogenous optical reflectivity (55.2%), type 2 thickening with markedly decreased optical reflectivity in the outer retinal layers (30.3%), type 3A foveolar detachment without traction (14.5%) and type 3B foveolar detachment with apparent vitreofoveal traction (2.8%). In this classification authors considered the tractional factor and subdivided the foveal detachment according to the presence of tractional membrane. These observations have important therapeutic impacts.

Another OCT based classification was published in 2006 by Kim and associates [5]: diffuse retinal thickening (97%), cystoids macular edema ((55%), serous retinal detachment (2.9%). This classification considered the traction retinal detachment and the serous retinal detachment.

In all these descriptions, the focal macular edema was omitted. The individualization of this type of DME is very important because of its therapeutic consequences. In fact , the focal laser photocoagulation is better guided by the OCT mapping showing the area of macular thickening and offering a precise localization of the edema by the overly image [16].

That's why we proposed an OCT classification of DME in five types: type 1 focal macular thickening, type 2 diffuse macular edema without cysts, type 3 cystoid macular edema, type 4 tractional macular edema, type 5 serous retinal detachments. This classification seems to be exhaustive exposing the whole aspects of DME. It is useful to disclose the pathogenic phenomena of DME, complementarily to angiographic data. Tractional forces on the fovea can be caused not only by the posterior hyaloid but also by an epiretinal membrane or sometimes by the two structures at the time [17,18].

Each of the morphologic subtypes of DME represents distinct entity that requires specific treatment regimens to achieve the best final result. The OCT type 4 with tractional component should be the best candidate for vitrectomy.

As in previous studies, we also found a significant relationship between retinal thickness and visual acuity [19-21]. The correlation coefficient varied within series (Table 7).

We also found a correlation between some morphologic patterns of DME and worse visual acuity. Focal macular edema less than central 500 μm from the fovea, cystoid macular edema, posterior hyaloid traction and serous retinal detachment were associated to a low visual acuity. However, Otani showed that cystoid macular edema hasn't any influence on the visual acuity [15].

Serous retinal detachment seems to be without effect on the visual acuity in diabetic eyes [17,29] , but in our study, it was correlated to an increased macular thickness and therefore to a worse visual acuity.

Comparing OCT and slit-lamp biomicroscopy, it's obvious that OCT can detect macular thickening while the clinic examination still normal [29].

Lattanzio and associates evaluated the macular thickness of eyes with clinically undetected DME to $228 \pm 53 \mu\text{m}$ [30].

Shaïdi noted that the slit-lamp biomicroscopy can detect DME unless the macular thickness exceeded 1.5 times the normal value [31] (in our study: 1.33 times).

For Browning, clinical diagnosis of DME was sub-estimated in 58 to 90% of cases [12].

The term of sub-clinic DME was described by Brown who reported that for eyes with a macular thickness between 201 and 301 μm, a DME can be seen on slit-lamp biomicroscopy in only 14 % [32].

Assessing the degree of correlation between fluorescein angiographic and tomographic features of DME, Kang concluded to a significant relationship for clinically significant macular edema [11].

A middle relation between macular thickness as assessed by OCT and leakage score as evaluated on fluorescein angiography was reported by Goebel ($p < 0.0001$ and $r = 0.44$) [8]. In our cohort the correlation coefficient between retinal thickness and angiographic types of DME was $r = 0.62$.

Thus, slit-lamp biomicroscopy, fluorescein angiography and OCT seem to be complementary in the diagnosis of DME, but OCT still more objective and less invasive for the following of this clinical entity [33].

Thick.(μm)	≤232	232-500	500-1000	>1000	Total
VA (log MAR)					
>1	0	11	11	13	35
[0.3-1]	0	78	89	0	167
[0-0.3]	17	93	2	0	112
Total	17	182	102	13	314

Thick : thickness

VA : visual acuity

Table 5: Correlation between visual acuity and retinal thickness.

DME type	Type1	Type2	Type3	Type4	Type 5	Total
VA (log MAR)						
> 1	3	5	10	17	9	44
[1-0.3]	29	37	85	16	5	172
[0.3-0]	58	20	11	6	3	98
Total	90	62	106	39	17	314

Table 6: Correlation between visual acuity and OCT types of DME.

Authors	Eyes number	year	Coefficient
Hee MR [22]	75	1995	0.67
Hee MR [23]	25	1998	0.89
Otani [15]	59	1999	0.64
Otani [24]	13	2001	0.76
Sanchez [25]	148	2002	0.9
Goebel [8]	136	2002	0.39
Massin [26]	15	2003	0.32
Laursen [27]	23	2004	0.29
Bandello [28]	28	2005	0.68
Kim [5]	164	2006	0.40
Diabetic retinopathy clinical research network [19]	251	2007	0.52
Our study	314	2011	0.87

Table 7: The correlation coefficient between retinal thickness and visual acuity.

Conclusion

Optical coherence tomography (OCT) has gained increasing popularity as an objective tool to measure retinal thickness and other aspects associated with macular edema. An advantage of using OCT is its quantitative assessment, rather than the qualitative evaluation performed with biomicroscopy or fluorescein angiography. The importance of OCT in routine clinical assessment of macular edema will most probably continue to grow. The amount of information's given by OCT demonstrates that macular edema is a complex clinical entity with various morphology and gravity, and disclaimed the limitations of a simple "clinic" definition.

Identifying the structural changes in eyes with DME using OCT may allow more effective management of these patients.

A uniform and precise classification of DME would increase the possibility to optimize our indications, to compare and to judge the results of different therapeutic strategies.

References

- Chan A, Duker JS, Ko TH, Fujimoto JG, Schuman JS (2006) Normal macular thickness measurements in healthy eyes using stratus optical coherence tomography. Arch Ophthalmol 124: 193-198.
- Massin P, Girach A, Erginay A, Gaudric A (2006) Optical coherence tomography: a key to the future management of patients with diabetic macular oedema. Acta Ophthalmol Scand 84: 466-474.
- Buabbud JC, Al-latayfeh MM, Sun JK (2010) Optical coherence tomography imaging for diabetic retinopathy and macular edema. Curr Diab Rep 10: 264-269.
- Browning DJ (2010) Interpreting Thickness Changes in the Diabetic Macula: The Problem of Short-Term Variation in Optical Coherence Tomography-Measured Macular Thickening. Trans Am Ophthalmol Soc 108: 62-76.
- Kim BY, Smith SD, Kaiser PK (2006) Optical coherence tomographic patterns of diabetic macular edema. Am J Ophthalmol 142: 405-412.
- Diabetic Retinopathy Clinical Research Network, Browning DJ, Glassman AR, Aiello LP, Beck RW, et al. (2007) Relationship between optical coherence tomography-measured central retinal thickness and visual acuity in diabetic macular edema. Ophthalmology 114: 525-536.
- Funatsu H, Yamashita H, Shimizu E, Mimura T, Nakamura S, et al. (2004) Quantitative measurement of retinal thickness in patients with diabetic macular edema is useful for evaluation of therapeutic agents. Diabetes Res Clin Pract 66: 219-227.
- Goebel W, Kretschmar-Gross T (2002) Retinal thickness in diabetic retinopathy: A study using optical coherence tomography. Retina 22: 759-767.
- Massin P, Vicaute E, Haouchine B, Erginay A, Paques M, et al. (2001) Reproducibility of retinal mapping using Optical Coherence Tomography. Arch Ophthalmol 119: 1135-1142.
- Polito A, Del Borrello M, Isola M, Zemella N, Bandello F (2005) Repeatability and reproducibility of fast macular thickness mapping with stratus optical coherence tomography. Arch Ophthalmol 123: 1330-1337.
- Kang SW, Park CY, Ham DI (2004) The correlation between fluorescein angiographic and optical coherence tomographic features in clinically significant diabetic macular edema. Am J Ophthalmol 137: 313-322.
- Browning DJ, McOwen MD, Bowen RM Jr, O'Marah TL (2004) Comparison of the clinical diagnosis of diabetic macular edema with diagnosis by optical coherence tomography. Ophthalmology 111: 712-715.
- Davis MD, Bressler SB, Aiello LP, Bressler NM, Browning DJ, et al. (2008) Browning and associates. Comparison of Time-Domain OCT and Fundus Photographic Assessments of Retinal Thickening in Eyes with Diabetic Macular Edema. Invest Ophthalmol Vis Sci 49: 1745-1752.
- Massin P, Girach A, Erginay A, Gaudric A (2006) Optical coherence tomography: a key to the future management of patient with diabetic macular edema. Acta Ophthalmol Scand 184: 466-474.
- Otani T, Kishi S, Maruyama Y (1999) Patterns of diabetic macular edema with optical coherence tomography. Am J Ophthalmol 127: 688-693.
- Browning DJ, Altaweel MM, Bressler NM, Bressler SB, Scott IU, et al. (2008) Diabetic macular edema: what is focal and what is diffuse? Am J Ophthalmol 146: 649-655, 655.e1-6.
- Thomas D, Bunce C, Moorman C, Laidlaw AH (2005) Frequency and associations of a taut thickened posterior hyaloid, partial vitreomacular separation, and subretinal fluid in patients with diabetic macular edema. Retina 25: 883-888.
- Gaucher D, Tadayoni R, Erginay A, Haouchine B, Gaudric A, et al. (2005) Optical coherence tomography assessment of the vitreoretinal relationship in diabetic macular edema. Am J Ophthalmol 139: 807-813.
- Diabetic Retinopathy Clinical Research Network, Browning DJ, Glassman AR, Aiello LP, Beck RW, et al. (2007) Relationship between Optical Coherence Tomography-Measured Central Retinal Thickness and Visual Acuity in Diabetic Macular Edema. Ophthalmology 14: 525-536.
- Wu B, Deng J, Yao C, He S, Gao R, et al. (2010) Macular morphology and function in patients with diabetic retinopathy without apparent visual loss. Yan Ke Xue Bao 25: 41-43.
- Schaudig U, Scholz F, Lerche RC, Richard G (2004) Optical coherence tomography for macular edema. Classification, quantitative assessment, and rational usage in the clinical practice. Ophthalmologie 101: 785-93.
- Hee MR, Puliafito CA, Wong C, Duker JS, Reichel E, et al. (1995) Quantitative assessment of macular edema with optical coherence tomography. Arch Ophthalmol 113: 1019-1029.
- Hee MR, Puliafito CA, Duker JS, Reichel E, Coker JG, et al. (1998) Topography of diabetic macular edema with optical coherence tomography. Ophthalmology 105: 360-370.
- Otani T, Kishi S (2001) Tomographic findings of foveal hard exudates in diabetic macular edema. Am J Ophthalmol 131: 50-54.

25. Sanchez-Tocino H, Alvarez-Vidal A, Maldonado MJ, Moreno-Montañés J, García-Layana A (2002) Retinal thickness study with optical coherence tomography in patients with diabetes. *Invest Ophthalmol Vis Sci* 43: 1588-1594.
26. Massin P, Duguid G, Erginay A, Haouchine B, Gaudric A (2003) Optical coherence tomography for evaluating diabetic macular edema before and after vitrectomie. *Am J Ophthalmol* 105: 169-177.
27. Laursen ML, Moeller F, Sander B, Sjoelie AK (2004) Subthreshold micropulse diode laser treatment in diabetic macular edema. *Br J Ophthalmol* 88: 1173-1179.
28. Bandello F, Polito A, Del Borrello M, Zemella N, Isola M (2005) "Light" versus "classic" laser treatment for clinically significant diabetic macular oedema. *Br J Ophthalmol* 89: 864-870.
29. Koleva-Georgieva DN, Sivkova NP (2010) Optical coherence tomography for the detection of early macular edema in diabetic patients with retinopathy. *Folia Med (Plovdiv)* 52: 40-48.
30. Lattanzio R, Brancato R, Pierro L, Bandello F, Iaccher B, et al. (2002) Macular thickness measured by optical coherence tomography (OCT) in diabetic patients. *Eur J Ophthalmol* 12: 482-487.
31. Shaidi M, Ogura Y, Blair NP, Rusin MM, Zeimer R (1991) Retinal thickness analysis for quantitative assessment of diabetic macular edema. *Arch Ophthalmol* 109: 1115-1119.
32. Brown JC, Solomon SD, Bressler SB, Schachat AP, DiBernardo C, et al. (2004) Detection of diabetic foveal edema: Contact lens biomicroscopy compared with optical coherence tomography. *Arch Ophthalmol* 122: 330-335.
33. Baskin DE (2010) Optical coherence tomography in diabetic macular edema. *Curr Opin Ophthalmol* 21: 172-177.

This article was originally published in a special issue, **Ocular Diseases: Immunological and Molecular Mechanisms** handled by Editor(s). Dr. C S De Paiva, Cullen Eye Institute, Baylor College of Medicine, USA

Submit your next manuscript and get advantages of OMICS Group submissions

Unique features:

- User friendly/feasible website-translation of your paper to 50 world's leading languages
- Audio Version of published paper
- Digital articles to share and explore

Special features:

- 200 Open Access Journals
- 15,000 editorial team
- 21 days rapid review process
- Quality and quick editorial, review and publication processing
- Indexing at PubMed (partial), Scopus, DOAJ, EBSCO, Index Copernicus and Google Scholar etc
- Sharing Option: Social Networking Enabled
- Authors, Reviewers and Editors rewarded with online Scientific Credits
- Better discount for your subsequent articles

Submit your manuscript at: www.editorialmanager.com/clinicalgroup