



## Optical coherence tomography in the evaluation of structural changes in primary open-angle glaucoma with and without elevated intraocular pressure

Optička koherentna tomografija u proceni strukturnih promena kod primarnog glaukoma otvorenog ugla sa i bez povišenog intraokularnog pritiska

Marija Trenkić Božinović\*, Gordana Zlatanović\*†, Predrag Jovanović\*†, Dragan Veselinović\*†, Jasmina Djordjević Jocić\*†, Marija Radenković\*, Mirko Resan\*§

\*Ophthalmology Clinic, University Medical Center Niš, Niš, Serbia; †Faculty of Medicine, University of Niš, Niš, Serbia; ‡Ophthalmology Clinic, Military Medical Academy, Belgrade, Serbia; §Faculty of Medicine of the Military Medical Academy, University of Defence, Belgrade, Serbia

### Abstract

**Background/Aim.** Glaucoma is a progressive optic neuropathy characterized by damage of the retinal ganglion cells and their axons and glial cells. The aim of this study was to evaluate the differences and connections between changes in the visual field and the thickness of the peripapillary retinal nerve fiber layer (RNFL), using optical coherence tomography (OCT) in patients with primary open-angle glaucoma with normal and elevated intraocular pressure (IOP). **Methods.** This prospective study included 38 patients (38 eyes) with primary open-angle glaucoma with normal intraocular pressure (NTG) and 50 patients (50 eyes) with primary open-angle glaucoma with elevated intraocular pressure (HTG), paired by the same degree of structural glaucomatous changes in the optic nerve head and by age. OCT protocols 'fast RNFL thickness' and 'fast optic disc' were used for testing. The patients' age, gender, best corrected visual acuity (BCVA), IOP, stereometric and functional parameters were compared. **Results.** The average age of the examined population was  $65.49 \pm 9.36$  (range 44–83) years. There was no statistically significant difference by age and

by gender between the two study groups ( $p = 0.795$  and  $p = 0.807$ , respectively). BCVA was higher in patients with NTG but there was no statistically significant difference compared to HTG patients ( $p = 0.160$ ). IOP was statistically significantly higher in patients with HTG compared to NTG patients ( $17.40 \pm 2.77$  mmHg *vs*  $14.95 \pm 3.01$  mmHg,  $p = 0.009$ ). The cup/disc (C/D) ( $p = 0.258$ ), mean deviation (MD) ( $p = 0.477$ ), corrected pattern standard deviation (CPSD) ( $p = 0.943$ ), disk area ( $p = 0.515$ ), rim area ( $p = 0.294$ ), rim volume ( $p = 0.118$ ), C/D area R ( $p = 0.103$ ), RNFL Average ( $p = 0.632$ ), RNFL Superior ( $p = 0.283$ ) and RNFL Inferior ( $p = 0.488$ ) were not statistically significantly different between the groups. **Conclusion.** OCT measurements of the RNFL thickness provide clinically significant information in monitoring of glaucomatous changes. There are no differences in the patterns of RNFL defects *per* sectors and quadrants between NTG and HTG, measured by OCT.

**Key words:** glaucoma, open-angle; intraocular pressure; tomography, optical coherence.

### Apstrakt

**Uvod/Cilj.** Glaukom je progresivna optička neuropatija koja oštećuje retinalne ganglijske ćelije i njihove aksone i glijalne ćelije. Cilj rada bio je da se procene razlike i veze između promena u vidnom polju i debljine peripapilarnih nervnih vlakana retine (RNFL), uz pomoć optičke koherentne tomografije (OCT), kod bolesnika obolelih od primarnog glaukoma otvorenog ugla sa normalnim i povišenim intraokularnim pritiskom (IOP). **Metode.** U ovu prospektivnu studiju bilo je

uključeno 38 bolesnika (38 očiju) obolelih od primarnog glaukoma otvorenog ugla sa normalnim intraokularnim pritiskom (NTG) i 50 bolesnika (50 očiju) obolelih od primarnog glaukoma otvorenog ugla sa povišenim intraokularnim pritiskom (HTG). Bolesnici su bili upareni po stepenu glaukomnih strukturnih promena glave vidnog živca i godinama starosti. Za ispitivanje su korišćeni 'fast RNFL thickness' i 'fast optic disc' OCT protokoli. Upoređivani su starost bolesnika, pol, najbolje korigovana vidna oštrina (BCVA), IOP, stereometrijski i funkcionalni parametri. **Rezultati.** Prosečna starost ispitanika

bila je  $65,49 \pm 9,36$  (opseg 44–83) godine. Utvrđeno je da ne postoji statistički značajna razlika prema starosti i prema polu između dve ispitivane grupe ( $p = 0,795$ , odnosno  $p = 0,807$ ). BCVA je bila veća kod bolesnika sa NTG, ali nije bilo statistički značajne razlike u odnosu na HTG bolesnike ( $p = 0,160$ ). IOP je bio statistički značajno viši kod bolesnika sa HTG u odnosu na NTG bolesnike ( $17,40 \pm 2,77$  mmHg *vs*  $14,95 \pm 3,01$  mmHg,  $p = 0,009$ ). Vrednosti *cup/disc* (C/D) ( $p = 0,258$ ), *mean deviation* (MD) ( $p = 0,477$ ), *corrected pattern standard deviation* (CPSD) ( $p = 0,943$ ), *disk area* ( $p = 0,515$ ), *rim area* ( $p = 0,294$ ), *rim volume* ( $p = 0,118$ ), *C/D area R* ( $p = 0,103$ ), *RNFL Average*

( $p = 0,632$ ), *RNFL Superior* ( $p = 0,283$ ) i *RNFL Inferior* ( $p = 0,488$ ) nisu se statistički značajno razlikovale između ispitivanih grupa. **Zaključak.** OCT parametri debljine RNFL obezbeđuju klinički važne informacije u praćenju glaukomnih promena. Ne postoje razlike u defektu RNFL po sektorima i kvadrantima između NTG i HTG bolesnika merenih OCT procedurom.

**Ključne reči:**  
glaukom, otvorenog ugla; intraokularni pritisak; tomografija, optička, koherentna.

## Introduction

Glaucoma is a progressive optic neuropathy characterized by damage of the retinal ganglion cells and their axons and glial cells<sup>1-3</sup>. This leads to morphological changes of the optic nerve head (ONH) and the accompanying changes in the visual field<sup>4</sup>. Primary open-angle glaucoma (POAG) is the most common glaucoma type. Although, elevated intraocular pressure (IOP) is considered as one of the main causes of the occurrence of glaucoma, POAG in elderly patients may occur with elevated intraocular pressure (HTG), normal intraocular pressure (NTG) as well as ocular hypertension (OH)<sup>5,6</sup>. Despite the numerous technical possibilities for testing the morphological and functional changes in glaucoma, POAG with and POAG without elevated IOP is a field in which many scientific results and opinions are opposite. Numerous studies, both past and present, have shown that the structural and functional changes in patients with HTG and NTG are almost identical<sup>7-11</sup>, as well as being completely different<sup>12-22</sup>.

Optical coherence tomography (OCT) is a contactless, non-invasive diagnostic procedure, that can be repeated number of times<sup>23-27</sup>. OCT provides measurements of the thickness of the retinal nerve fiber layer, the loss of 25% of which, occurs in the early stages of glaucoma<sup>4,28</sup>. Some authors have shown that the loss of as much as 40% to 50% of the nerve fibers of the optic nerve does not have to be accompanied by changes in the visual field<sup>28</sup>. Because of this change, RNFL thickness is considered as the most sensitive indicator for glaucomatous damage<sup>29</sup>.

Yamazaki et al.<sup>30</sup>, and Woo et al.<sup>31</sup> demonstrated the different patterns of retinal nerve fiber layer (RNFL) defects in patients with HTG compared to patients with NTG, i.e. in NTG the defects are more localized. However, Kubota et al.<sup>32</sup>, and Kook et al.<sup>33</sup> reported that there was a symmetrical loss of RNFL in the superior and inferior quadrants in POAG patients with elevated IOP. In contrast to all this, Mok et al.<sup>1,34</sup> reported that there are no differences in RNFL thinning pattern in HTG and NTG; it was a mixture of localized and diffuse RNFL defects in both cases<sup>29</sup>.

The aim of this study was to evaluate the differences and connections between changes in the visual field and the thickness of the peripapillary retinal nerve fiber layer, measured by OCT in POAG patients with normal and elevated IOP.

## Methods

This prospective study included 38 eyes (38 patients) suffering from POAG with normal IOP (NTG) and 50 eyes (50 patients) suffering from POAG with elevated IOP (HTG), paired by the degree of structural glaucomatous changes of the optic nerve head and by age. The selection and monitoring of the patients was performed at the Department of Ophthalmology, University Medical Center Niš. The research followed the Declaration of Helsinki and was approved by the Ethical Review Board of Clinical Center Niš.

All of the patients had the previous diagnosis of POAG with elevated or normal IOP. Exclusion criteria were: spherical equivalent  $> \pm 4$  Dsph, other ocular diseases, ocular surgery performed in the previous year, laser treatment, trauma, secondary glaucoma, neurological diseases with changes in the visual field, patients with unreliable visual field (defined as false-negative errors  $> 33\%$ , false-positive errors  $> 33\%$ , and fixation losses  $> 20\%$ ), patients with anomalies of the optic nerve head. If both eyes of the patients satisfied the inclusion criteria, only one eye was randomly selected.

The following demographic and stereometric parameters were measured and studied here: the patients' age (years); gender; best corrected visual acuity (BCVA) determined by Snellen; intraocular pressure (in mmHg) measured by applanation tonometry; the size of the optic nerve head excavation (*cup/disc* - C/D) determined by indirect ophthalmoscopy with 90 D lens; the value of mean deviation (MD, in dB) and corrected pattern standard deviation (CPSD, in dB) obtained by computed (static) perimetry; disc area (in mm<sup>2</sup>), rim area (in mm<sup>2</sup>), rim volume (in mm<sup>3</sup>), C/D area ratio, the global average thickness of peripapillary retinal nerve fibers (RNFL Avg, in  $\mu$ m) and average RNFL thickness (in  $\mu$ m) in four quadrants and all sectors measured by OCT.

Static perimetry, Humphrey visual field analyzer (Carl Zeiss Meditec, Inc., threshold test 24-2), was used to reveal the defects in the visual field of patients. The first visual field was never considered with regard to the learning curve.

OCT measurements were performed on the Stratus OCT (Carl Zeiss Meditec, Inc.). For testing, 'fast RNFL thickness' and 'fast optic disc' OCT protocols were used. Fast RNFL protocol consists of three circular scans, each 3.46 mm in diameter, centered on the optic disc. This diameter has been shown to be optimal for RNFL thickness analysis

and provides better reproducibility than single scan. Scans were further analyzed using the RNFL thickness average analysis protocol (OU). The protocol quantifies the average RNFL thickness (360° measure), as well as 12 clock-hour sectoral measures (30°): 1 clock-hour: supero-nasal (15 to 45°), 2: nasal-superior (45 to 75°), 3: nasal (75–105°), 4: nasal-inferior (105–135°), 5: inferonasal (135–165°), 6: inferior (165–195°), 7: inferotemporal (195–225°), 8: tempo-inferior (225–255°), 9: temporal (255–285°), 10: tempo-superior (285–315°), 11: superotemporal (315–345°), 12: superior (345–15°). Three adjacent measures are then averaged (clock hours 11, 12, 1; 2, 3, 4; 5, 6, 7; 8, 9, 10) to provide four quadrant thickness values. One author performed all the images and measurements.

The data are shown as arithmetic means and standard deviations. The comparison of the values between patients with NTG and HTG was carried out using *t*-test or Mann-Whitney test. The association of these parameters was tested by Spearman's correlation coefficient. Statistical analysis of data was performed by SPSS (version 16.0, SPSS Science, Chicago, IL, USA). *p*-value < 0.05 was considered statistically significant.

## Results

The study included 38 (43.18%) NTG patients and 50 (56.82%) HTG patients. The average age of the examined population was 65.49 ± 9.36 (range 44–83) years. No statistically significant difference by age and by gender was found between

the two study groups (*p* = 0.795 and *p* = 0.807, respectively) (Table 1).

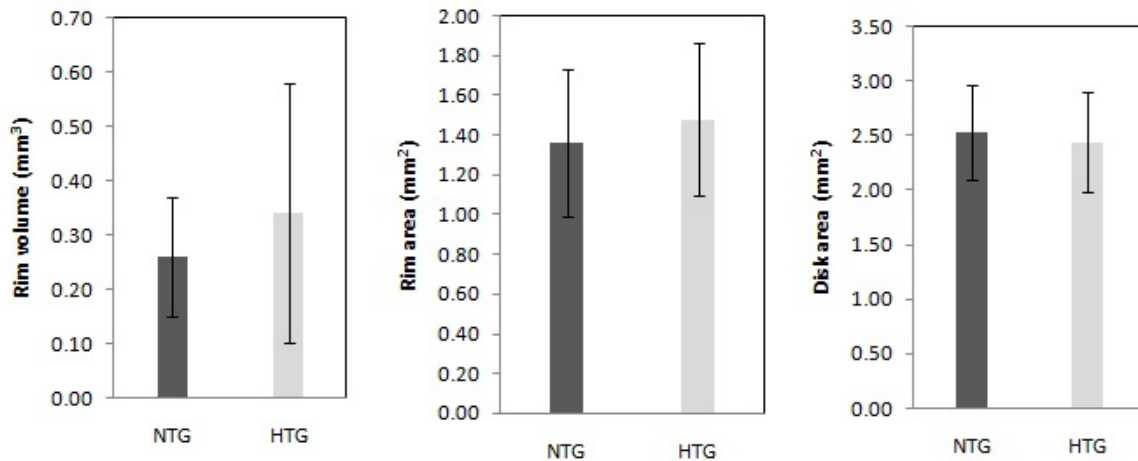
In the group of NTG patients, the therapy of 32 (84.21%) patients included one anti-glaucomatous topical medication (81.25%  $\alpha$ -agonist, 18.75% carbonic anhydrase inhibitor), four patients (10.53%) received two medications, and two patients (5.26%) received three medications. In the second group, HTG patients were on the following therapy: 12 (24.00%) patients received one medication, 16 (32.%) patients two medications, and 22 (44%) patients three medications.

Best corrected visual acuity was higher in patients with NTG but there was no statistically significant difference compared to HTG patients (*p* = 0.160). Intraocular pressure with the prescribed therapy was significantly higher in patients with HTG compared to NTG patients (17.40 ± 2.77 mmHg vs 14.95 ± 3.01 mmHg, *p* = 0.009). The morphological parameters of the optic nerve head, due to the examination of the fundus with the 90D lens, C/D, were not statistically significantly different between the patients with HTG and NTG (*p* = 0.258). Changes in the visual field, ie. functional parameters: MD (*p* = 0.477) and CPSD (*p* = 0.943) did not show any statistical significance. Stereometric ONH parameters obtained by OCT: disk area (*p* = 0.515), rim area (*p* = 0.294), rim volume (*p* = 0.118), C/D area R (*p* = 0.103), RNFL Avg (*p* = 0.632), RNFL Superior (RNFL Sup) (*p* = 0.283) and RNFL Inferior (RNFL Inf) (*p* = 0.488) were not statistically significantly different between the groups (Table 1, Figure 1).

**Table 1**  
Demographic and stereometric parameters of primary open-angle glaucoma (POAG) the patients with normal intraocular pressure (NTG) and elevated intraocular pressure (HTG)

Parameters`	NTG (n = 38) $\bar{x} \pm SD$	HTG (n = 50) $\bar{x} \pm SD$	t/z*	<i>p</i>
Age (years)	65.90 ± 9.22	65.16 ± 9.65	0.262	0.795
Gender (M/F), n	15/23	16/34	0.059	0.807
BCVA	0.89 ± 0.23	0.81 ± 0.26	1.406*	0.160
IOP (mmHg)	14.95 ± 3.01	17.40 ± 2.77	2.772	0.009
C/D	0.51 ± 0.13	0.46 ± 0.16	1.146	0.258
MD (dB)	-5.35 ± 3.31	-6.16 ± 2.90	0.711*	0.477
CPSD (dB)	4.10 ± 3.45	3.86 ± 2.90	0.071*	0.943
Disk area (mm <sup>2</sup> )	2.53 ± 0.44	2.44 ± 0.46	0.658	0.515
Rim area (mm <sup>2</sup> )	1.36 ± 0.37	1.48 ± 0.38	1.063	0.294
Rim volume (mm <sup>3</sup> )	0.26 ± 0.11	0.34 ± 0.24	1.603	0.118
C/D area R	0.46 ± 0.14	0.37 ± 0.19	1.665	0.103
RNFL Avg (μm)	92.74 ± 17.91	95.37 ± 17.87	0.483	0.632
RNFL Sup (μm)	105.11 ± 30.27	114.72 ± 27.22	1.090	0.283
RNFL Inf (μm)	123.84 ± 28.30	117.84 ± 27.95	0.701	0.488
RNFL Nas (μm)	80.05 ± 21.58	82.16 ± 22.06	0.457	0.648
RNFL Temp (μm)	64.20 ± 15.30	62.12 ± 10.74	0.709	0.478

M/F – male/female; BCVA – best corrected visual acuity; IOP – intraocular pressure; MD – mean deviation; CPSD – corrected pattern standard deviation; C/D area R – cup/disc area ratio; RNFL – retinal nerve fiber layer; RNFL Avg – RNFL average; RNFL Sup – RNFL superior; RNFL Inf – RNFL inferior; RNFL Nas – RNFL nasal; RNFL Temp – RNFL temporal.



**Fig. 1 – Rim volume, rim area and disc area in normal intraocular pressure (NTG) and elevated intraocular pressure (HTG) patients showing no statistically significant difference between NTG and HTG groups. (rim volume:  $p = 0.118$ ; rim area:  $p = 0.294$ ; disc area:  $p = 0.515$ ).**

The average global and quadrant, and sectoral RNFL thickness values were compared between the groups of NTG and HTG patients; no statistically significant difference in the values of the thickness of RNFL as *per* quadrant and sectors was found (Tables 1 and 2).

The correlation analysis of the structural and functional parameters in patients with NTG and HTG was performed by Spearman's correlation coefficient (Tables 3 and 4). A statistically significant positive correlation in the group of NTG patients was found between RNFL Avg and rim volume ( $p = 0.713$ ,  $p = 0.001$ ), RNFL Avg and rim area ( $p = 0.847$ ,  $p < 0.001$ ), RNFL Sup and rim area ( $p = 0.522$ ,  $p = 0.022$ ), RNFL Inf and RNFL Nasal (RNFL Nas) ( $p = 0.595$ ,  $p <$

$0.001$ ), RNFL Inf and RNFL Temporal (RNFL Temp) ( $p = 0.574$ ,  $p = 0.010$ ), RNFL Inf and rim volume ( $p = 0.462$ ,  $p = 0.047$ ), RNFL Inf and rim area ( $p = 0.674$ ,  $p = 0.002$ ), RNFL Nas and rim volume ( $p = 0.702$ ,  $p = 0.001$ ), RNFL Nas and rim area ( $p = 0.547$ ,  $p = 0.015$ ), RNFL Temp and rim area ( $p = 0.651$ ,  $p = 0.003$ ), RNFL Avg and disk area ( $p = 0.634$ ,  $p = 0.004$ ), RNFL Sup and disk area ( $p = 0.778$ ,  $p < 0.005$ ) (Table 3).

A statistically significant positive correlation in the group of HTG patients was found between RNFL Avg and rim volume ( $p = 0.627$ ,  $p = 0.001$ ), RNFL Avg and rim area ( $p = 0.467$ ,  $p = 0.019$ ), RNFL Sup and RNFL Nas ( $p = 0.420$ ,  $p = 0.036$ ), RNFL Sup and rim volume ( $p = 0.484$ ,  $p = 0.014$ ), RNFL Inf and RNFL Nas ( $p = 0.594$ ,  $p = 0.002$ ),

**Table 2**  
**The thickness of peripapillary retinal nerve fiber layer (RNFL) in normal intraocular pressure (NTG) and elevated intraocular pressure (HTG) patients on optical coherence tomography (OCT)**

Clock-hour sectoral measures	NTG (n = 38) $\bar{x} \pm SD$	HTG (n = 50) $\bar{x} \pm SD$	$p^*$ $\mu m$
1	93.70 ± 30.58	109.64 ± 32.49	0.100
2	88.75 ± 23.72	91.92 ± 26.02	0.631
3	64.40 ± 21.12	69.04 ± 18.89	0.411
4	82.05 ± 26.09	85.40 ± 28.78	0.568
5	110.80 ± 28.18	107.52 ± 35.37	0.706
6	132.65 ± 40.58	121.76 ± 34.86	0.723
7	123.55 ± 46.18	115.48 ± 24.94	0.213
8	65.65 ± 21.32	62.64 ± 11.42	0.267
9	49.00 ± 14.26	49.60 ± 9.80	0.936
10	74.85 ± 20.64	73.72 ± 15.48	0.973
11	111.20 ± 34.75	115.32 ± 24.51	0.749
12	107.55 ± 39.89	121.32 ± 37.24	0.320

\*Mann-Whitney U test

Clock-hour sectoral measures: 1 – supero-nasal (15 to 45°); 2 – nasal-superior (45 to 75°); 3 – nasal (75–105°); 4 – nasal-inferior (105–135°); 5 – inferonasal (135–165°); 6 – inferior (165–195°); 7 – inferotemporal (195–225°); 8 – tempo-inferior (225–255°); 9 – temporal (255–285°); 10 – tempo-superior (285–315°); 11 – superotemporal (315–345°); 12 – superior (345–15°).

**Table 3**  
**Correlation analysis of the structural and functional parameters in patients with normal intraocular pressure (NTG)**

Parameters	Rim volume	Rim area	Disk area	MD	CPSD
RNFL Avg	<b>0.713**</b>	<b>0.847**</b>	<b>0.634**</b>	0.450	-0.166‡
<i>p</i>	<b>0.001</b>	<b>&lt; 0.001</b>	<b>0.004</b>	0.053	0.496†
RNFL Sup	0.269	<b>0.522*</b>	<b>0.778**</b>	0.400	-0.218
<i>p</i>	0.266	<b>0.022</b>	<b>&lt; 0.001</b>	0.090	0.369
RNFL Inf	<b>0.462*</b>	<b>0.674**</b>	0.158	0.450	-0.111
<i>p</i>	<b>0.047</b>	<b>0.002</b>	0.519	0.053	0.651
RNFL Nas	<b>0.702**</b>	<b>0.547**</b>	0.161	0.099	0.187
<i>p</i>	<b>0.001</b>	<b>0.015</b>	0.499	0.686	0.443
RNFL Temp	0.437	<b>0.651**</b>	-0.059	0.340	-0.246
<i>p</i>	0.061	<b>0.003</b>	0.810	0.155	0.310
RIM VOLUME	-	<b>0.729**</b>	<b>0.551*</b>	0.059	0.060
<i>p</i>		<b>&lt; 0.001</b>	<b>0.015</b>	0.811	0.808
RIM AREA		-	0.293	0.449	-0.307
<i>p</i>			0.223	0.054	0.201
MD			0.279	-	<b>-0.564*</b>
<i>p</i>			0.247		<b>0.012</b>

Data are presented as Spearman's coefficient; \* – statistically significant;

\*\* – statistically highly significant.

RNFL – retinal nerve fiber layer; RNFL Avg – RNFL-Average; RNFL Sup – RNFL-Superior; RNFL Inf – RNFL Inferior; RNFL Nas – RNFL-Nasal; RNFL Temp – RNFL – Temporal; MD – mean deviation; CPSD – corrected pattern standard deviation.

**Table 4**  
**Correlation analysis of the studied parameters in patients with elevated intraocular pressure (HTG)**

Parameters	Rim volume	Rim area	Disk area	MD	CPSD
RNFL Avg	<b>0.627**</b>	<b>0.467*</b>	<b>-0.543**</b>	0.172	0.086
<i>p</i>	<b>0.001</b>	<b>0.019</b>	<b>0.005</b>	0.410	0.682
RNFL Sup	<b>0.484*</b>	0.285	<b>-0.610**</b>	-0.126	0.279
<i>p</i>	<b>0.014</b>	0.167	<b>0.001</b>	0.550	0.176
RNFL Inf	<b>0.508**</b>	0.377	<b>-0.462*</b>	0.348	-0.158
<i>p</i>	<b>0.010</b>	0.064	<b>0.019</b>	0.088	0.451
RNFL Nas	<b>0.422*</b>	<b>0.441*</b>	-0.192	0.140	0.135
<i>p</i>	<b>0.035</b>	<b>0.027</b>	0.358	0.505	0.521
RNFL Temp	0.257	0.346	-0.121	<b>0.454*</b>	<b>-0.470*</b>
<i>p</i>	0.214	0.090	0.566	<b>0.022</b>	<b>0.018</b>
Rim volume	-	<b>0.746**</b>	-0.018	-0.072	0.149
<i>p</i>		<b>&lt;0.001</b>	0.930	0.734	0.477
Rim area		-	-0.379	0.190	0.027
<i>p</i>			0.061	0.363	0.897
MD			-0.136	-	<b>-0.475*</b>
<i>p</i>			0.516		<b>0.016</b>

For explanation see under Table 3.

RNFL Inf and RNFL Temp ( $\rho = 0.418$ ,  $p = 0.038$ ), RNFL Inf and rim volume ( $\rho = 0.508$ ,  $p = 0.010$ ), RNFL Nas and rim volume ( $\rho = 0.422$ ,  $p = 0.035$ ), RNFL Nas and rim area ( $\rho = 0.441$ ,  $p = 0.027$ ), RNFL Temp and MD ( $\rho = 0.454$ ,  $p = 0.022$ ). The strongest correlation was found between RNFL Avg and RNFL Inf ( $\rho = 0.801$ ,  $p < 0.001$ ). A statistically significant negative correlation was found between RNFL

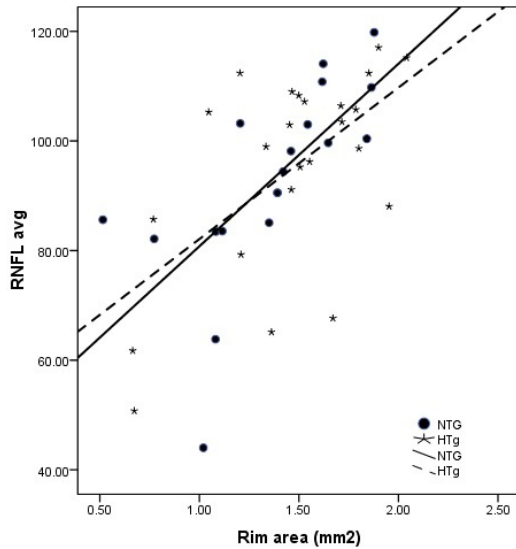
Temp and CPSD ( $\rho = -0.470$ ,  $p = 0.018$ ), RNFL Avg and disk area ( $\rho = -0.543$ ,  $p = 0.005$ ), RNFL Sup and disk area ( $\rho = -0.610$ ,  $p = 0.001$ ), RNFL Inf and disk area ( $\rho = -0.462$ ,  $p = 0.019$ ) (Table 4).

The strongest correlation was found between RNFL Avg and rim area ( $\rho = 0.847$ ,  $p < 0.001$ ) in the patients with NTG. This correlation was also statistically significant in pa-

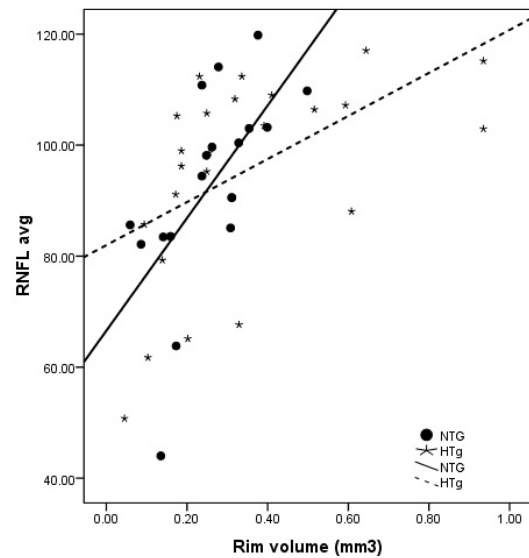
tients with HTG, RNFL Avg and rim area ( $\rho = 0.467$ ,  $p = 0.019$ ) (Figure 2). The correlation between RNFL Avg thickness and rim volume showed statistical significance in both groups of patients (NTG:  $\rho = 0.713$ ,  $p = 0.001$ , HTG:  $\rho = 0.627$ ,  $p = 0.001$ ) (Figure 3).

The study of correlation between changes in the visual

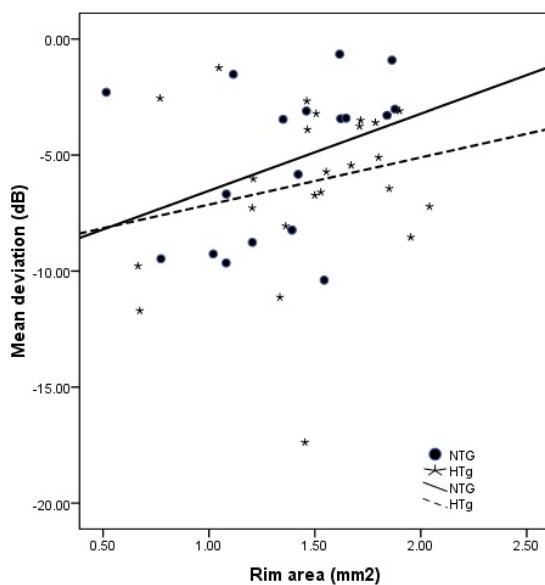
field MD and CPSD with RNFL Avg thickness and rim area in glaucomatous eyes did not find statistical significance in any of the groups of patients with POAG (Figures 4 and 5). Only statistically significant correlation existed between RNFL Temp and MD ( $\rho = 0.454$ ,  $p = 0.022$ ) and between RNFL Temp and CPSD ( $\rho = -0.470$ ,  $p = 0.018$ ) in the HTG patients.



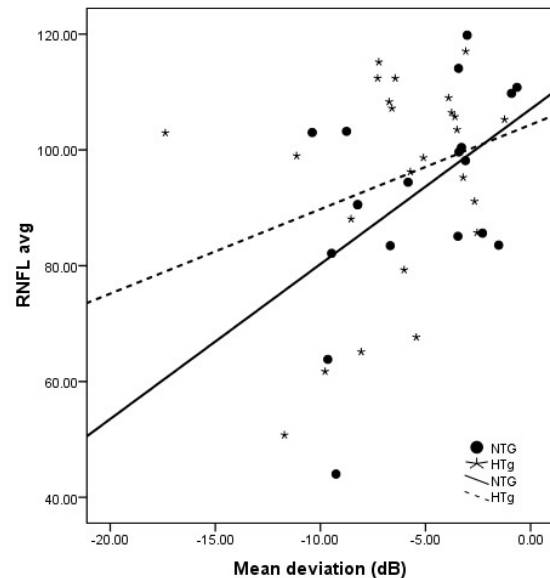
**Fig. 2 – Thickness of retinal nerve fiber layer average (RNFL Avg) ( $\mu\text{m}$ ) plotted versus the rim area ( $\text{mm}^2$ ) for normal intraocular pressure (NTG) and elevated intraocular pressure (HTG) patients (NTG:  $\rho = 0.847$ ,  $p < 0.001$ ; HTG:  $\rho = 0.467$ ,  $p = 0.019$ ).**



**Fig. 3 – Thickness of retinal nerve fiber layer average (RNFL Avg) ( $\mu\text{m}$ ) plotted versus the rim volume ( $\text{mm}^3$ ) for normal intraocular pressure (NTG) and elevated intraocular pressure (HTG) patients (NTG:  $\rho = 0.713$ ,  $p = 0.001$ ; HTG:  $\rho = 0.627$ ,  $p = 0.001$ ).**



**Fig. 4 – Mean deviation (MD) in dB plotted versus the rim area for normal intraocular pressure (NTG) and elevated intraocular pressure (HTG) patients (NTG:  $\rho = 0.449$ ,  $p = 0.054$ ; HTG:  $\rho = 0.190$ ,  $p = 0.363$ ).**



**Fig. 5 – Thickness of retinal nerve fiber layer Average (RNFL Avg) ( $\mu\text{m}$ ) plotted versus the mean deviation (MD, dB) for normal intraocular pressure (NTG) and elevated intraocular pressure (HTG) patients (NTG:  $\rho = 0.450$ ,  $p = 0.053$ ; HTG:  $\rho = 0.172$ ,  $p = 0.410$ ).**

## Discussion

Glaucoma is associated with the loss of retinal ganglion cells, which manifests as defects in the RNFL. The most important part of glaucoma diagnosis is the evaluation of the thickness of the retinal nerve fibers and changes of the optic disc. This can be assessed by OCT, as a good, objective and repeatable method. Also, OCT with its high axial resolution of 9–10  $\mu\text{m}$  is a much superior method than GDx VCC and Heidelberg retina tomograph (HRT) III<sup>1, 29</sup>. For a long time it was thought that there are different patterns of RNFL thinning occurring in patients with POAG with elevated IOP and without elevated IOP. Kubota et al.<sup>32</sup> found a difference in RNFL defects in patients with HTG and NTG. RNFL thickness was reduced symmetrically in the superior and inferior quadrants in HTG patients, whereas in patients with NTG a more localized RNFL loss in inferior quadrant occurs<sup>32, 35</sup>. Quite different results have appeared in recent years: there are no differences in RNFL thinning pattern between HTG and NTG, measured by OCT<sup>29</sup>. Our research also shows no differences in the defect pattern (localized or diffuse) of RNFL in HTG and NTG patients, and no differences in the amount of lost retinal nerve fibers of the two groups of patients. The strength of this statement is supplemented by the fact that the patients were at the same disease stage, with the same degree of structural damage of the optic nerve head and the same degree of change in the visual field (MD < 12 dB). In addition, all glaucoma patients had spherical equivalent (SE) within  $\pm 4$  Dsph, so the possibility of involving patients with very large or small optic nerve head (ONH) was reduced to a minimum. Our results are consistent with Mok et al.<sup>1, 34</sup>, and Konstantakopoulou et al.<sup>29</sup> published results, that patients with HTG and NTG showed a similar RNFL thinning pattern, which is a mixture of diffuse and localized changes, measured by OCT<sup>36</sup>.

Studying the localized RNFL loss by clock-hour sectors did not show any statistically significant difference, although this method provides more precise information on smaller fields of peripapillary nerve fiber loss. Furthermore, OCT parameters for inferotemporal and superotemporal sector, which are considered to be of great help for the early diagnosis of glaucoma and making a difference compared to healthy eyes, did not differ significantly between our groups of HTG and NTG patients<sup>1, 37</sup>. The study did not include pa-

tients with ocular hypertension as well as a healthy population because the differences between these two groups of patients with POAG patients are already tested and proven.

The results from this study related to age, gender, BCVA and morphological parameters of the optic nerve head did not differ significantly between the patients with HTG and NTG, and are fully in line with other publications<sup>2, 29, 34, 38</sup>. Only the IOP was significantly lower in patients with NTG ( $p = 0.009$ )<sup>2</sup>. Hüntzschel et al.<sup>2</sup> reported that visual acuity was significantly better in patients with NTG than in patients with HTG ( $p < 0.002$ ); we found that BCVA was higher in patients with NTG but there was no statistically significant difference compared to HTG patients ( $p = 0.160$ ), most likely due to better randomization. The sample size for this study is relatively small (38 NTG, 50 HTG), but it is in accordance with the groups studied by other authors: Mok et al.<sup>34</sup> (38NTG, 48HTG), and Konstantakopoulou et al.<sup>29</sup> (20NTG, 21 HTG).

Sihota et al.<sup>28</sup> found that defects in the visual field (MD) positively correlate with the thickness of RNFL superior, inferior, nasal, temporal and average, and that there is a negative correlation between RNFL (average, superior, nasal, inferior, temporal) parameters with CPSD. Shin et al.<sup>38</sup> reported the connection between MD and CPSD and RNFL Avg and RNFL Inf thickness parameters. Our results of two visual field indices (MD and CPSD) showed that there is a statistically significant positive correlation between RNFL Temp and MD ( $\rho = 0.454$ ,  $p = 0.022$ ) and negative correlation between RNFL Temp and CPSD ( $\rho = -0.470$ ,  $p = 0.018$ ), only in patients with HTG. This difference could be due to the difference in sample size and because the other authors compared the patients with POAG and healthy population<sup>28</sup>.

## Conclusion

OCT measurements of RNFL thickness provide clinically significant information in the monitoring of glaucomatous changes. There are no differences in RNFL thinning pattern *per* sectors and quadrants between NTG and HTG, as assessed by OCT. However, further larger studies are needed to supplement these findings view of the fact that it is known that RNFL thickness measurements and morphology of ONH have wide inter-individual and inter-racial variations.

## REFERENCES

1. Mok HK, Wing-Hong LV, So FK. Retinal Nerve Fiber Loss in High- and Normal-Tension Glaucoma by Optical Coherence Tomography. *Opto Vis Sci* 2004; 81(5): 369–72.
2. Hüntzschel J, Terai N, Sorgenfrei F, Hausteim M, Pillunat K, Pillunat LE. Morphological and functional differences between normal-tension and high-tension glaucoma. *Acta Ophthalmol* 2013; 91(5): 386–91.
3. Hüntzschel J, Terai N, Furashova O, Pillunat K, Pillunat LE. Comparison of Normal- and High-Tension Glaucoma: Nerve Fiber Layer and Optic Nerve Head Damage. *Ophthalmologica* 2014; 231(3): 160–5.
4. Sommer A, Katz J, Quigley HA. Clinically Detectable Nerve Fiber Atrophy Precedes the Onset of Glaucomatous Field Loss. *Arch Ophthalmol* 1991; 109(1): 77–81.
5. Gemenetzki M, Yang Y, Lotery AJ. Current concepts on primary open-angle glaucoma genetics: a contribution to disease pathophysiology and future treatment. *Eye* 2011; 26(3): 355–69.
6. Takai Y, Tanito M, Ohira A. Multiplex Cytokine Analysis of Aqueous Humor in Eyes with Primary Open-Angle Glaucoma, Exfoliation Glaucoma, and Cataract. *Invest Ophthalmol Vis Sci* 2011; 53(1): 241–7.

7. *Motolko M, Drance SM, Douglas GR.* Visual field defects in low-tension glaucoma. Comparison of defects in low-tension glaucoma and chronic open angle glaucoma. *Arch Ophthalmol* 1982; 100(7): 1074–77.
8. *Lewis RA, Hayreh SS, Phelps CD.* Optic Disk and Visual Field Correlations in Primary Open-Angle and Low-Tension Glaucoma. *Am J Ophthalmol* 1983; 96(2): 148–52.
9. *Miller KM, Quigley HA.* Comparison of optic disc features in low-tension and typical open-angle glaucoma. *Ophthalmic Surg* 1987; 18(12): 882–9.
10. *Iester M, Mikelberg FS.* Optic nerve head morphologic characteristics in high-tension and normal-tension glaucoma. *Arch Ophthalmol* 1999; 117(8): 1010–3.
11. *Nakatsue T, Shirakashi M, Yaeoda K, Funaki S, Funaki H, Fukushima A, et al.* Optic disc topography as measured by confocal scanning laser ophthalmoscopy and visual field loss in Japanese patients with primary open-angle or normal-tension glaucoma. *J Glaucoma* 2004; 13(4): 291–8.
12. *Caprioli J, Spaeth GL.* Comparison of visual field defects in the low-tension glaucomas with those in the high-tension glaucomas. *Am J Ophthalmol* 1984; 97(6): 730–7.
13. *Chauban BC, Drance SM, Douglas GR, Johnson CA.* Visual field damage in normal-tension and high-tension glaucoma. *Am J Ophthalmol* 1989; 108(6): 636–42.
14. *Chauban BC, McCormick TA, Nicoletta MT, LeBlanc RP.* Optic disc and visual field changes in a prospective longitudinal study of patients with glaucoma: comparison of scanning laser tomography with conventional perimetry and optic disc photography. *Arch Ophthalmol* 2001; 119(10): 1492–9.
15. *Thonginnetra O, Greenstein VC, Chu D, Liebmann JM, Ritch R, Hood DC.* Normal Versus High Tension Glaucoma: a Comparison of Functional and Structural Defects. *J Glaucoma* 2010; 19(3): 151–7.
16. *Hitchings RA, Anderton SA.* A comparative study of visual field defects seen in patients with low-tension glaucoma and chronic simple glaucoma. *Br J Ophthalmol* 1983; 67(12): 818–21.
17. *Caprioli J, Spaeth GL.* Comparison of the optic nerve head in high- and low-tension glaucoma. *Arch Ophthalmol* 1985; 103(8): 1145–9.
18. *Gramer E, Althaus G, Leydebecker W.* Site and depth of glaucomatous visual field defects in relation to the size of the neuroretinal edge zone of the optic disk in glaucoma without hypertension, simple glaucoma, pigmentary glaucoma. A clinical study with the Octopus perimeter 201 and th. *Klin Monbl Augenheilkd* 1986; 189(3): 190–8. (German)
19. *Yamagami J, Araie M, Shirato S.* A comparative study of optic nerve head in low- and high-tension glaucomas. *Graefes Arch Clin Exp Ophthalmol* 1992; 230(5): 446–50.
20. *Araie M, Yamagami J, Suzuki Y.* Visual field defects in normal-tension and high-tension glaucoma. *Ophthalmology* 1993; 100(12): 1808–14.
21. *Eid TE, Spaeth GL, Moster MR, Augsburger JJ.* Quantitative differences between the optic nerve head and peripapillary retina in low-tension and high-tension primary open-angle glaucoma. *Am J Ophthalmol* 1997; 124(6): 805–13.
22. *Kiriyama N, Ando A, Fukui C, Nambu H, Nishikawa M, Terauchi H, Matsumura M.* A comparison of optic disc topographic parameters in patients with primary open angle glaucoma, normal tension glaucoma, and ocular hypertension. *Graefes Arch Clin Exp Ophthalmol* 2003; 241(7): 541–5.
23. *Hee MR, Izatt JA, Swanson EA, Huang D, Schuman JS, Lin CP, et al.* Optical coherence tomography of the human retina. *Arch Ophthalmol* 1995; 113(3): 325–32.
24. *Huang D, Swanson EA, Lin CP, Schuman JS, Stinson WG, Chang W, et al.* Optical coherence tomography. *Science* 1991; 254(5035): 1178–81.
25. *Schuman JS, Hee MR, Arya AV, Pedut-Kloizman T, Puliafito CA, Fujimoto JG, et al.* Optical coherence tomography: a new tool for glaucoma diagnosis. *Curr Opin Ophthalmol* 1995; 6(2): 89–95.
26. *Schuman JS, Pedut-Kloizman T, Hertzmark E, Hee MR, Wilkins JR, Coker JG, et al.* Reproducibility of nerve fiber layer thickness measurements using optical coherence tomography. *Ophthalmology* 1996; 103(11): 1889–98.
27. *Budenz DL, Chang RT, Huang X, Knighton RW, Tielsch JM.* Reproducibility of retinal nerve fiber thickness measurements using the stratus OCT in normal and glaucomatous eyes. *Invest Ophthalmol Vis Sci* 2005; 46(7): 2440–3.
28. *Sibota R, Sony P, Gupta V, Dada T, Singh R.* Diagnostic capability of optical coherence tomography in evaluating the degree of glaucomatous retinal nerve fiber damage. *Invest Ophthalmol Vis Sci* 2006; 47(5): 2006–10.
29. *Konstantakopoulou E, Reeves BC, Fenerty C, Harper RA.* Retinal nerve fiber layer measures in high- and normal-tension glaucoma. *Optom Vis Sci* 2008; 85(7): 538–42.
30. *Yamazaki Y, Koide C, Miyazawa T, Kuwagaki N, Yamada H.* Comparison of retinal nerve-fiber layer in high- and normal-tension glaucoma. *Graefes Arch Clin Exp Ophthalmol* 1991; 229(6): 517–20.
31. *Woo SJ, Park KH, Kim DM.* Comparison of localized nerve fibre layer defects in normal tension glaucoma and primary open angle glaucoma. *Br J Ophthalmol* 2003; 87(6): 695–8.
32. *Kubota T, Khalil AK, Honda M, Ito S, Nishioka Y, Inomata H.* Comparative study of retinal nerve fiber layer damage in Japanese patients with normal- and high-tension glaucoma. *J Glaucoma* 1999; 8(6): 363–6.
33. *Kook MS, Sung K, Kim S, Park R, Kang W.* Study of retinal nerve fibre layer thickness in eyes with high tension glaucoma and hemifield defect. *Br J Ophthalmol* 2001; 85(10): 1167–70.
34. *Mok KH, Lee VW, So KF.* Retinal nerve fiber loss pattern in high-tension glaucoma by optical coherence tomography. *J Glaucoma* 2003; 12(3): 255–9.
35. *Thonginnetra O, Greenstein VC, Chu D, Liebmann JM, Ritch R, Hood DC.* Normal versus high tension glaucoma: a comparison of functional and structural defects. *J Glaucoma* 2010; 19(3): 151–7.
36. *Kim DM, Hwang US, Park KH, Kim SH.* Retinal nerve fiber layer thickness in the fellow eyes of normal-tension glaucoma patients with unilateral visual field defect. *Am J Ophthalmol* 2005; 140(1): 165–6.
37. *Kanamori A, Nakamura M, Escano MF, Seya R, Maeda H, Negi A.* Evaluation of the glaucomatous damage on retinal nerve fiber layer thickness measured by optical coherence tomography. *Am J Ophthalmol* 2003; 135(4): 513–20.
38. *Shin IH, Kang SY, Hong S, Kim SK, Seong GJ, Tak MK, et al.* Comparison of OCT and HRT findings among normal, normal tension glaucoma, and high tension glaucoma. *Korean J Ophthalmol* 2008; 22(4): 236–41.

Received on February 18, 2015.

Revised on March 19, 2015.

Accepted on April 2, 2015.

Online First April, 2016.