

# Validation of an Objective Scoring System for Forme Fruste Keratoconus Detection and Post-LASIK Ectasia Risk Assessment in Asian Eyes

Cordelia Chan, FRCS(Ed),\*† Marcus Ang, FRCS(Ed),\*† Alain Saad, MD,‡ Daniel Chua, MD,\* Margarita Mejia, MD,\* Li Lim, FRCS(Ed),\* and Damien Gatinel, MD, PhD‡

**Purpose:** To investigate the efficacy of the SCORE Analyzer (Bausch+Lomb TechnoLas, Germany) in detecting forme fruste keratoconus (FFKC) in Asian eyes and validate its usefulness as a risk assessment system for post-laser in situ keratomileusis (LASIK) keratectasia.

**Methods:** We retrospectively evaluated corneal topographies with the Orbscan Ilz system and independently tested them with the SCORE Analyzer through masked investigators. Eyes were classified into 2 groups: (1) The FFKC group included clinically and topographically normal eyes with definite keratoconus in the contralateral eye. (2) The control group included normal preoperative topographies of patients with LASIK performed at least 4 years before with no resultant keratectasia. The main outcome measures were accuracy indicators: sensitivity, specificity, positive, and negative predictive values. Parameters in the calculation of the SCORE including irregularity at 3 mm, thinnest pachymetry, the difference between central and thinnest pachymetry (CP – TP), vertical decentration of the thinnest point, maximum posterior elevation, and anterior elevation of the thinnest point were compared in both groups.

**Results:** We analyzed 128 Orbscans of 128 Asian patients. There were 24 FFKC eyes and 104 control eyes. SCORE was negative in 7 eyes (false negative) in the FFKC group and was positive in 2 eyes in the control group (false positive). The sensitivity was 70.8%, specificity 98.1%, positive predictive value 89.5%, and negative predictive value 93.6%. Irregularity at 3 mm, thinnest pachymetry, CP – TP, thinnest point decentration, maximum posterior elevation, and anterior elevation of the thinnest point were significantly different in both groups.

**Conclusions:** The SCORE Analyzer algorithm, developed and validated in white eyes, was found to be valid and consistent in Asian eyes, showing good sensitivity and specificity in FFKC

detection, and to be useful in objectively identifying cases at risk of post-LASIK keratectasia.

**Key Words:** corneal topography, forme fruste keratoconus, post-LASIK keratectasia

(*Cornea* 2015;00:1–9)

Keratectasia remains the most devastating corneal complication after undergoing laser in situ keratomileusis (LASIK), with undetected forme fruste keratoconus (FFKC) being the most important independent risk factor.<sup>1,2</sup> A major challenge for any corneal or refractive surgeon is the detection of keratoconus at its earliest stages.<sup>3,4</sup>

Various risk assessment and keratoconus detection systems have been described,<sup>2,5,6</sup> but no system is able to detect all cases of FFKC and predict unequivocally the risk of developing keratectasia after LASIK. Although it is important to have a heightened awareness of “at-risk” patients, it is also necessary to avoid overzealously excluding patients who may safely benefit from the life-changing spectacle and contact lens independence that LASIK provides. A simple yet reliable and objective topographic risk assessment system, with good specificity and sensitivity, would therefore be useful to increase the efficiency of screening for FFKC.

A study by Saad and Gatinel<sup>7</sup> found that the addition of elevation and tomography data in the evaluation of suspect corneas gives good sensitivity and specificity in detecting FFKC. The indices generated from corneal thickness and curvature measurements over the entire cornea centered on the thinnest point, and calculations of percentage changes in the thickness and anterior and posterior curvature variations are able to identify very mild forms of keratoconus undetected by Placido-based topography alone. This concept was used to create an artificial intelligence system that has since been incorporated into the SCORE Analyzer, software linked to the Orbscan Ilz corneal topography system (Bausch + Lomb TechnoLas, Munich, Germany) and designed to detect FFKC.

Keratoconus is generally accepted to be a bilateral disease. The incidence of “true” unilateral keratoconus is thought to be rare and controversial, with unilateral eye rubbing believed to be associated with some of these cases.<sup>8,9</sup> Eyes with no or low evidence of keratoconus (clinically and through Placido-based topography) in which the contralateral eye has definite keratoconus currently represent the best approach for

Received for publication March 25, 2015; revision received May 15, 2015; accepted May 19, 2015. Published online ahead of print XX XX, XXXX. From the \*Singapore National Eye Center, Singapore, Singapore; †Singapore Eye Research Institute, Singapore, Singapore; and ‡Rothschild Foundation, Paris, France.

D. Gatinel: Bausch+Lomb TechnoLas; A. Saad: Bausch+Lomb TechnoLas. The other authors have no funding or conflicts of interest to disclose.

Reprints: Damien Gatinel, MD, PhD, Fondation Ophtalmologique Adolphe de Rothschild, 25 Rue Manin, 75019 Paris, France (e-mail: gatinel@ gmail.com).

Copyright © 2015 Wolters Kluwer Health, Inc. All rights reserved.

AU2

AU3

E1

AU4

the detection of the mildest or subclinical form of the disease. This concept has been used in a number of validation studies for keratoconus.<sup>4,10,11</sup> Although there is currently no consensus on the proper terminology for these cases, it is generally accepted that they be defined as forme fruste keratoconus. The term forme fruste keratoconus was first proposed by Amsler<sup>12</sup> and then adopted by Klyce.<sup>13</sup> As explained by Klyce, “Both eyes of unilateral keratoconus have the same genetic makeup, and therefore the less affected eye already is known to have keratoconus. The fellow eye that has no clinical findings of any sort except for certain topographical changes should carry the diagnosis of forme fruste keratoconus.”<sup>14</sup> We adhered to these definitions and have chosen such eyes for our study.

There are inherent differences among eyes of different ethnicities, including the risk of myopia, risk, severity, and progression of keratoconus, and variations in corneal hysteresis and central corneal thickness, all related to a difference in the genetic makeup.<sup>13–16</sup> Differences in corneal topographic parameters between Asian and white ethnic groups have also been described.<sup>17</sup> The parameters generated in the algorithm of the SCORE Analyzer and the eyes used in its validation were from a group of white patients.<sup>7,18</sup> In this study, we tested the discriminating ability of the SCORE Analyzer for FFKC detection in a new and all-Asian group of patients, to determine whether algorithm adjustments are required when this system is used in Asian eyes.

## MATERIALS AND METHODS

This retrospective study was determined to be exempt from review by the Institutional Review Board and was conducted in accordance with the ethical principles that have their origin in the Declaration of Helsinki, and involved 128 eyes of 128 patients. All topographies from the Orbscan IIz system were obtained by experienced operators at the Singapore National Eye Center.

Because the SCORE Analyzer was designed to detect FFKC and to quantify the risk of keratectasia after LASIK, all patients included in the study were less than 45 years of age (the “ectasia-risk” group of patients). Eyes with a history of corneal injury, corneal scarring, ocular surgery, or ocular surface or other ophthalmic disease that may potentially affect the outcome of the study were also excluded, as were patients with possible corneal warpage from contact lens wear. All patients enrolled were without contact lens use for at least 1 week (soft contact lenses) or 2 weeks (rigid gas-permeable contact lenses) when topographies were performed.

The raw data examination (.EXM) file of the topographies were retrospectively collected with masking of the diagnosis and patient identifiers and were sent electronically to the Rothschild Foundation for testing with the SCORE Analyzer before it became commercially available. We classified our study eyes into 2 groups.

### Group 1: FFKC

The FFKC group involved clinically and topographically “normal” eyes with the contralateral eye showing frank keratoconus. These cases were obtained from the database of

patients with keratoconus from the Singapore National Eye Center. The diagnosis of keratoconus in the contralateral eye was reconfirmed by clinical examination and evaluation of topographies from the Orbscan IIz and Tomey keratoconus screening system (Topographic Modeling System, software version 2.4.2J, Tomey TMS-2N; Tomey Corp, Nagoya, Japan) by a corneal subspecialist (C.C.). Clinically evident keratoconus was defined by evidence of 1 or more slit-lamp biomicroscopic findings including conical protrusion of the cornea at the apex, Fleischer rings, Vogt striae, and corneal stromal thinning. Eyes included in this group were classified as “normal” if there were no clinical and topographic signs of keratoconus, including a negative Tomey keratoconus screening report [using the Klyce/Maeda keratoconus index (KCI) and the Smolek/Klyce index (KSI)]<sup>19,20</sup> and without a steep keratometric curvature of  $>47$  D, maximum posterior corneal elevation of  $>40$   $\mu\text{m}$ , and an asymmetric anterior keratographic pattern in the axial power map on the Orbscan.<sup>21–23</sup>

### Group 2: Controls

The control group involved normal preoperative topographies of patients who had myopic LASIK (with or without astigmatism) performed at least 4 years before with no resultant ectasia. One eye of each patient was randomly selected for inclusion in the study. These patients were determined to be normal post-LASIK either by examination and topography testing in the clinic or through a telephone interview using a detailed standardized questionnaire evaluating the patients’ visual function and symptoms that could suggest possible ectasia after LASIK. Patients with visual disturbances or unsatisfactory vision or those who provided dubious or equivocal responses to the questionnaire were immediately excluded. The preoperative Orbscans from these patients initially deemed to qualify for inclusion were also reevaluated, and any topography suspicious of keratoconus (as defined by the above criteria) was excluded.

The SCORE Analyzer is based on a linear regression analysis that constructs a set of linear functions of variables, known as discriminant functions.<sup>11</sup> It combines 12 Placido and tomographic indices in a weighted fashion to classify corneas as suspicious for keratoconus or normal. These variables include the thinnest pachymetry (TP), the difference between the central pachymetry and the thinnest pachymetry (CP – TP), thinnest point decentration (TPy), the difference between inferior and superior keratometry (I – S), posterior elevation of the thinnest point, the 3-mm irregularity, and data derived from the pachymetry thinning rate. Receiver operating characteristics (ROC) curves were plotted to obtain critical values that allowed accurate classification. The evaluation of these parameters in a systematic fashion to create an artificial intelligence and scoring system is the basis of the SCORE Analyzer. Elevation, Placido, and tomography data are acquired through the Orbscan IIz system. Using a large number of these specifically weighted-independent quantitative variables, the SCORE, or score number, is calculated. These variables were found to be statistically significantly different between tested populations, but not always when considered independently. Zero or a positive (nonnegative)

AU5

E2

numeral would indicate positive for keratoconus, and a negative numeral would indicate normal or negative for keratoconus. This allows objective quantification of the risk of keratoconus. The theory behind the derivation and calculation of the SCORE, including detailed descriptions of the Radar Map and pachymetry data graphs of the SCORE Analyzer, has been previously published.<sup>7,18</sup>

**AU6** All topographies in our study were tested with the SCORE Analyzer to determine the SCORE for each eye. Based on the SCORE of each of these topographies, results were classified as true positive, true negative, false positive, and false negative, from which sensitivity (true positive)/(true positive + false negative), specificity (true negative)/(true negative + false positive), positive predictive value (true positive)/(true positive + false positive), and negative predictive value (true negative)/(true negative + false negative) were calculated. The discriminant functions of the SCORE Analyzer including irregularity at 3 mm, TP, CP – TP, TPy, maximum posterior elevation (MPE), and anterior elevation of the thinnest point (AETP) were compared in both groups.

Groups of data were compared using the Fisher exact test and Mann–Whitney *U* test where appropriate. Differences were considered significant at *P* < 0.05. All statistical tests were performed using SPSS Version 20 (IBM Corporation, Armonk, NY).

## RESULTS

### Demographics

**T1** Table 1 shows the demographic data of both groups. There were more men in the FFKC group (*P* = 0.012). The mean age in both groups was not significantly different. The ethnic groups involved were Chinese, Malay, and Indian. The patients involved in both groups were predominantly Chinese (95.2% in the control group and 70.8% in the FFKC group), in keeping with the racial distribution in Singapore (according to the Census of Singapore Population 2010, the racial distribution in Singapore was 74% Chinese, 13% Malay, 9.2% Indian, and 3.8% other races) (Census of Population 2010 Statistical Release 1. Demographic Characteristics, Education, Language and Religion, ISBN 978-981-08-7808-5. Department of Statistics, Ministry of Trade & Industry, Republic of Singapore).

**AU7**

**TABLE 1.** Demographics

	Control (n = 104)	FFKC (n = 24)	<i>P</i>
Age, yrs			
Mean	29	30	
SD	5	5	0.4*
Race, n (%)			
Chinese	99 (95.2)	13 (70.8)	
Malay	2 (1.9)	6 (25.0)	
Indian	3 (2.9)	1 (4.2)	<0.001†
Male, n (%)	43 (41.3)	17 (70.8)	0.012†

\*Independent samples Mann–Whitney *U* test.

†Fisher exact test.

### Sensitivity and Specificity

Of the 24 FFKC eyes, 7 were classified as normal by the SCORE Analyzer (false negative). Of the 104 control eyes, 2 were classified as positive (false positive). Based on these, the sensitivity was 70.8%, specificity 98.1%, positive predictive value 89.5%, and negative predictive value 93.58%.

**E3**

### Control Versus FFKC Groups

The irregularity at 3 mm, TP, CP – TP, TPy, MPE, and AETP were all statistically significantly different in both groups. Table 2 summarizes the results.

**T2**

**T3**

Table 3 shows the various indices and differences within the FFKC group, comparing the true positives and false negatives. The CP – TP and TPy were different in the true-positive group compared with the false-negative group. Both parameters in the false-negative group seem normal.

**T4**

Table 4 shows the comparison of parameters within the control group. Both false positives have relatively thin corneas (TP slightly beyond 500 μm), partially explaining the positive SCORE. Other parameters were similar in both groups. However, these observations were limited by the small sample size of the false-positive group (n = 2), and therefore tests of statistical significance have little value.

### CASE EXAMPLES

Example 1 describes a true-negative (normal) case demonstrated by a normal Orbscan Quad Map (Fig. 1A) corroborated with a normal Radar Map, pachymetry data graphs (meridionally averaged pachymetry and pachymetry

**F1**

**TABLE 2.** Comparison Between the Control and FFKC Groups

**AU9**

	Control (n = 104)	FFKC (n = 24)	<i>P</i>
Irregularity at 3 mm, D			
Mean	1.14	1.28	
SD	0.15	0.26	0.009*
TP, μm			
Mean	546.2	500.9	
SD	27.8	27.4	<0.001*
CP – TP			
Mean	3	6.69	
SD	2.65	5.76	0.001*
TPy			
Mean	–0.34	–0.51	
SD	0.24	0.31	0.004*
MPE			
Mean	0.024	0.038	
SD	0.0068	0.013	<0.001*
AETP			
Mean	0.009	0.014	
SD	0.004	0.0066	<0.001*

\*Independent samples Mann–Whitney *U* test.

†Fisher exact test.

All parameters compared were statistically significantly different in both groups.

**TABLE 3.** Comparing the True-Positive and False-Negative Cases Within the FFKC Group

	True Positive (n = 17)	False Negative (n = 7)	P
Irregularity at 3 mm, D			
Mean	1.33	1.13	0.099*
SD	0.27	0.15	
TP, $\mu\text{m}$			
Mean	498.6	506.6	0.62*
SD	30.6	18.5	
CP – TP			
Mean	8.68	1.87	<0.001*
SD	5.71	1.32	
TPy			
Mean	-0.6	-0.31	0.005*
SD	0.33	0.13	
MPE			
Mean	0.04	0.033	0.21*
SD	0.014	0.009	
AETP			
Mean	0.014	0.014	0.8*
SD	0.007	0.007	

\*Independent samples Mann–Whitney *U* test.

†Fisher exact test.

CP – TP and TPy were different in both groups. Both parameters in the false-negative group seem normal, explaining the negative SCORE.

thinning rate), and a corresponding negative SCORE of -1.8 (Fig. 1B).

Example 2 shows a true-positive case. Frank keratoconus is seen in the right eye (Fig. 2A(ii)) with a normal-appearing Quad Map in the left (Fig. 2A(i)). The Tomey scan is negative for keratoconus in the left eye (Fig. 2B(i)) but positive in the right (Fig. 2B(ii)). However, a positive SCORE of 1.2 was generated for the left (Fig. 2C). The combination of 12 parameters used for the SCORE calculation, including the abnormal I – S value, lead to a positive SCORE in this case.

Example 3 also demonstrates a true-positive case, in which frank keratoconus is seen in the right eye (Fig. 3A(ii)). A normal Orbscan Quad Map is seen for the left eye (Fig. 3A(i)), but the SCORE generated is positive at 1.1 (Fig. 3B). The positive SCORE is a result of a thin cornea, increase in the pachymetry thinning rate, and borderline inferior decentration of the thinnest point.

Example 4 shows a false-positive case. The Orbscan Quad Map (Fig. 4A) shows mild inferior steepening but is otherwise normal. A Tomey scan (Fig. 4B) is normal for this eye. The SCORE is borderline positive at 0.7 because of an abnormal I – S value and an increased pachymetry thinning rate (Fig. 4C). The patient subsequently had LASIK with no resultant ectasia to date (4 years after surgery).

Example 5 demonstrates a false-negative case. There is frank keratoconus in the left eye (Fig. 5A(ii)), and the Orbscan Quad Map of the contralateral (right) eye appears normal (Fig. 5A(i)). The cornea in the right eye is borderline thin (503  $\mu\text{m}$ ); there is a borderline increase in the

**TABLE 4.** Comparing the True-Negative and False-Positive Cases in the Control Group

	True Negative (n = 102)	False Positive (n = 2)
Irregularity at 3 mm, D		
Mean	1.14	1.13
SD	0.15	0.011
TP, $\mu\text{m}$		
Mean	546.9	508.9
SD	27.5	25.0
CP – TP		
Mean	3.01	2.42
SD	2.67	0.77
TPy		
Mean	-0.34	-0.32
SD	0.24	0.042
MPE		
Mean	0.02	0.027
SD	0.007	0.009
AETP		
Mean	0.009	0.01
SD	0.004	0.008

The false positives have relatively thin corneas (TP slightly beyond 500  $\mu\text{m}$ ), partially explaining the positive SCORE, but the number in this group (n = 2) is too small for tests on statistical significance. Other parameters were similar in both groups.

pachymetry thinning rate, but the overall SCORE is borderline negative at -0.3 (Fig. 5B).

Example 6 is another false-negative case. Keratoconus is obvious in the left eye (Fig. 6A(ii)). The Orbscan Quad Map of the fellow eye appears normal (Fig. 6A(i)) and SCORE is negative at -1.0 (Fig. 6B). Anterior and posterior elevation in the right eye and the Placido topography appear within normal limits. The pachymetry thinning rate is however borderline, and should alert us, despite a negative SCORE.

### Descriptive Analyses of SCORE Values in Various Groups

Figure 7 shows a comparison of the spread of SCORE values for each of the true-positive, true-negative, false-positive, and false-negative groups. The median value was 1.9 for the true-positive group, -2.0 for the true-negative group, 0.5 for the false-positive group, and -0.6 for the false-negative group. The SCORE values for the 2 false-positive cases were 0.4 and 0.7. In the false-negative group, 5 cases were -1.0 or less, whereas there were 2 outliers at -1.2 and -1.3.

### DISCUSSION

Keratectasia after LASIK is a devastating complication despite its low incidence (0.04%–0.6%),<sup>24</sup> which often results in permanent visual impairment and in severe cases in a need for corneal transplantation. Corneas with normal topographies preoperatively have been described to have developed ectasia after LASIK.<sup>25</sup> Individual parameters obtained during topography including keratometry >47 diopters (defined as

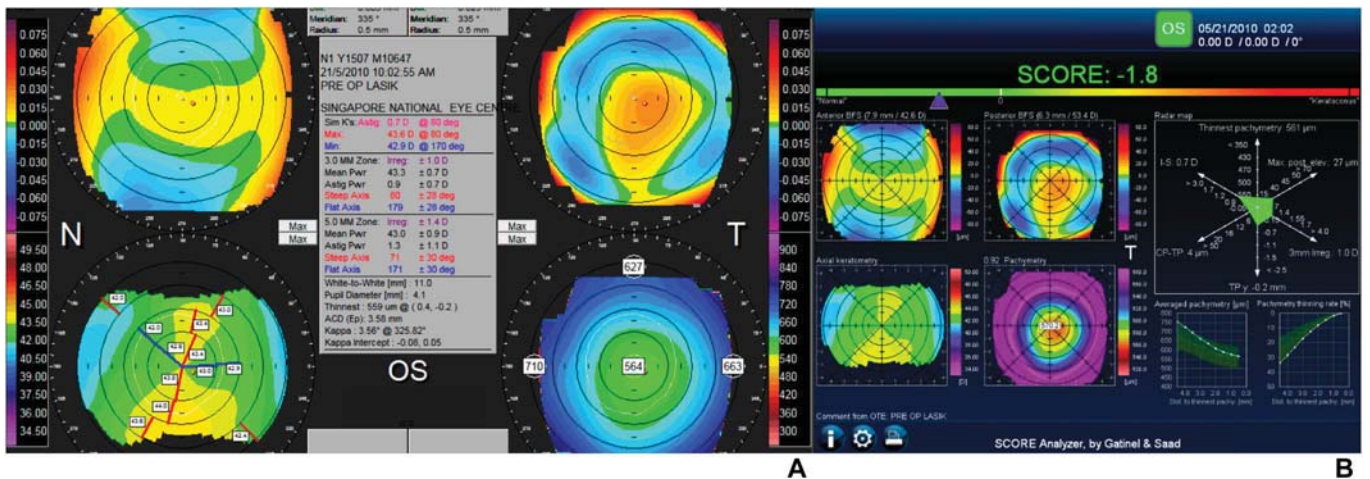


FIGURE 1. Example 1: True negative. A, Normal Orbscan Quad Map. B, Corresponding negative SCORE.

a “steep” K),<sup>21</sup> abnormal inferior keratometry minus superior keratometry (I – S) values (as defined by Rabinowitz and McDonnell),<sup>26</sup> and a thin cornea (<500 μm)<sup>27</sup> are not necessarily indicative of keratoconus, and when considered alone, may generate false positives.

Newer concepts such as elevation-based topography, spatial profile measurements of the cornea, and assessment of the viscoelastic properties of the cornea with the ocular response analyzer have paved the way for better and earlier FFKC detection.<sup>4,6,28,29</sup> Bühren et al<sup>4</sup> showed that corneal wavefront and thickness spatial profile data enabled highly accurate distinction of eyes with FFKC from normal eyes. With the dual Scheimpflug GALILEI Analyzer (Ziemer Ophthalmic Systems AG, Port, Switzerland), Smadja et al<sup>6</sup> demonstrated that the discriminating ability for normal

corneas compared with FFKC cases improved by using corneal elevation measurement obtained by best-fit toric and aspheric reference surfaces.

Ambrosio et al<sup>6</sup> described a corneal thickness spatial profile, corneal volume distribution, percentage increase in thickness, and percentage increase in the volume to be different in normal and keratoconic corneas with the use of the OCULUS Pentacam system (Oculus Optikgerate GmbH). A new parameter developed for this system, the Belin/Ambrosio-enhanced ectasia display D index (BAD-D index), which is derived from keratometric, pachymetric, and posterior elevation data and described by the manufacturers as an individual parameter that can be used for the identification of patients with early keratoconus at a risk of progression to ectasia after corneal laser refractive surgery,<sup>31,32</sup> was recently

E5  
E6

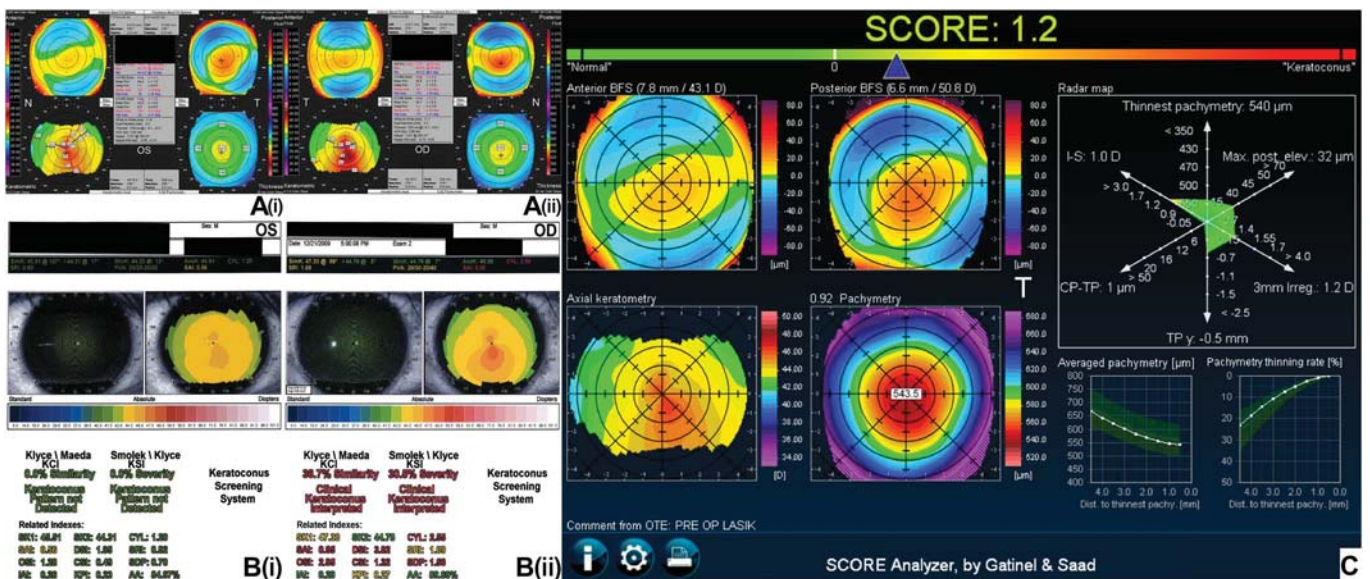
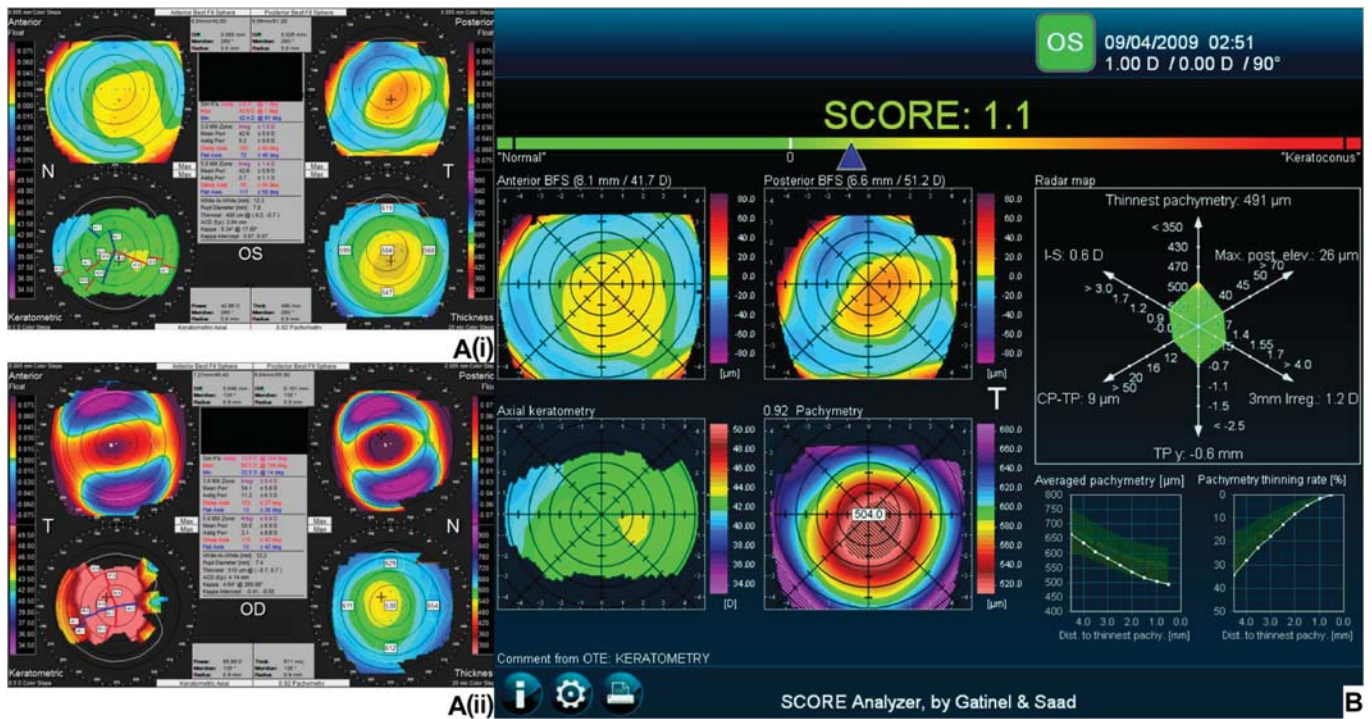


FIGURE 2. Example 2: True positive. A, Orbscan Quad Maps of both eyes, with a normal scan in OS (A(i)) and keratoconus in OD (A(ii)). These correlate with Tomy scans in (B) with no keratoconus in OS (B(i)) and keratoconus present in OD (B(ii)). C, Positive SCORE with the Radar Map showing an abnormal I – S value.

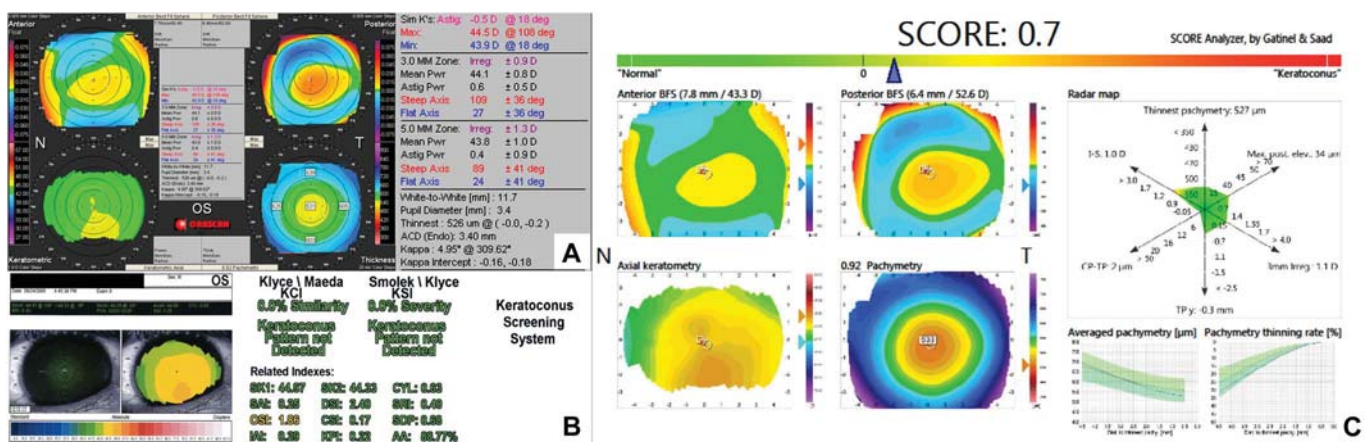


**FIGURE 3.** Example 3: True positive. A(i), Normal Quad Map in OS and A(ii) keratoconus in OD. B, Positive SCORE. The cornea is thin at 490  $\mu\text{m}$ , there is an increase in the pachymetry thinning rate and the inferior decentration of the thinnest point is borderline, giving rise to a positive SCORE.

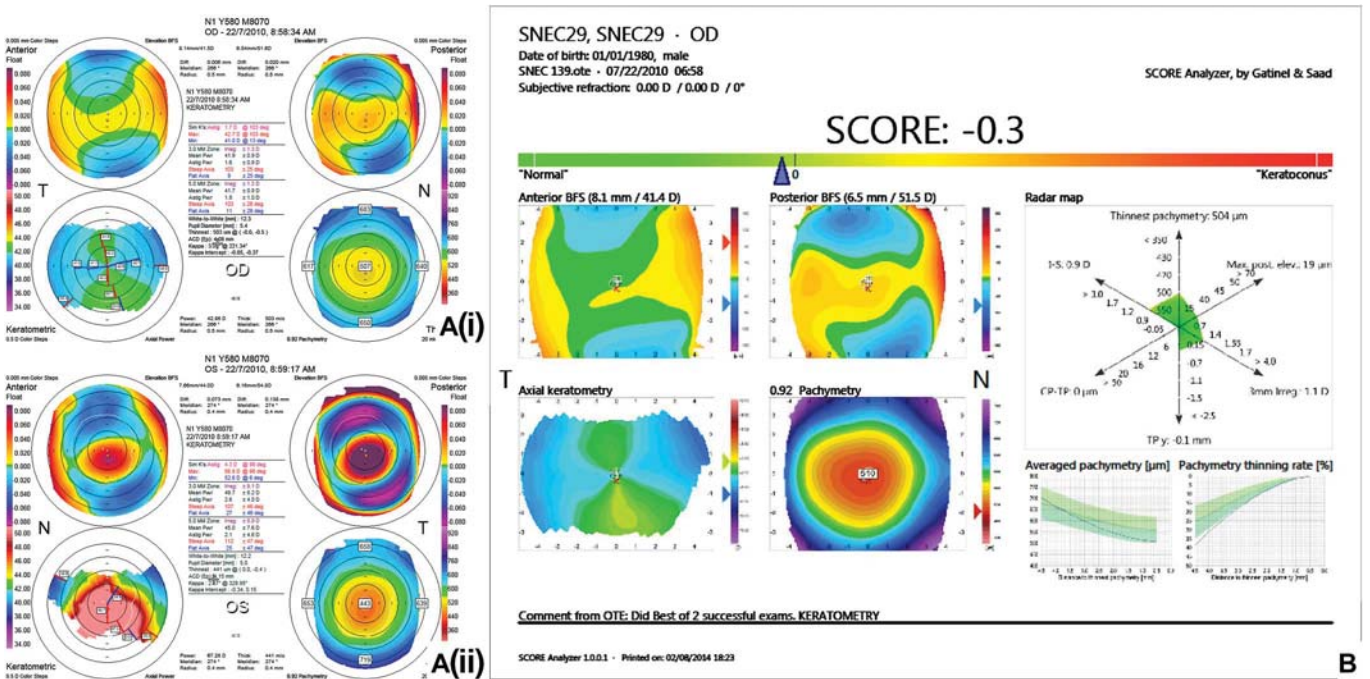
independently evaluated.<sup>10</sup> The D index was found to have a sensitivity of 60% in differentiating eyes with subclinical keratoconus from normal eyes, which suggests that false negatives are possible with this system and FFKC may be missed. Muftuoglu et al concluded that other topographic parameters with higher sensitivities were required to more effectively screen eyes for their susceptibility to ectasia after LASIK. These newer topographic tools have improved the screening and detection of FFKC, but to our knowledge, they have not been independently validated in Asian eyes, and no

comparative studies between these systems with the Orbscan IIz and SCORE Analyzer have been performed.

The Orbscan IIz uses slit scanning technology combined with a Placido disc system for corneal topographic analysis. In a study of corneal thickness, curvature, and elevation parameters in normal corneas, the Orbscan II was compared with the combined Placido-Scheimpflug system, the TMS-5 topographer (Topographic Modeling System, version 5; Tomey Corp, Nagoya, Japan) using 50-MHz ultrasound pachymetry as a reference for central corneal



**FIGURE 4.** Example 4: False positive. Orbscan Quad Map (A) shows mild inferior steepening, but is otherwise normal. The Tomey scan in B is negative for keratoconus. SCORE (C) is borderline positive because of the abnormal I – S value and increased pachymetry thinning rate.

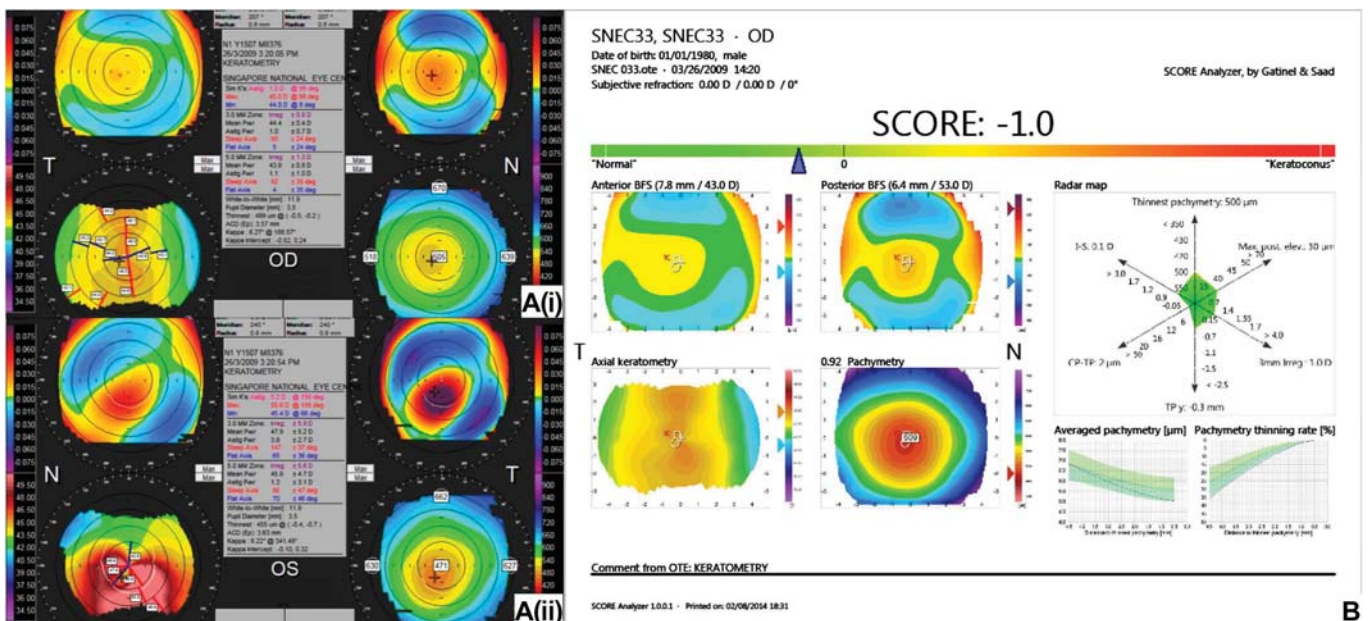


**FIGURE 5.** Example 5: False negative. A(i), Normal Orbiscan Quad Map in OD and (A(ii)) shows frank keratoconus in OS. B, Negative SCORE. The Radar Map hints of a borderline I – S value, and slight increase in the pachymetry thinning rate, but overall the SCORE is borderline negative.

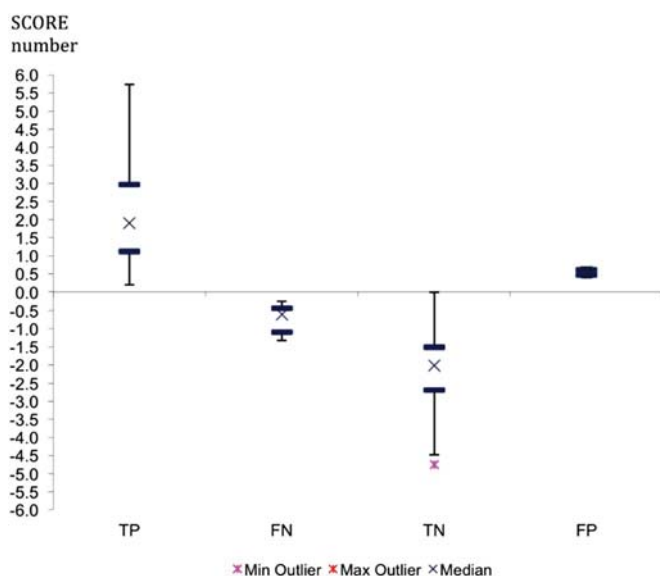
thickness measurements.<sup>53</sup> The authors found that the Orbiscan Ilz system correlated well with the newer TMS-5, and the central corneal thickness values obtained from the Orbiscan were very similar to those from the ultrasound pachymeter. Repeatability was excellent, with consistency achieved for 3 successive pachymetry and keratometry measurements as

well as anterior and posterior best-fit sphere calculations. However, despite its reliability and repeatability, the Orbiscan Ilz system, without input from the SCORE Analyzer, does not provide any objective indices for FFKC detection.

Using data obtained from the Orbiscan, through linear discriminant analysis, the SCORE Analyzer builds a model to



**FIGURE 6.** Example 6: False negative. A(i), Normal Quad Map of OD and (A(ii)) frank keratoconus in OS. SCORE (B) is negative for OD. Anterior and posterior elevation appears within normal limits. The pachymetry thinning rate is however borderline.



**FIGURE 7.** Box and whisker plot for SCORE analyzer values. The Figure shows the range and spread of the SCORE numbers in the various groups. The median value is 1.9 for TP,  $-0.6$  for FN,  $-2.0$  for TN, and  $0.5$  for FP. FN, false negative; FP, false positive; TP, true positive; TN, true negative.

discriminate between healthy versus FFKC corneas.<sup>7,18</sup> The SCORE, expressed as a single number, by its negativity or positivity, aims to objectively indicate the risk of FFKC, or to the refractive surgeon, the risk for keratectasia. In addition, the absolute numerical value of the SCORE (how positive or negative) could provide the clinician with information on the magnitude of the risk. A further advantage described would be to help clinicians analyze the natural progression of the keratoconic disease.<sup>18,34</sup>

The subjects in derivation and validation studies by Saad and Gatinel<sup>7,18</sup> were whites. Our study was performed in an all-Asian group of patients and found the discriminating parameters including irregularity at 3 mm, TP, CP – TP, TPy, MPE, and AETP to be valid and consistent when tested between the FFKC and control groups. It thus seems that the SCORE Analyzer is robust to any inherent differences between white and Asian eyes<sup>13–16</sup> and no discriminant function adjustments for this system are required for the Asian group of patients.

Our study achieved a specificity of 98.1%, with 2 false positives in the control group. The topographies in the control group were classified as normal based on the subjective interpretation of the Orbscans by the attending refractive surgeon, unlike the study by Saad and Gatinel<sup>7</sup> in which all eyes in both groups were also classified using objective Placido analysis with the Nidek Corneal Navigator. The 2 false positives in our study had relatively thin corneas (slightly beyond 500  $\mu\text{m}$ ) and arguable mild anterior curvature asymmetry on the Orbscan. However, the Tomey scan was negative for keratoconus in these eyes, and so the Orbscan changes were deemed unremarkable by the surgeon, who performed LASIK, with no evidence of ectasia 4 years after surgery. The SCORE Analyzer has classified these eyes

as positive, and whether these eyes develop ectasia subsequently remains to be seen.

Our study failed to detect FFKC in 7 of 24 such eyes (false negative). The CP – TP and TPy, important contributors to the discriminant function,<sup>7</sup> were significantly different in the eyes in this false-negative group, compared with those in the true-positive group, in which the SCORE Analyzer was able to detect the FFKC. Both of these parameters were normal in the false-negative group, which would explain the negative SCORE. However, we are unable to conclude unequivocally whether these “missed” cases were true unilateral cones or failure of the SCORE Analyzer to detect the FFKC. Despite this, with a sensitivity of 70.8% and positive predictive value of 89.5%, the majority of the FFKC cases were identified. This sensitivity relates to the identification of very early forms of the disease, in which topographic analysis from anterior curvature data alone with their corresponding Placido map analyses using objective tools such as the Klyce/Maeda keratoconus index (KCI) and the Smolek/Klyce index (KSI) was not sensitive enough, failing to reach the threshold of FFKC detection or raising any suspicion whatsoever of a possibility of keratoconus. By being able to successfully identify more than two-thirds of such subclinical or very early forms of the disease, the majority of keratoconus cases would be detected by the SCORE Analyzer.

In the study by Saad and Gatinel,<sup>7</sup> the sensitivity obtained was much higher at 93%. The sensitivities and specificities in their work were obtained using data from the training model, whereby the observation used to calculate the model was itself used in the validation. Although cross-validation was performed, using data in such a manner would usually generate higher sensitivities and specificities. A more accurate method of validating the function would be to use a new and external group of patients, as we have done in this study. Another possible explanation for the difference in sensitivities in the 2 studies is the use of different topography systems (in addition to the Orbscan) in the screening of eyes with keratoconus. In the study by Saad and Gatinel, the eyes were screened with the Nidek Corneal Navigator, and in this study, the TMS system was used.

Based on the results of our study, it seems that the SCORE Analyzer’s individual discriminant functions do not require adjustment in Asian eyes. However, descriptive analyses of SCORE values for the false-negative and false-positive groups showed that the values were close to zero, with the median at  $-0.6$  and  $0.5$ , respectively. Based on these findings, to optimize the screening of cases with this system, we suggest that SCORE values falling within the  $-0.6$  and  $0.5$  interval be characterized as equivocal and additional testing for confirmation of its significance be at the discretion of the attending ophthalmologist.

The limitations of our study include its retrospective nature, and possible selection bias in obtaining the topographies. For the controls, it was important to include patients who underwent LASIK at least a few years ago for a definitive ectasia-free history. Ideally, all patients in the control group should have clinical examination and topography to exclude ectasia. Given the difficulty in retrospectively gathering a large sample size of these normal patients at least



4 years after LASIK, we opted to conduct a telephone interview to recruit some of these patients, but with stringent guidelines and a standardized questionnaire to determine whether the patients had any visual disturbances or symptoms suggestive of ectasia. Patients with visual problems or those who provided dubious or equivocal responses to the questionnaire were immediately excluded from the study.

In the control group, a disproportionately high percentage of patients were Chinese (95.2% vs. 70.8% in the FFKC group). In Singapore, the prevalence of myopia is high in the Chinese population<sup>35</sup> and LASIK candidates in Singapore are predominantly Chinese.<sup>36</sup> By our methodology, subjects in the control group consisted of patients who have had LASIK, and this accounts for the high percentage of Chinese in the group. Because there were very few Malays and Indians in both the control and FFKC groups, it was not possible to further validate and compare the SCORE Analyzer algorithm in these individual ethnic groups.

Our study achieved a specificity of 98.1%. This implies that the SCORE Analyzer would unlikely wrongly identify and unnecessarily exclude normal eyes from LASIK. However, the system quantifies only the topographic risk for ectasia. Ultimately, the final decision on LASIK suitability will depend on other clinical features including patient age, refraction, and other factors.

Work is in progress to further evaluate the efficacy of the SCORE Analyzer by retrospectively testing it on the preoperative Orbscan topographies of patients with ectasia after LASIK. The study aims to substantiate the usefulness of the SCORE Analyzer as a screening tool and risk assessment system for post-LASIK ectasia.

## REFERENCES

- Binder PS. Ectasia after laser in situ keratomileusis. *J Cataract Refract Surg.* 2003;29:2419–2429.
- Randleman JB, Woodward M, Lynn MJ, et al. Risk assessment for ectasia after corneal refractive surgery. *Ophthalmology.* 2008;115:37–50.
- Klyce SD. Chasing the suspect: keratoconus. *Br J Ophthalmol.* 2009;93:845–847.
- Buhren J, Kook D, Yoon G, et al. Detection of subclinical keratoconus by using corneal anterior and posterior surface aberrations and thickness spatial profiles. *Invest Ophthalmol Vis Sci.* 2010;51:3424–3432.
- Rabinowitz YS, Rasheed K. KISA % index: a quantitative video-keratography algorithm embodying minimal topographic criteria for diagnosing keratoconus. *J Cataract Refract Surg.* 1999;25:1327–1335.
- Ambrosio R Jr, Alonso RS, Luz A, et al. Corneal-thickness and spatial profile and corneal-volume distribution: tomographic indices to detect keratoconus. *J Cataract Refract Surg.* 2006;32:1851–1859.
- Saad A, Gatinel D. Topographic and tomographic properties of forme fruste keratoconus corneas. *Invest Ophthalmol Vis Sci.* 2010;51:5546–5555.
- Philips AJ. Can true monocular keratoconus occur? *Clin Exp Optom.* 2003;86:399–402.
- McMonnies CW. The evidentiary significance of case reports: eye rubbing and keratoconus. *Optom Vis Sci.* 2008;85:262–269.
- Muftuoglu O, Ayar O, Hurmeric V, et al. Comparison of multimetric D index with keratometric, pachymetric, and posterior elevation parameters in diagnosing subclinical keratoconus in fellow eyes of asymmetric keratoconus patients. *J Cataract Refract Surg.* 2015;41:557–565.
- Arbelaez MC, Versaci F, Vestri G, et al. Use of a support vector machine for keratoconus and subclinical keratoconus detection by topographic and tomographic data. *Ophthalmology.* 2012;119:2231–2238.
- Amsler M. The “forme fruste” of keratoconus [in German]. *Wien Klin Wochenschr.* 1961;73:842–843.
- Georgiou T, Funnell CL, Cassels-Brown A, et al. Influence of ethnic origin on the incidence of keratoconus and associated atopic disease in Asian and white patients. *Eye (Lond).* 2004;18:379–383.
- Pearson AR, Soneji B, Sarvananthan N, et al. Does ethnic origin influence the incidence or severity of keratoconus? *Eye (Lond).* 2000;14:625–628.
- Haseltine SJ, Pae J, Ehrlich JR, et al. Variation in corneal hysteresis and central corneal thickness among black, hispanic and white subjects. *Acta Ophthalmol.* 2012;90:e626–631.
- Kok YO, Tan GFL, Loon SC. Review: keratoconus in Asia. *Cornea.* 2012;31:581–593.
- Hickson-Curran S, Brennan NA, Igarashi Y, et al. Comparative evaluation of Asian and white ocular topography. *Optom Vis Sci.* 2014;91:1396–1405.
- Saad A, Gatinel D. Validation of a new scoring system for the detection of early forme of keratoconus. *Int J Kerat Ect Cor Dis.* 2012;1:100–108.
- Smolek MK, Klyce SD. Current keratoconus detection methods compared with a neural network approach. *Invest Ophthalmol Vis Sci.* 1997;38:2290–2299.
- Maeda N, Klyce SD, Smolek MK, et al. Automated keratoconus screening with corneal topography analysis. *Invest Ophthalmol Vis Sci.* 1994;35:2749–2757.
- Rabinowitz YS. Videokeratographic indices to aid in screening for keratoconus. *J Refract Surg.* 1995;11:371–379.
- Rao SN, Raviv T, Majmudar PA, et al. Role of Orbscan II in screening keratoconus suspects before refractive corneal surgery. *Ophthalmology.* 2002;109:1642–1646.
- Rabinowitz YS. Keratoconus. *Surv Ophthalmol.* 1998;42:297–319.
- Pallikaris IG, Kymionis GD, Astyrakakis NI. Corneal ectasia induced by laser in situ keratomileusis. *J Cataract Refract Surg.* 2001;27:1796–1802.
- Lifshitz T, Levy J, Klemperer I, et al. Late bilateral keratectasia after LASIK in a low myopic patient. *J Refract Surg.* 2005;21:494–496.
- Rabinowitz YS, McDonnell PJ. Computer-assisted cornea topography in keratoconus. *Refract Corneal Surg.* 1989;5:400–408.
- Pflugfelder SC, Liu Z, Feuer W, et al. Corneal thickness indices discriminate between keratoconus and contact lens-induced corneal thinning. *Ophthalmology.* 2002;109:2336–2341.
- Schlegel Z, Hoang-Xuan T, Gatinel D. Comparison of and correlation between anterior and posterior corneal elevation maps in normal eyes and keratoconus-suspect eyes. *J Cataract Refract Surg.* 2008;34:789–795.
- Touboul D, Benard A, Mahmoud AM, et al. Early biomechanical keratoconus pattern measured with an ocular response analyzer: curve analysis. *J Cataract Refract Surg.* 2011;37:2144–2150.
- Smadja D, Santhiago MR, Mello GR, et al. Influence of the reference surface shape for discriminating between normal corneas, subclinical keratoconus and keratoconus. *J Refract Surg.* 2013;29:274–281.
- Belin MW, Khachikian SS. Keratoconus/ectasia detection with the Oculus Pentacam: Belin/Ambrosio enhanced ectasia display. In: *New Advances and Technology With the Pentacam.* Wetzlar, Germany: Oculus Optikgerate GmbH; 2008: 3–7. Available at: [http://pentacam.com/downloads/studien/oculus\\_low\\_res.pdf](http://pentacam.com/downloads/studien/oculus_low_res.pdf). Accessed March 14, 2015.
- Ambrosio R Jr. Defining the risky cornea with enhanced corneal analysis technology. Presented at the XXXI Congress of the European Society of Cataract and Refractive Surgeons and the 4th Eurocornea Congress; October 2013; Amsterdam, the Netherlands. *European Ophthalmology News* Oct 2013, Page 9. Available at: [http://www.oculus.de/fileadmin/images/news\\_termine/European\\_Ophthalmology\\_Times\\_ESCRS2014.pdf](http://www.oculus.de/fileadmin/images/news_termine/European_Ophthalmology_Times_ESCRS2014.pdf). Accessed March 14, 2015.
- Guilbert E, Saad A, Grise-Dulac A, et al. Corneal thickness, curvature and elevation readings in normal corneas: combined Placido-Scheimpflug system versus combined Placido-scanning-slit system. *J Cataract Refract Surg.* 2012;38:1198–1206.
- Gatinel D, Saad A. The challenges of the detection of subclinical keratoconus at its earliest stage. *Int J Keratoco Ectatic Corneal Dis.* 2012;1:36–43.
- Pan CW, Zheng YF, Anuar AR, et al. Prevalence of refractive errors in a multiethnic Asian population: the Singapore epidemiology of eye disease study. *Invest Ophthalmol Vis Sci.* 2013;54:2590–2598.
- Yuen LH, Chan WK, Koh J, et al. A 10-year prospective audit of LASIK outcomes for myopia in 37,932 eyes at a single institution in Asia. *Ophthalmology.* 2010;117:1236–1244.

AU8