

Keratoconus Expert Meeting, London, 2014

¹Ramez Barbara, ²Jamyl Habib Castillo, ³Rana Hanna, ⁴Eran Berkowitz, ⁵Beatrice Tiosano, ⁶Adel Barbara

¹Doctor, I Vision Refractive Surgery Center, Haifa, Israel

²⁻⁴Resident, Department of Ophthalmology, Hillel Yaffe Medical Center, Hadera, Israel

⁵Director, Department of Ophthalmology, Hillel Yaffe Medical Center, Hadera, Israel

⁶Medical Director, I Vision Refractive Surgery Center, Haifa, Israel

Corresponding Author: Adel Barbara, Doctor, I Vision Refractive Surgery Center, Haifa, Israel, e-mail: adelbarbara@yahoo.com

PRESENTATION 1

Indication for Collagen Corneal Cross-linking in Children

Farhad Hafezi

Laboratory for Ocular Cell Biology, University of Geneva, Switzerland; Department of Ophthalmology, University of Southern California Los Angeles, CA, USA; The ELZA Institute, Dietikon/Zurich, Switzerland

Professor Hafezi discussed how quickly keratoconus (KC) in childhood and adolescence can progress in its natural course, and provided an example of one patient's images taken 3 months apart (Fig. 1). About eight papers were published on KC between 2011 and 2013, including three major studies by the groups of 'Caporossi' and 'Vinciguerra' that looked at the effectiveness and the safety of the CXL method. They reported good results for the first 2 years. Professor Hafezi also commented on a study conducted by his team: It involved fewer eyes (62), but it extended over 3 years. His study also looked at how many patients aged 8 to 19 years that came in for the first time indeed showed progression as defined by one Diopter increase of K_{max} over 12 months. The result was a shocking 88%, meaning that 9 out of 10 of them would progress according to this definition. This is why he adopted a different approach whereby he now cross-links every child that is diagnosed with KC. He said that he believes that every patient younger than 20 years of age who is diagnosed as having KC should be treated without waiting for documentation of progression.

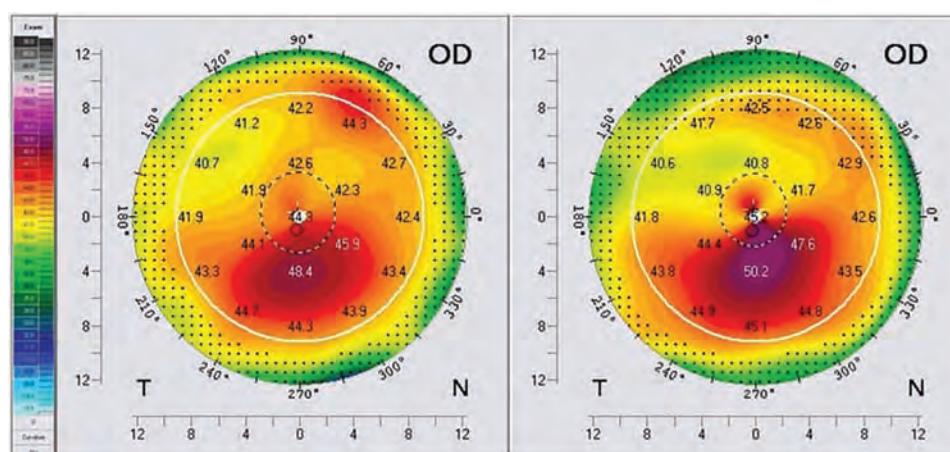


Fig. 1: Two images of a 15-year-old patient taken 3 months apart (left panel) May, 2009, (right panel) August, 2009

PRESENTATION 2

Should We Do Corneal Collagen Cross-linking (CXL) in any Patient with Keratoconus (KC) without Documentation of Progression?

Renato Ambrósio Jr, MD, PhD

Instituto de Olhos Renato Ambrósio, Rio de Janeiro, Brazil

About two decades ago, the treatment of keratoconus (KC) and other ectatic corneal diseases was relatively 'easy and straight forward' due to the low number of options. Once the diagnosis was confirmed, visual rehabilitation

was attempted by glasses and/or by rigid gas permeable contact lenses. When these treatments fail, penetrating keratoplasty became necessary as the only and final solution.

In the late 1990's, collagen CXL procedures were described by Professor Theo Seiler's group in Dresden,¹ opening new horizons for managing such diseases. Crosss-linking was demonstrated to be very effective measure to halt ectasia progression.^{2,3} Interestingly, other refractive surgery procedures, such as intrastromal rings segments (ICRS), phakic intraocular lenses (pIOLs), conductive keratoplasty and custom topography-guided photorefractive keratectomy (PRK), have been also described as alternative surgical treatments prior to keratoplasty.⁴

However, the advent of these options have also implicated new challenges and paradoxes for the clinician.⁵ When, why and how to operate a patient with KC involve clinical dilemmas, opening the room for extensive debates which require appropriate prospective studies.

The first main concept is that the main goal for keratoconus surgery is therapeutic, aiming for improving corrected vision, typically measured as corrected distance visual acuity (CDVA).⁶ While we should always consider the safest and most efficient approach for our patients, refractive results should be secondary for these cases.

Second, CXL should be ideally performed in an early phase of the disease. In fact, the study by Koller, Mrochen and Seiler on failures and complications of the original Dresden CXL protocol⁷ found that failure rate of CXL, defined as continued ectasia progression on corneal tomography, is significantly reduced if the preoperative K_{max} (maximal axial keratometric value on the front corneal surface) is less than 58D. However, we still need to consider its pros and cons for every individual case since the same study found that preoperative CDVA better than 20/25 was a significant risk factor for losing more than one lines of corrected vision.⁷

Diagnostic technologies for detecting ectatic disease at the earliest stage have dramatically improved.^{8,9} Still, the clinician should understand that when screening refractive candidates for ectasia risk, we aim to detect individual's susceptibility or predisposition for biomechanical failure and ectasia progression.^{10,11} There is still some debate as to what is 'forme fruste' keratoconus (FFKC), and also some confusion between FFKC and a pattern of mild inferior steepening, classified on topography as suspicious (Fig. 1).¹² Anyway, these are not the same as disease, so that these cases that are found at high risk for ectasia do not necessarily have KC and/or need CXL.

Progression of KC is more common in the first three decades of life. In fact, up to 88% of children and adolescent patients may have progression of ectasia as reported by Chatzis and Hafezi, who also reported excellent results after CXL in this population.¹³ While we do commend the colleagues for this interesting and well documented study, the proposal that CXL in children and adolescents should be performed as soon as the diagnosis has been made needs to be reconsidered. I agree we do not need a subtraction topographic map demonstrating ectasia progression for indicating CXL. But CXL is not an innocuous procedure with zero complications,⁷ so that generalizing such indication may lead to a large number of patients to a unnecessary harm. Correa et al reported in this issue of the IJKECD¹⁴ a typical patient we see at the daily keratoconus referral practice. A 17-year-old male with asymmetric keratoconus had stabilization of the ectatic process without CXL. ICRS may provide more benefit to the patient with moderate disease. Rigorous follow-up along with treatment for allergy, along with patient education with advice not to rub the eyes are mandatory in such cases.

Regardless of age, I strongly believe it would be a mistake to generalize the indications of CXL for each and every patient with KC or other corneal ectatic disease. One could already argue that there is already some abuse with over-indication of CXL. Indeed, I have seen many cases of CXL indicated and performed on patients whose preoperative data did not corroborate the diagnosis of ectasia. CXL works for true KC and it is also true that its introduction determined a factual revolution in the management of such diseases.¹⁵ However, the power of prevention should not give everyone a green light to perform the procedure in every case of mild KC.

In conclusion, we should consider every patient individually. Any medical treatment, clinical or surgical, should be indicated based on the judgment of the risks and benefits involved. We should do medicine first and foremost, considering the best for the patient in either private and public practices. The Oath of Hippocrates-Primum non nocere-in this context, should be always considered.

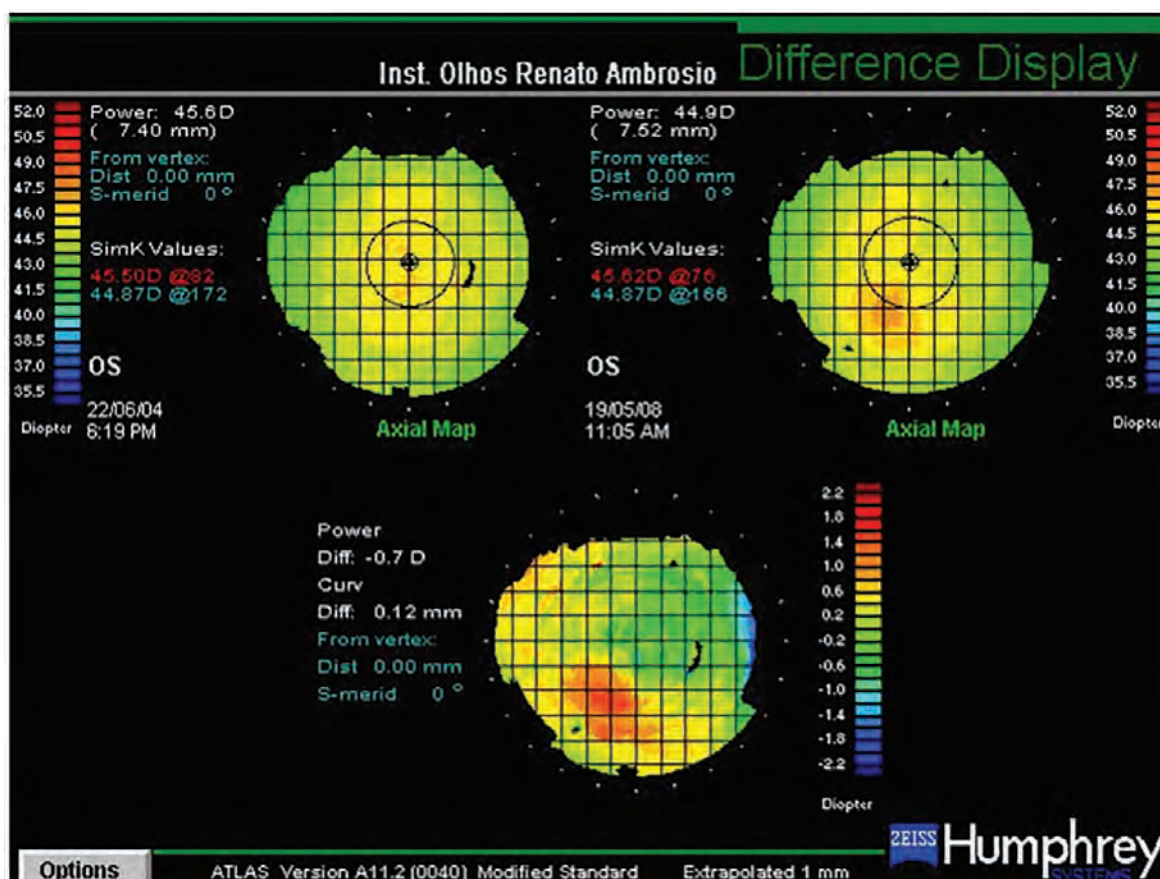

Fig. 1: An example of forme fruste KC with natural evolution of ectasia

REFERENCES

1. Spoerl E, Seiler T. Techniques for stiffening the cornea. *J Refract Surg* 1999;15:711-713.
2. Wollensak G, Spoerl E, Seiler T. Riboflavin/ultraviolet-a-induced collagen cross-linking for the treatment of keratoconus. *Am J Ophthalmol* 2003;135:620-627.
3. Caporossi A, Mazzotta C, Baiocchi S, Caporossi T. Long-term results of riboflavin ultraviolet a corneal collagen cross-linking for keratoconus in Italy: the Siena eye cross study. *Am J Ophthalmol* 2010;149:585-593.
4. Faria-Correia F, Luz A, Ambrósio R Jr. Managing corneal ectasia prior to keratoplasty. *Expert Review of Ophthalmology* 2015;10:33-48.
5. Seiler T. The paradigm change in keratoconus therapy. *Ind J Ophthalmol* 2013;61:381.
6. Ambrósio R Jr. Cirurgia refrativa terapêutica: por que diferenciá-la? *Revista Brasileira de Oftalmologia* 2013;72:85-86.
7. Koller T, Mrochen M, Seiler T. Complication and failure rates after corneal cross-linking. *J Cataract Refract Surg* 2009;35:1358-1362.
8. Belin MW, Villavicencio OF, Ambrosio RR Jr. Tomographic parameters for the detection of keratoconus: suggestions for screening and treatment parameters. *Eye Contact Lens* 2014;40:326-330.
9. Belin MW, Ambrosio R. Scheimpflug imaging for keratoconus and ectatic disease. *Ind J Ophthalmol* 2013;61:401-406.
10. Ambrosio R Jr, Randleman JB. Screening for ectasia risk: what are we screening for and how should we screen for it? *J Refract Surg* 2013;29:230-232.
11. Ambrosio R Jr, Dawson DG, Salomao M, Guerra FP, Caiado AL, Belin MW. Corneal ectasia after LASIK despite low preoperative risk: tomographic and biomechanical findings in the unoperated, stable, fellow eye. *J Refract Surg* 2010;26:906-911.
12. Saad A, Gatineau D. Topographic and tomographic properties of forme fruste keratoconus corneas. *Invest Ophthalmol and Visual Sci* 2010;51:5546-5555.
13. Chatzis N, Hafezi F. Progression of keratoconus and efficacy of pediatric corrected) corneal collagen cross-linking in children and adolescents. *J Refract Surg* 2012;28:753-758.
14. Corrêa RO, Canedo ALC, Beildeck R, Salomão MQ, Politis PB, Dawson D, Ambrósio R Jr. Long-term stability of ectasia in a young patient with asymmetric keratoconus. *Int J Ker Ectac Cor Dis* 2015.
15. da Paz AC, Bersanetti PA, Salomao MQ, Ambrosio R Jr, Schor P. Theoretical basis, laboratory evidence, and clinical research of chemical surgery of the cornea: cross-linking. *J Ophthalmol* 2014;2014:890823.

PRESENTATION 3

When to Perform Collagen Corneal Cross-linking?

Osama Ibrahim MD, PhD

Professor, Department of Ophthalmology, Alexandria University, Egypt

Professor Ibrahim stated that he has performed corneal cross-linking (CXL) in more than 10,000 eyes. In the beginning, he used to wait until he had proof of progression before carrying out CXL, and unfortunately lost around 10 eyes of patients that had progressed while being 'lost to follow-up'. Today, the concept followed in his practice is that a patient will be treated with CXL once he/she is diagnosed as having a 'true' keratoconus (KC), i.e. not a forme frusta or suspicious KC or a thin cornea, but a true one that meets all the criteria agreed upon in past meetings, even if the patient is younger than 20 years of age. He noted that the only patients that had to be retreated were below 20 years of age. Age alone is not the real problem — there are other issues that need to be addressed in this population, among them mental problems (e.g. Down syndrome), allergies that cause severe eye rubbing, etc. Professor Ibrahim mentioned that if he sees a patient with predisposing risk factors, he will explain to the family and the patient that the condition needs to be treated together with a close follow-up.

The main message of his talk was that the follow-up intervals for younger patients must be no longer than 3 months. If those patients are lost to follow-up after 1 year, it may be too late. The philosophy practiced by him is to first concentrate on the diagnosis: if it is true KC, then treat the patient immediately, monitor him/her closely, and strongly advise against eye rubbing and other risky behaviors. Waiting is an option when he sees a slight steepening in K_{\max} (less than half a Diopter) or a slight increase in elevation (a few microns) in adults. It is never an option in children, if he finds the slightest difference in K_{\max} or in corneal elevation.

PRESENTATION 4

How to Measure/Document Progression of Ectatic Disease?

Michael W Belin

Professor, Department of Ophthalmology and Vision Science, University of Arizona Health Sciences, Tucson, Arizona

In his interesting lecture, Dr Belin discussed the problems facing clinicians today with regard to measuring or documenting keratoconus (KC) progression. Dr Belin stated that it is fairly easy to use maximum keratometry (K_{\max}) to document progression in advanced disease, where there is significant alteration in vision, corneal thickness or keratometry. However, K_{\max} is an unreliable parameter to differentiate normal corneas from cones. The difficulty lies in the setting of early or subclinical disease and in documenting change prior to visual loss, in which case K_{\max} is a very poor parameter to diagnose and monitor disease progression. Progression measures may include anterior surface (curvature and elevation), epithelial thickness, best spectacle visual acuity (BSCVA), corneal thickness, and posterior surface (curvature and elevation). The problem is that each of them has its own limitations: (1) The anterior surface can be altered by contact lenses and curvature can change with axis, so the curvature can change and even the shape maybe be altered after treatment, (2) Epithelial surface measurement is not commercially available for screening, and progression of epithelial surface changes over time have not been well documented, (3) Visual acuity is very variable: for example, it varies with lighting, and we know that there are some patients with advanced KC who nevertheless have good visual acuity through some axes, (4) Single point measurements of corneal thickness may not be suitable, although a full map has the potential to document progression in early disease, and (5) Posterior surface measurement is least affected by outside forces, and it has the potential to document disease progression, but single point measurements are probably too 'noisy' to determine early changes. Taken together, there is no easy way to measure KC progression. There had been some discussion last year at the convention about using the index of height decentration (IHD) as an option, but, as can be seen in the example in Figure 1, a patient with fairly advanced KC can still have a normal IHD.



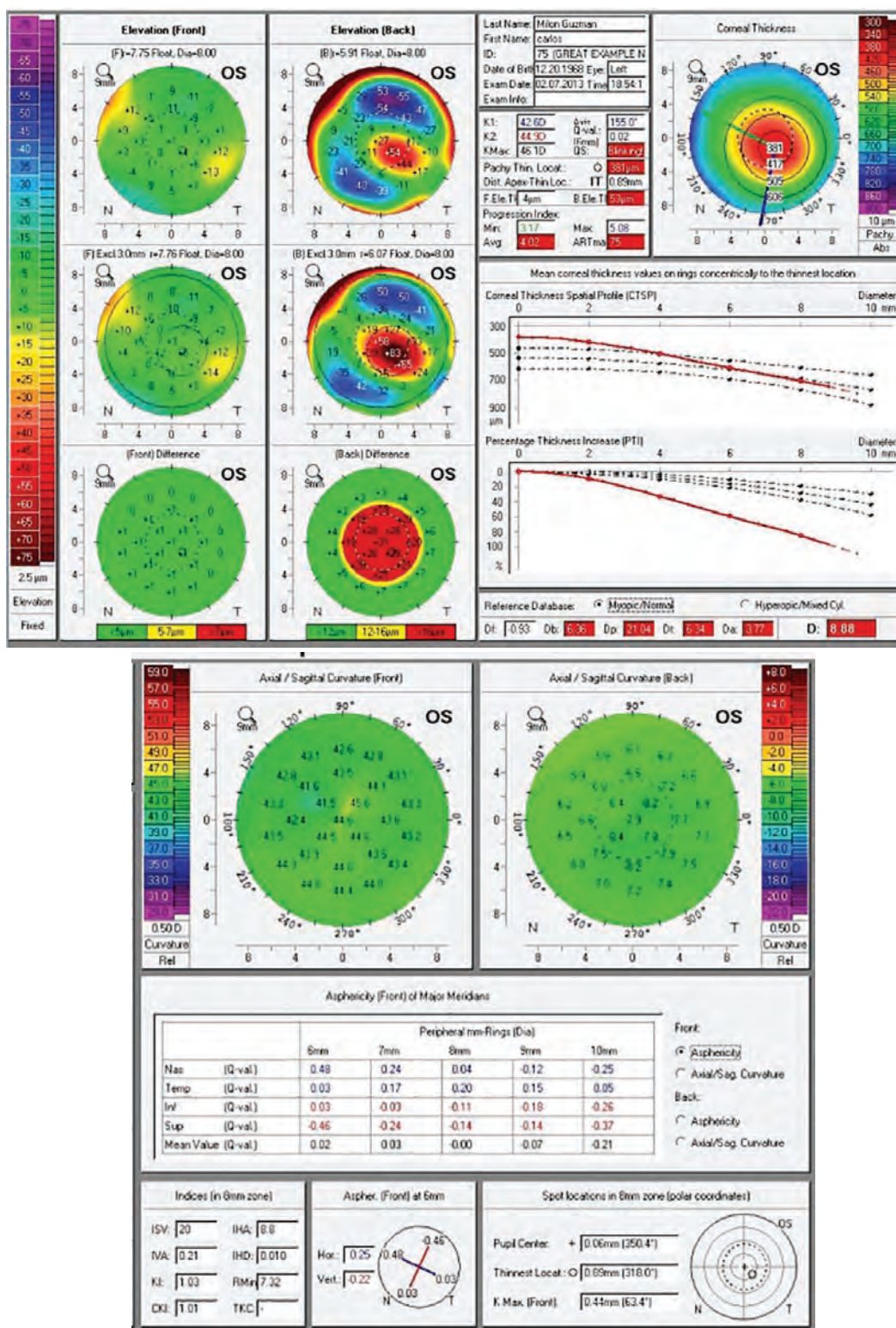


Fig. 1: An example of a patient with advanced cone and a normal index of height decentration (IHD)

Progression measures of the posterior surface elevation are often difficult to interpret as some areas may show a positive change (greater elevation) while other areas may show the opposite (Fig. 2). Possibly comparing the central best fit sphere BFS) may be a more reliable indicator of progression. Corneal thickness is a reasonable variable to look at (Fig. 3) but occasionally may show similar conflicting changes. Dr Belin mentioned that he measures progression by checking the anterior corneal surface, the posterior corneal surface and corneal thickness and looks for changes in two of those three parameters, although he notes that there is no consensus as to how to document subtle changes and how to determine real change from noise.

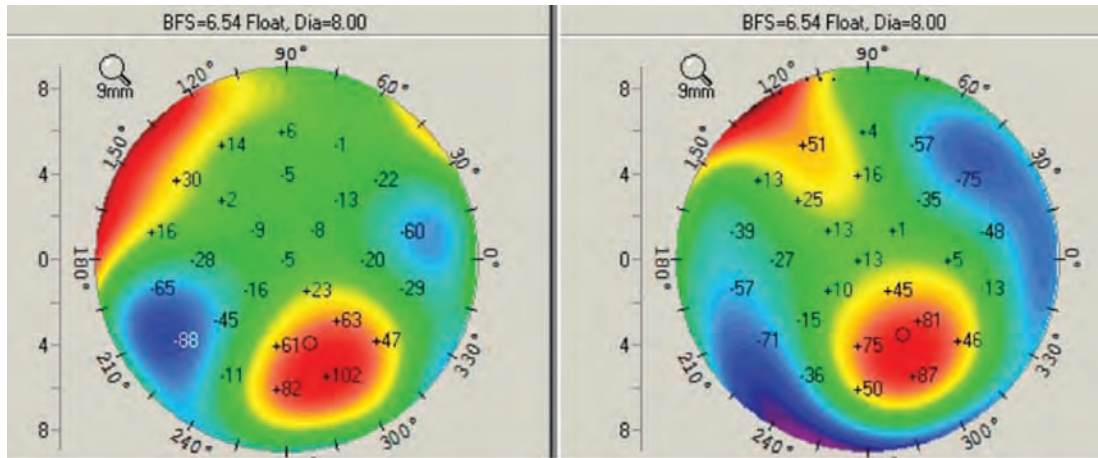


Fig. 2: Posterior surface measurement. Two examinations separated in time showing conflicting areas of change, with greater elevation inferiorly on the left map and great elevation superior on the right

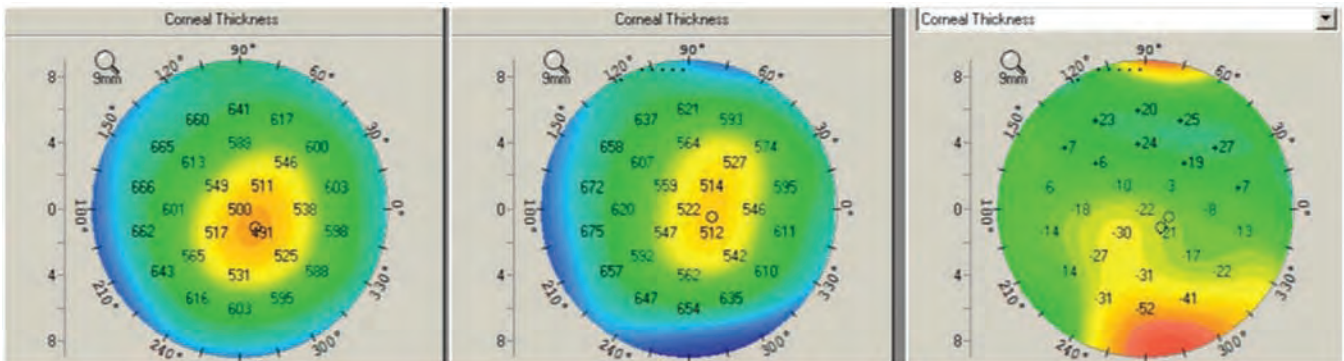


Fig. 3: Corneal thickness measurement (two map difference display). The map on the left represents the more current examination. The difference map on the right shows the regional changes in corneal thickness

PRESENTATION 5

What Parameters I use to Evaluate Diagnosis and Progression of Keratoconus (KC)?

A John Kanellopoulos

Director, Laservision.gr Institute, Athens, Greece; Clinical Professor, NYU Medical School, New York, USA

Continuing Dr Belin’s discussion on diagnosing and evaluating the progression of KC, Dr Kanellopoulos stated that in his long experience corneal curvature asymmetry appears to be the most sensitive marker of ectasia and ectasia progression.

The only rare instance in which asymmetry cornea indices do not work is when the cone is of a nipple type. Index of height decentration (IHD) measures the asymmetry of the anterior cornea curvature and appears to be the most sensitive marker, with one exception, that of a central cone, which is hard to ‘catch’ with IHD alone. On the other hand, index of surface variance (ISV) measures the highest to lowest difference, so it is very useful and perhaps more valuable for the rare central cones. These two parameters in combination are very useful. Pachymetric asymmetry and epithelial profiles are very valuable, and most optical coherence topographies (OCTs) will have them.

The problem that needs to be answered today for the evaluation of progression is if there is a change in corneal thickness and ectasia that results in curvature change or if there is a curvature change (anterior or posterior) that results in a thickness change. Until we know the answer to this question, we will not know where to evaluate progression first. Another question that needs answering is whether corneas with ‘weaker’ biomechanics are at risk for ectasia or if there is a ‘breaking’ point in biomechanics that is different for destabilizing each cornea (for example, LASIK procedures done on weak corneas that did not go into ectasia).

As part of his presentation, Dr Kanellopoulos presented a recently published study involving 800 eyes, in which it was concluded that IHD and ISV were the most sensitive markers for KC progression and early diagnosis. In that study, the index of height decentration and the index of surface variance had the strongest correlations with topographic keratoconus grading (P, 0.001). In contrast, corrected distance visual acuity (CDVA) and keratometry correlated poorly with keratoconus severity.

Dr Kanellopoulos also discussed his study on epithelium and the discovery that epithelium in old people is extremely homogenous. He noted that the differences between a 15-year-old cornea and a 75-year-old cornea are within 1 micron of magnitude. There is no biometric measure in the human body that is so homogenous, with the possible exception of body temperature. He used the variables central, superior, inferior, minimum and maximum, that can be measured with an OCT (Fig. 1). Past studies have showed that these variables correlate with cone, ectasia and ectatic corneas.

Referring to another study, Dr Kanellopoulos created asymmetry indices with corneal pachymetry using OCT and epithelial pachymetry (Fig. 2). He believes that these indices are far more sensitive and specific in OCT since they are not biased by dryness or epithelial opacities.

In concluding his presentation, Dr Kanellopoulos emphasized that topometric asymmetry indices are very useful and comprise the most sensitive tool that we have (IHD and ISV), although they have the one pitfall with regard to central cones which can be missed. Finally, he noted that ART max is very valuable for screening for LASIK procedures in the clinical setting a parameter available on most pentacams.

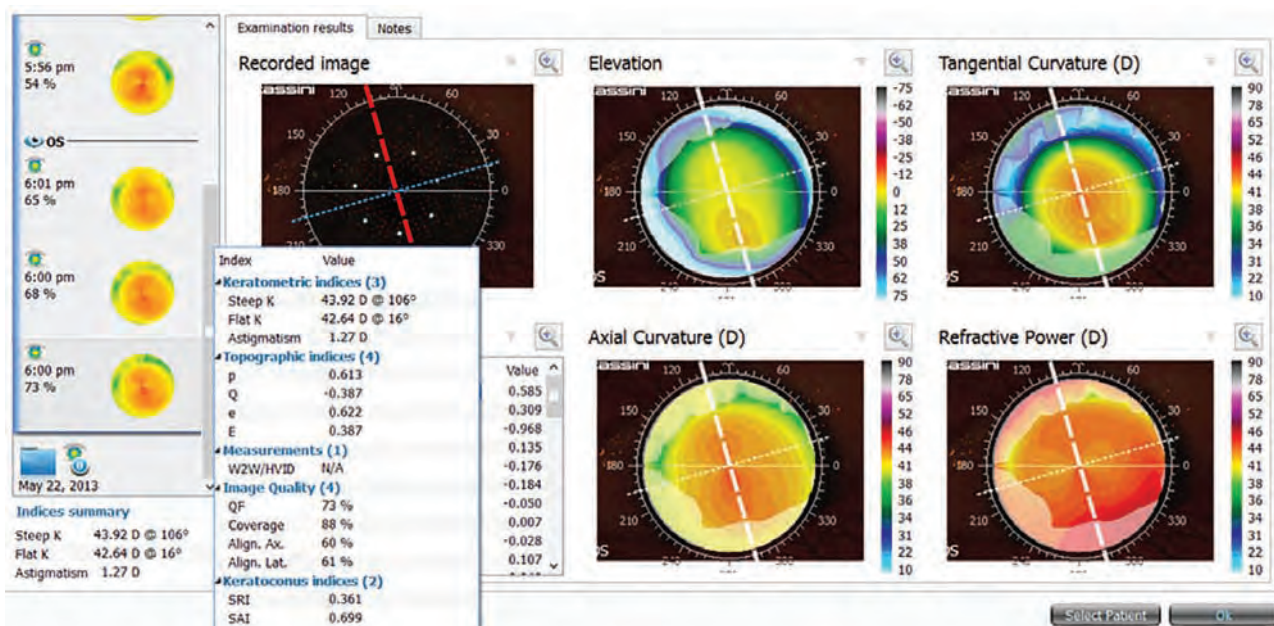


Fig. 1: Keratometry in D, shape factors and keratoconic indices

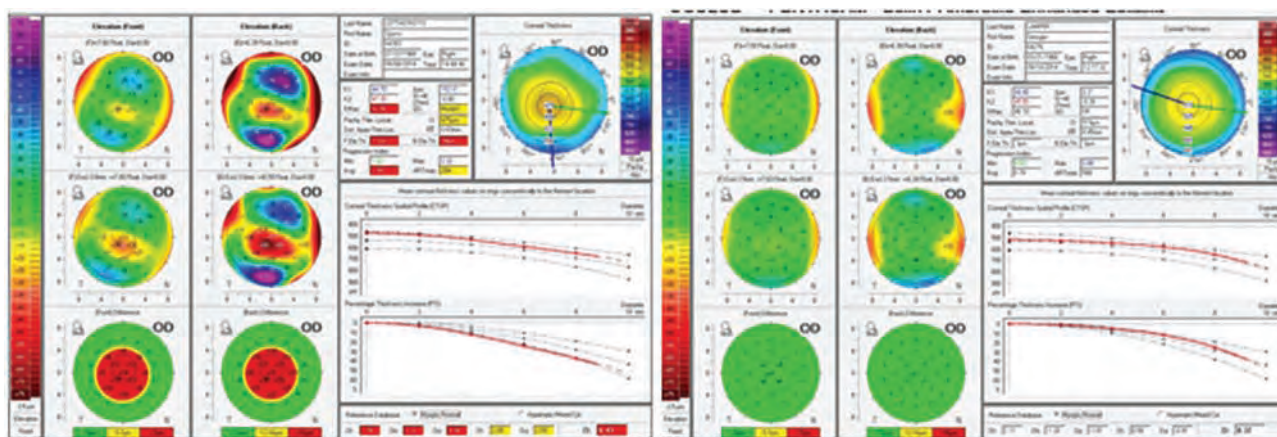


Fig. 2: Pachymetric maps of a normal cornea and a KC cornea

PRESENTATION 6

Best Spectacle Corrected Visual Acuity (BSCVA) as the Best Method to Classify and Grade Keratoconus (KC)

Jorge L Alió

VISSUM Corporation Alicante, Spain; Universidad Miguel Hernández Alicante, Spain

Dr Alio started his presentation by saying that for him and his team, visual acuity (VA) is the best method to classify and grade KC. He said that the questions we should be asking are, first, do we really understand what is KC and second, how can we use modern therapeutic approaches for the correction of KC (e.g. contact lenses, intrastromal corneal ring segments (ICRS) and others) more successfully and with better predictability.

Patients present because of disease progression, from grade 1 to 5 or according to the grading system that you may be using. There has been a deterioration of vision no matter in which stage you may define the condition to be (Fig. 1). 'Real' KC is present when it is detectable by the patient, and it is defined by the patient's having begun or is steadily losing vision.

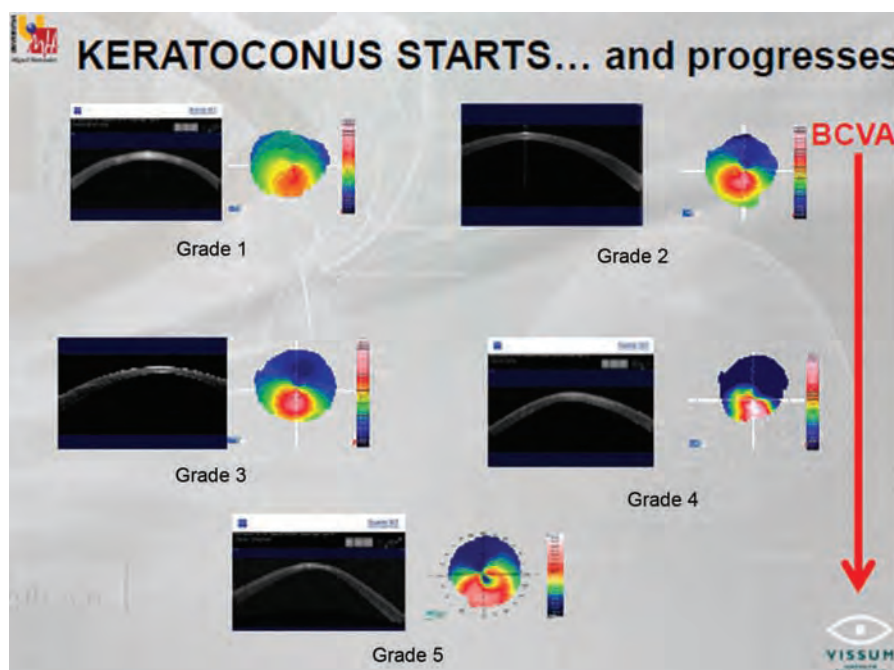


Fig. 1

Dr Alio said that what matters to the patients is vision—they do not care about keratometries (K) values or about pachymetry, and they neither know nor care about mechanical data. They are concerned because they are losing vision, and, of course, are experiencing a poorer quality of life as related to vision. Our procedures are only as good as their ability to address the issue of how to improve these patients' vision.

Dr Alió mentioned some KC classifications (Amsler 1990, Amsler-Krumeich 1991, Alió-Shabayek 2006) and said that none of them is complete enough to fully incorporate all the actual knowledge about its clinical manifestations. They also do not consider the different technologies that we now have to study KC, and, above all, none is based on the severity of the visual impact of the corneal disease.

He said that if you go to the nephrologists, or any other specialty, most, if not all, of the diseases they treat are graded according to deterioration of function. This is exactly what he proposed to do for KC. Toward this end, Dr Alió et al developed the national library KC database some years ago, and it is the official KC data base in Spain.

Many centers contribute to this database from the initial 507 patients (776 eyes), it currently has reached 1700 cases and continues to grow (Fig. 2).




Fig. 2: Database of keratoconus in Spain

Dr Alió’s team is attempting to identify the variables involved in the visual loss caused by KC, specifically, to determine which of the incoming data from the various sources are related to the visual loss caused by the KC. They also study other parameters that are related to the improvement of vision based on treatment of the cornea. All these patients undergo extensive clinical examinations in order to include everything that is currently considered of value for diagnosis as well as for categorizing the various characteristics of KC as a disease entity (Fig. 3).

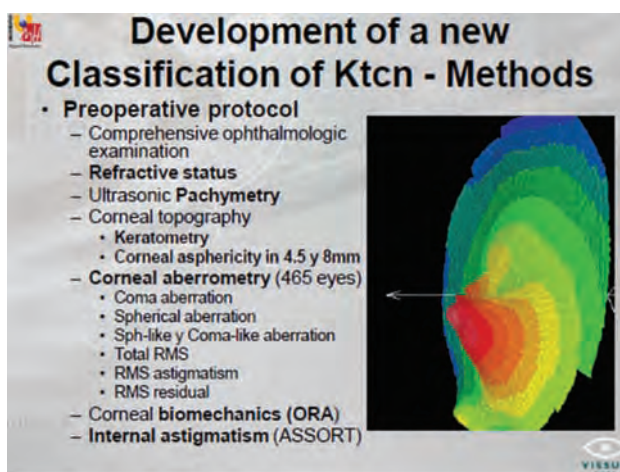


Fig. 3: Methods used for the development of a new classification system of keratoconus

Dr Alió and his colleagues created a system of classification of KC based on the variables that they found to be significantly related to the patient’s visual condition: the mean K, the internal astigmatism, the root mean square (RMS) of the coma-like aberrations, and the Q value at 8 mm (Fig. 4).

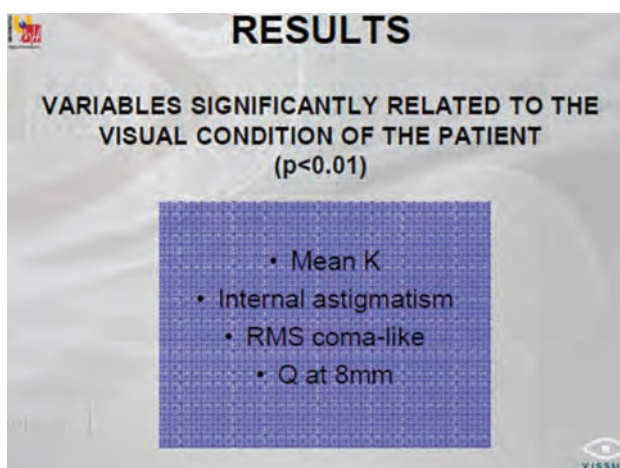


Fig. 4

GRADE	TOPO	CDVA	K	Internal Astigmatism (diopters)	RMS Coma-Like (μ)	Q 8mm
GRADE I		> 0.9	< 46.5 D	< 2.50	< 2.50 μ	< -0.35
GRADE II		0.9 and 0.6	46.5 and 49 D	2.50 and 3.70	2.50 and 3.50 μ	-0.35 and -0.75
GRADE III		0.6 and 0.4	49 and 53 D	3.50 and 4.50	3.50 and 4.50 μ	-0.75 and -1.10
GRADE IV		0.4 and 0.2	53 and 57 D	4.50 and 5.50	4.50 and 5.50 μ	-1.10 and -1.50
GRADE IV-PLUS		< 0.2	> 57 D	> 5.50	> 5.50 μ	> -1.50

Fig. 5: Classification of keratoconus

The Alió classification: Grade 1 = corrected visual acuity with spectacles better than 0.9, grade 2 = between 0.9 and 0.6, grade 3 = between 0.6 and 0.4, grade 4 = between 0.4 and 0.2, and grade 4 plus = cases which have corneal scarring or evidence of an anatomical imbalance, as well as anatomical features typical of keratoconus with less than 0.2 corrected distance visual acuity (CDVA). There is a progressive increase in the K-values, in internal astigmatism, in RMS and in the Q values with increasing grade (Fig. 5).

Dr Alió contends that these classifications could serve as a better approach to delineate a given case of KC because they were based on: (1) a large number of patients with different degrees of KC, (2) correlations that exist between clinical and practical variables pertaining to the patient's visual function, (3) relevant parameters, such as the analysis of the posterior surface of the cornea (that has been proposed as an incipient marker of the disease), (4) relevant variables, such as corneal aberrations that are used in order to determine the degree of asymmetry from the corneal surface and the optical quality of the eye, and finally (5) analysis of corneal asphericity through 8 mm that allows estimation of the geometry of the cornea throughout a broad area and not only in the central 3 mm.

Dr Alió concluded by saying that this classification will allow us to provide a better therapeutic approach, because it takes into account the degree of visual impairment of each individual patient.

PRESENTATION 7

When Implanting Intrastromal Corneal Ring Segments (ICRSs) Do We Still Need to Perform Corneal Collagen Cross-linking (CXL) with Riboflavin and Ultraviolet-A (UVA) (UV-CXL)?

Efekan Coşkunseven, MD

Director, Department of the Refractive Surgery, Dünyagöz Medical Center, Istanbul, Turkey

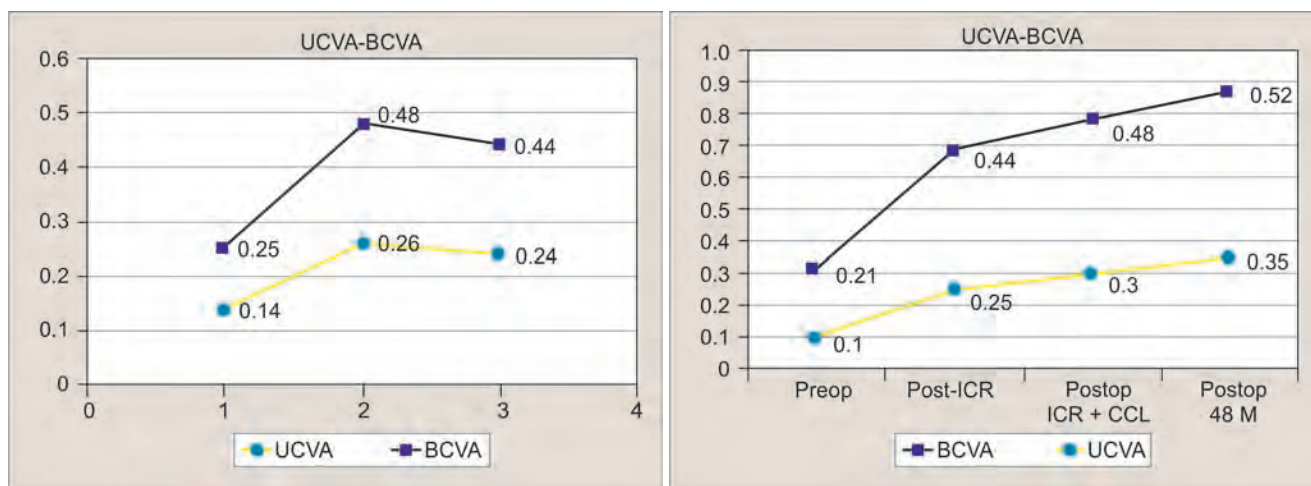
Dr Coşkunseven started his talk by saying he does not believe that intrastromal corneal ring (ICR) implantation can stop keratoconus (KC) progression. He presented his latest study which compared ICR implantation alone and ICR implantation following corneal collagen cross-linking (CXL). Group I included 36 eyes that underwent ICR implantation alone, and group II included 21 eyes that first underwent CXL and then ICR implantation. Both groups were followed-up for a period of 6 to 48 months. The inclusion criteria were grade I-II-III KC, age 30 to 35 years, contact lens intolerance and corneal thickness of at least 400 microns (μ m) at the thinnest point and at least 450 μ m at the incision point. The exclusion criteria were keratometry readings ≥ 65 D, severe atopy, corneal dystrophies, hydrops, corneal opacities, herpetic keratitis, grade IV keratoconus, best corrected visual acuity 0.05 or less, collagen, vascular, autoimmune diseases and other systemic diseases. CXL was performed on patients with highly irregular corneas, very thin corneal thickness (400-425 μ m) and those who were very difficult to follow-up. Both groups used a Keraring 5 mm optical zone segment.

Dr Coskunseven presented the results of his study: group I exhibited very little change in uncorrected visual acuity and best corrected visual acuity (UCVA-BCVA), while group II exhibited increasing improvement over time in UCVA-BCVA (Graph 1). Group I showed an increase in cylinder and spherical equivalent (SEQ) at 48 months of follow-up, while group II showed a decrease in those parameters (Graph 2). The K2 parameter also underwent the same decrease in group II at 48 months, while there was an increase in K2 from months 6 to 48 in group I (Graph 3). The mean K decreased by 2.97D in group I and by 4.06D in group II.

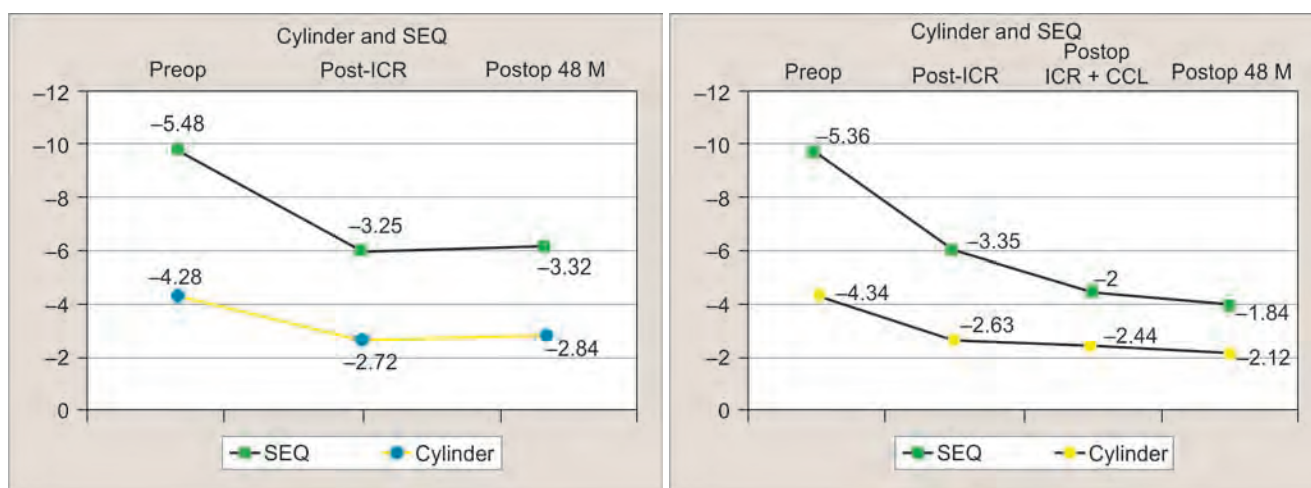
Dr Coskunseven stated that the age of the patients selected was so because they did not want any progression. He proposed that biomechanical changes might explain the reduction in efficiency in the ICR group. Nevertheless, UCVA and BCVA in group I had still not changed between 6 and 48 months in 14 eyes, the SEQ was unchanged in 6 eyes and the CYL was unchanged in 8 eyes. Moreover, K2 did not change in 12 eyes and the mean K did not change in 11 eyes in group I.

Dr Coskunseven concluded that ICR implantation is an effective method for the improvement of UCVA and BCVA in KC. However, the inhibiting effect of ICR in KC progression is still unclear. CXL with riboflavin and UV light seems to be a safe procedure for halting the progression of KC. Finally, the addition of corneal crosslinking with riboflavin and UV light (UV-X) to Keraring implantation yields greater improvement in keratoconus than Keraring implantation alone.

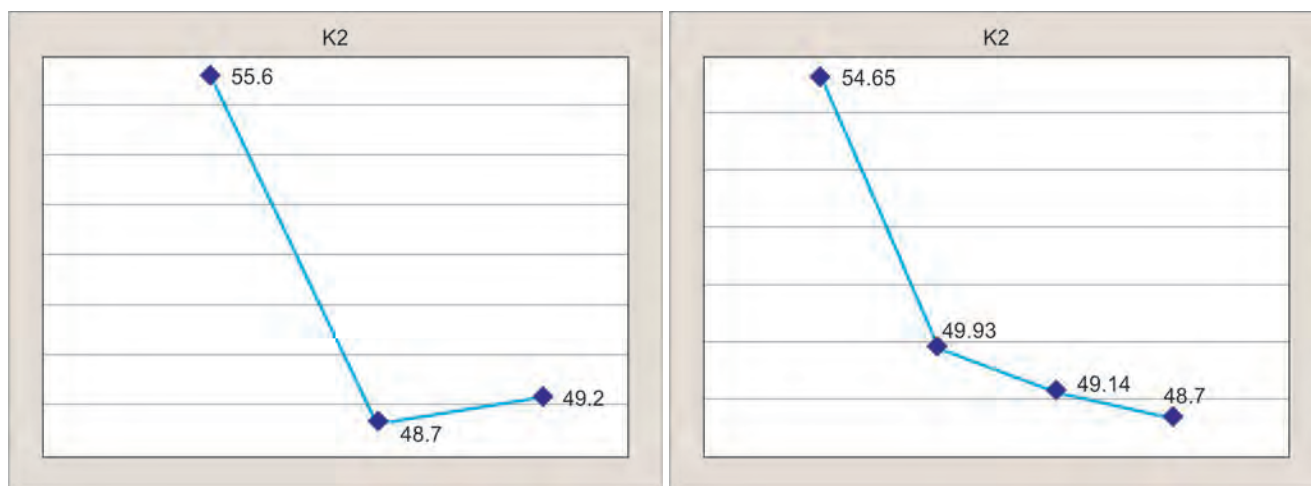
At the end of his talk, Dr Coskunseven stated that he can not definitively say that we need to perform CXL prior to ICR implantation, but the results did show a reduction in efficiency in group I while the effect was maintained over the study period in group II.



Graph 1: Change in UCVA-BCVA in the ICR group vs the ICR + CXL group



Graph 2: Change in cylinder and SEQ in the ICR group vs the ICR + CXL group



Graph 3: Change in K2 in the ICR group vs the ICR + CXL group

PRESENTATION 8

When Implanting Intrastromal Corneal Ring Segments (ICRSs), Do You Still Need to Perform Corneal Collagen Cross-linking (CXL) with Riboflavin and Ultraviolet-A (UVA) (UV-CXL)?

Michael Assouline

AIHP, ACCA, Funder and Director of Médical Center Ophthalmologique Iéna Vision, Paris, France

Dr Assouline began his presentation by showing the results of his study on 56 patients who underwent ICRS without CXL, and were followed for 4 years. There was no disease progression among the vast majority of patients that did not have post-Lasik ectasia.

He mentioned that he does not perform systematic CXL procedures (except for patients under 16 years of age), but rather waits and follows his patients periodically to obtain proof of significant change in corneal shape before deciding to do cross-linking. He said that he sees about 20 to 30 keratoconus patients per week, including follow-up patients, and does fewer than 15-20 CXL procedures per year. Despite those low numbers of CXL procedures, he does not perform more keratoplasties, and his patients have not yet abandoned him!

He believes that many nonspecialized eye doctors only entered the field of keratoconus treatment when seemingly 'easy to perform' methods became available and economically attractive. He thinks that cross-linking is now applied by many to most if not all keratoconus patients without really assessing the risk/benefit ratio for each individual. The procedure is technically very easy to perform and it does not require much expertise. However, the long-term efficacy has not been proven for keratoconus patients which have no or slow progression, and was not effectively compared to that of other approaches (such as prevention of eye rubbing, or intrastromal segments). Short-term complications of CXL include wound healing delay, corneal infection and scarring that may affect visual performance in more than 1% of cases. In addition, long-term side effects of CXL are largely unknown at this time, and may for instance include lens, vitreous and retinal damage from phototoxicity.

Before carrying out a CXL procedure, Dr Assouline studies the candidate eyes very carefully. He works with two types of corneal topography, Orbscan and Pentacam, as well as anterior OCT (Visante Zeiss). The patients carry out differential maps every 6 months on a regular basis, and undergo optical coherence tomography as well. Their vision is assessed, and their aberrations are measured at the same time.

Because of this experience Dr Assouline suggests that ICRS should be the first line of treatment in KC because it may address both goals of improving vision and limiting disease progression, with virtually no risk for the patient. Once ICRS are in place, few patients will experience progression of KC, and this may limit or delay the need for CXL.

He concluded by saying that such a comprehensive follow-up protocol provides enough data to help keep updated on the patients' status, and that we should not feel compelled to do CXL if no significant progression of KC can be proven.

PRESENTATION 9

Ferrara-type Intracorneal Ring Segments (ICRSs) and Progression of Keratoconus (KC)

¹José F Alfonso, ²Carlos Lisa, ³Luis Fernández-Vega Cueto, ⁴Jesús Merayo

¹⁻⁴Department of Corneal, Lens and Refractive Surgery, Instituto Oftalmológico Fernández-Vega Fundación de Investigación Oftalmológica Universidad de Oviedo, Spain

Dr Alfonso presented his group's idea about the influence of the Ferrara-type segment on the progression of KC. He explained two types of classifications: the classic classification, which is 'progression-based treatment' that proposes treatment by corneal collagen cross-linking (CXL) or segments if the ectasia is progressive, and the 'morphological' classification that Ferrara established for use at any stage. He later demonstrated a customized treatment with segments ('diagnosis based treatment') (Fig. 1).



Fig. 1: The de Ferrara 'morphological' classification for diagnosis-based treatment

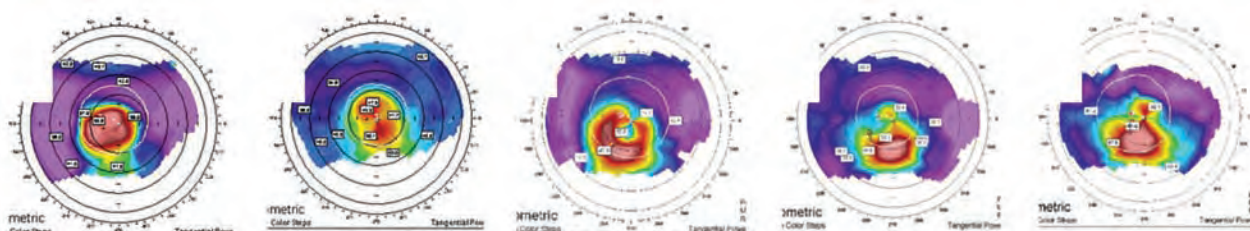


Fig. 2: Keratoconus phenotypes: nipple, bow tie, croissant, duck and snowman

Following Ferrara's diagnostic guidelines, his team classified the KC into 5 main phenotypes, 2 central and 3 paracentral types, based on the location of the thinnest point, asphericity and the relationship between refractive, topographic and coma axes (Fig. 2).

Following their extensive experience in diagnosing and treating according to this classification, they published two papers related to the KC phenotypes and Ferrara segments.

Based on the last meeting of the KC expert forum in Amsterdam, and on the papers that were published since then, Dr Alfonso stated that there are 3 parameters that are related to KC progression: pachymetry, steepest keratometry and visual acuity. He and his group analyzed these parameters in a retrospective study of 173 eyes with a minimum of 5 years of follow-up. The pachymetry was evaluated with optical coherence tomography (OCT) Visante at the optic zones of 0 to 2 mm and 2 to 5 mm. They discovered that the thinnest value remained stable at both optic zones in central KC throughout the first 5 years after surgery. This finding was the same for paracentral KC. The steepest keratometry was assessed by Placido's topography and the Scheimpflug camera. Again, at 5 years, there were no relevant changes in the keratometric findings for both types of KC. The uncorrected visual acuity at the 5th postoperative year was better than it was before the surgery, but it was slightly worse than the values obtained at the 1st postoperative year for both types of KC.

He also presented another parameter for evaluating the efficiency of segments in stopping the progression of KC, and the need for new surgeries based on this classification. To assess these topics, they studied a group of at-risk patients younger than 20 years that were treated with segments. They identified 111 eyes that fulfilled these criteria in their database of 1,300 KC cases (9% of the total sample). Only 5 (4.5%) eyes needed a reoperation due to KC progression. Dr Alfonso found it interesting that those 5 eyes corresponded to 2 specific phenotypes, bow tie and snowman. They had been treated incorrectly, with 2 symmetrical segments at the horizontal meridian, a treatment that favors a pattern of inferior progression in younger patients (Fig. 3). Those patients should have been treated with a single inferior segment.

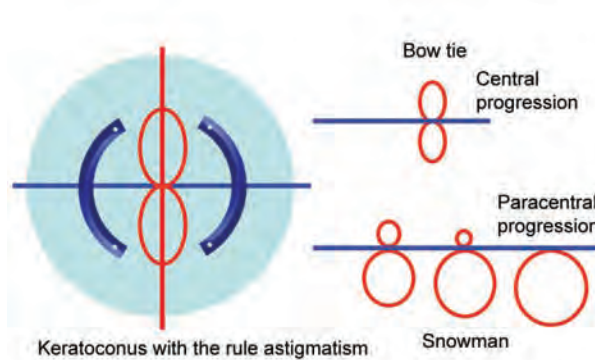


Fig. 3: Illustration of the treatment that favors progression in an inferior direction

Dr Alfonso concluded that the KC treated with Ferrara-type segments can be considered stable at 5 years of follow-up, subject to the previously mentioned treatment parameters. Patients younger than 20 years, who have the snowman or bow-tie phenotypes and who are treated with symmetrical segments at the horizontal meridian have a greater risk of progression, thus emphasizing the need to classify KC into phenotypes in order to identify the high-risk cases. Preoperative location of the cone, asphericity and relation between coma, refractive and topographic axis are important for optical properties of keratoconus and also for visual and refractive outcomes after intracorneal ring segments implantation.

PRESENTATION 10

How Long to Wait for Visual Rehabilitation after Corneal Cross-linking (CXL)?

Farhad Hafezi

Lecturer and Professor, Hafezi Proposed Answers to the Interesting Question of How Long to Wait after CXL before Initiating Visual Rehabilitation

On one hand, he showed a case presenting atypical regression of 2.5 D at 18 months after CXL (Fig. 1).

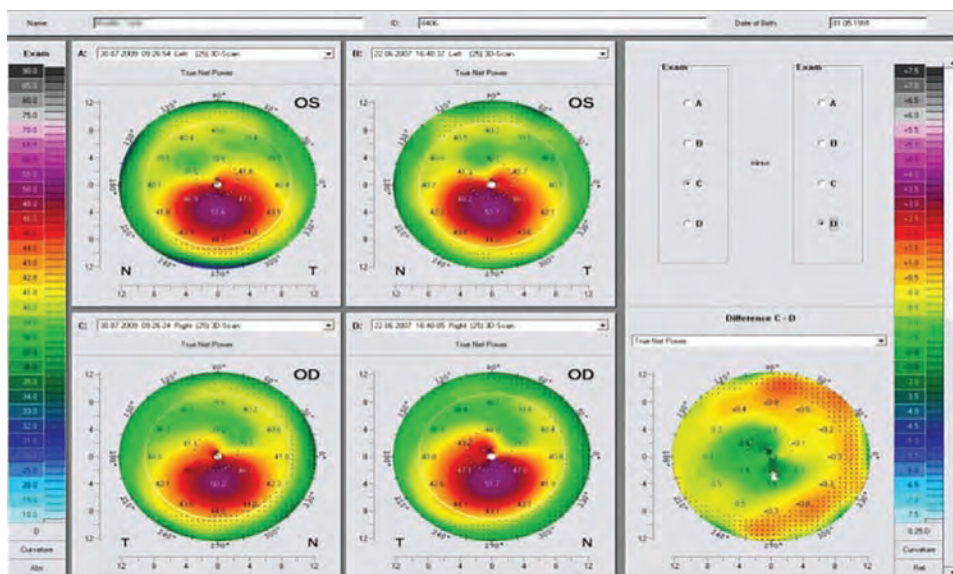


Fig. 1

On the other hand, he presented a case series of 5 eyes that had received standard epi-off CXL using the Dresden protocol, but that surprisingly showed flattening of up to 11.5D. The incidence of this massive flattening was 1:200 epi-off CXL procedures.¹

Until we have not fully understood why some patients show ‘normal’ flattening and others show massive flattening, Professor Hafezi prefers to perform PRK after CXL only once the K readings have stabilized (sequential over simultaneous).



To do so, we need to know how much an excimer laser pulse ablates in a previously cross-linked cornea. He cited two studies that were performed on different laser platforms, but were congruent in terms that both studies showed 9 to 12% less ablation in a previously cross-linked cornea.^{2,3} This will lead to the development of new nomograms for PRK excimer laser treatment of cross-linked corneas.

REFERENCES

1. Hafezi F, Koller T, Vinciguerra P, Seiler T. Marked remodelling of the anterior corneal surface following collagen crosslinking with riboflavin and UVA. *Br J Ophthalmol* 2011;95 8):1171-1172.
2. Chen S, Li Y, Stojanovic A, Zhang J, Wang Y, Wang Q, Seiler T. Evaluation of the efficacy of excimer laser ablation of crosslinked porcine cornea. *PLoS One* 2012;7(10):e46232.
3. Richoz O, Mosquera AS, Kling S, Hammer A, Magnago T, Bosch MM, Hafezi F. Determination of the excimer laser ablation rate in previously cross-linked corneas. *J Refract Surg* 2014;30(9):628-632.

PRESENTATION 11

Understanding and Managing Keratoconus (KC)

¹Michael Assouline, ²Tony Guedj, ³Lydia Bessede

¹⁻³Clinique de la Vision and Centre Léna Vision, Paris, France

Dr Assouline started his talk by saying that KC is a 'tough cookie' to swallow in medical science, and that it falls in the category of a failed scientific approach. There is still no evidence-based medicine for KC.

He claimed that no one knows the exact pathophysiology of the disease since there is no clearly identified cause or mechanism, and that the diagnosis is also problematic because there are no definitive diagnostic criteria. Moreover, the receiver operating curves are based on speculative incidence and prevalence because the rules of interpretation of corneal topography are defined by subjective observers. He also noted that there is no clear proof that Lasik is a direct cause of ectasia, and that it would be more appropriate from a clinical and medicolegal standpoint to refer to post-lasikectasia as a keratoconus revealed by Lasik.

The follow-up of KC is also problematic due to the great variation in presentation. Long-term follow-up is also difficult because of technical and geographic restrictions.

Therapeutic strategy consists of a number of means, combinations and sequences. The fact that KC is a relatively rare disease leads to series that include too few patients to arrive at firm conclusions with a high level of significance. He emphasized that there is also difficulty in conducting a meta-analysis due to the fact that there is no consensus on standardized outcome variables. Finally, the lack of funding precludes prospective randomized trials.

He raised the question as to whether KC is a single entity or a group of diseases (Fig. 1).

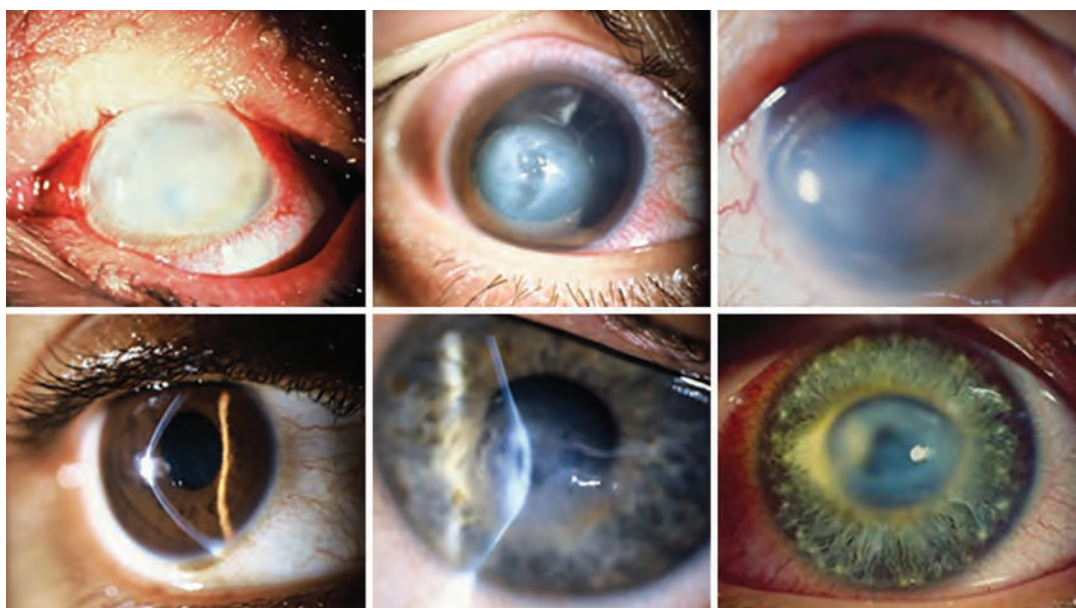


Fig. 1: Clinical photography of keratoconus from left to right and top to bottom: acute keratoglobus, acute keratoconus, acute pellucid marginal degeneration, extreme cone, descemet's break, and acute hydrops in a Down's syndrome patient (with iris Brushfield's spots)

Dr Assouline had tried to look at the published information on KC genetics for a better understanding of the disease, but that, too, turned out to be very complex. He said that we do not know whether the mechanical deformity is the result of altered genes and proteins, or whether expressed genes and proteins are the consequence of long-term structural changes in the cornea.

Dr Assouline gave a 12 points about keratoconus that needs to be addressed as follows:

1. Are we treating the cause or the consequence?
2. Long-term safety
3. Corneal topographic and remodeling effects
4. Corneal thinning and biomechanical loss
5. Need for subsequent interventions
6. Delaying or deferring PKP
7. Visual acuity
8. Refractive outcomes
9. Visual quality (contrast, distortion, fluctuation)
10. Contact lens tolerance
11. Quality of life
12. Patient satisfaction.

As few as 11 out of 4613 published papers on KC were conclusive prospective randomized trials. We also lack information on the epidemiology of the condition.

Characterizing KC based on biomechanical changes turned out not to be possible because the biomechanical features of KC overlap (Fig. 2).

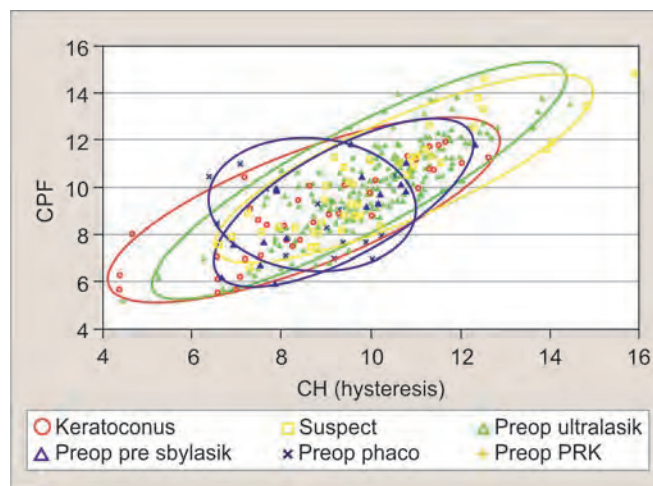


Fig. 2: Biomechanical changes in keratoconus (ORA: CH/CRF). Comparison of the ratio of cornea hysteresis (CH) and corneal resistance factor (CRF) in 320 eyes, fails to clearly discriminate populations of keratoconus patients, lasik patients, PRK patient and older presbylasik patients or cataract patients

According to him, the main outcome variable should be the quality of vision.

The common believe that KC no longer progresses after age of 35 years is not correct: there are many cases that showed progression even after the age of 70 years (Fig. 3, *Courtesy: John Kanelopoulos, MD*).

Dr Assouline continued by proposing an interesting assumption that KC may be a neurosensory rather than a corneal disease. He claimed that it is a disease of the regulation of the emmetropization process that does not affect the axial length of the eye but rather the corneal curvature.

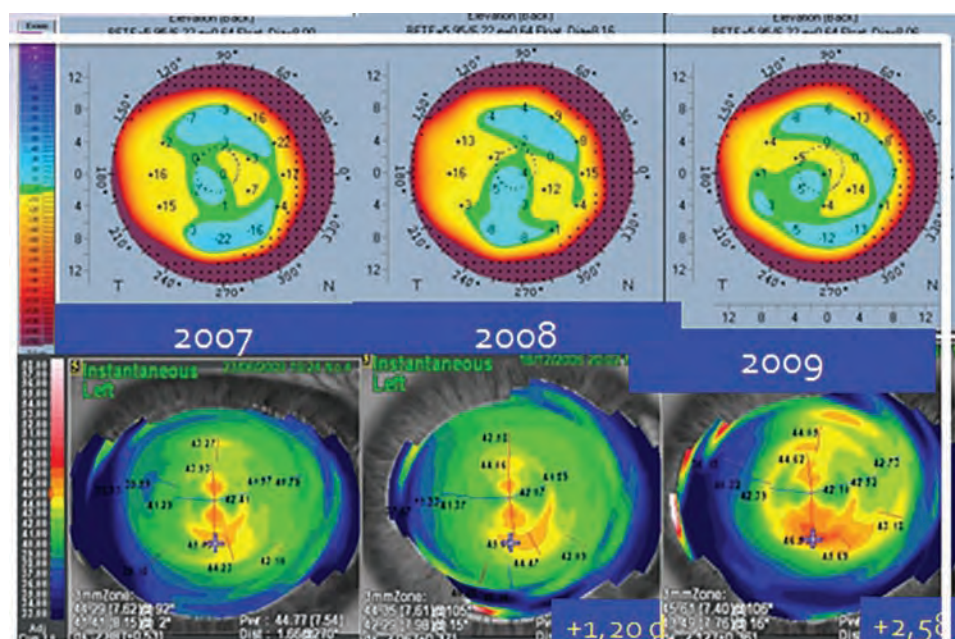


Fig. 3: Case presentation of progression after the age of 70 years (Courtesy: John Kanelopoulos)

In conclusion, Dr Assouline presented several provocative concepts with regard to KC: 1) It may be a visual differentiation or evolution of the emmetropization process of the eye from neurosensory origin rather than a primary structural corneal disease, (2) it is a more frequently occurring disease than currently believed, (3) its epicenter is in the Middle East, (4) it occurs and progresses at any time, at a faster rate when corneal structure is mechanically challenged (eye rubbing, Lasik), (5) managing KC should primarily aim at an early correction of high order aberration by optical or surgical means. This should contribute to the prevention of eye rubbing and limit KC progression and delay or avoid keratoplasty. Strengthening corneal structure with cross-linking may also help slowing down the process in selected cases, but should be used more conservatively than what is currently observed, since the exact long-term risk/benefit ratio is currently unknown.

PRESENTATION 12

How Mini-scleral Contact Lens Adaptation has Changed my Surgical Volume

Jérôme C Vryghem

Eye Surgeon at Clinique du Parc Leopold, Brussels, Belgium

Dr Vryghem noted that KC surgeons can use three different techniques to visually rehabilitate Keratoconus patients. These techniques are: topography-guided PRK, phakic lens implantation of intracorneal ring segments: they can be useful after cross-linking in younger patients with progressive keratoconus or in older patients with stable Keratoconus. He contends that we can aim and sometimes obtain near emmetropia. He also remarked that there will always be a complex debate for choosing among these techniques because of the parameters at play, such as BCVA, spherical equivalent, astigmatism, corneal thickness, aspect and centration of the conus, etc. All things considered, all three are good and yield encouraging results. However, we have to bear in mind that contact lenses will give a better, faster visual result.

Dr Vryghem said that since he started working with a specialized optometrist for the adaptation of contact lenses for difficult cases, such as keratoconus, post-radial keratotomy, post-scars, etc, his need to perform surgical visual rehabilitation (SVR) techniques has drastically diminished.

He explained how the mini scleral lenses work. Mini scleral contact lenses are less than 18 mm in diameter. They have to vault over the cornea and limbus and land on the sclera. Vision is restored by a liquid reservoir that fills in the surface irregularities of the cornea.

In comparison to rigid gas permeable contact lenses, mini scleral contact lenses are more comfortable, do not dislodge and are less likely to scar the cornea at long-term. Besides that, the manipulation of mini scleral lenses is much easier than with the older bigger scleral contact lenses.

In addition to those advantages, the wearing time of a mini scleral contact lens is increased by using a high oxygen transmissible contact lens material up to 12 hours/day. A toric scleral landing zone enhances the stability and centration of the lens with the possibility of incorporating a front cylinder, giving better visual acuity.

He noted that, in his practice, the use of mini scleral contact lenses has drastically decreased the need of performing SVR techniques by: 81% in ICRS, 80% in TG-PRK, and 60% in phakiclenses. In addition, patient satisfaction from the use of mini scleral lenses was high (an average of 7/10 on a scale from 1-10).

Dr Vryghem concluded his presentation by inviting the audience to think about the possibility of adapting mini scleral contact lenses before deciding upon surgery.

Voting Results

