

# The Athens Protocol

The management of keratoconus and post-LASIK ectasia by means of combined, same-day, topography-guided partial PRK and collagen cross-linking.

BY A. JOHN KANELLOPOULOS, MD

**P**rogressive, asymmetrical corneal steepening associated with an increase in myopic and astigmatic refractive errors, combined with midperipheral and/or peripheral corneal thinning, represents a constellation of findings in ectatic corneal disorders (eg, keratoconus and pellucid marginal degeneration).

These entities are associated with asymmetry upon presentation, unpredictability of progression, and myriad abnormal topographic findings. Similar observations after LASIK surgery have been described as *post-LASIK ectasia*.<sup>1-3</sup> Analyses of series of eyes that have developed post-LASIK ectasia have suggested that certain preoperative and/or operative features may be associated with this adverse outcome of LASIK or PRK.<sup>4</sup> The fact that ectasia can occur in the absence of these features, or that it may not occur in spite of them, has confounded surgeons' understanding of this complication.<sup>5</sup> Nevertheless, post-LASIK ectasia is a visually disabling complication whose ultimate surgical treatment is penetrating keratoplasty when glasses or contact lenses can no longer provide patients with visual quality that allows them to perform their activities of daily living.

During the past 10 years, the use of topical riboflavin combined with ultraviolet-A (UVA) irradiation to increase collagen cross-linking (CXL) has demonstrated the potential for retarding or eliminating the progression of keratoconus and post-LASIK ectasia. My colleagues and I have previously reported on the application of CXL in post-LASIK ectasia.<sup>6</sup> We have found that once the progression has stabilized, it is possible to treat the surface of the eye with customized PRK to normalize the corneal surface by reducing irregular astigmatism. After using CXL for cases of ectasia, my colleagues and I introduced the Athens Protocol, which consists of same-day, topography-guided partial PRK and CXL.

## EFFECTIVE AND SAFE

My colleagues and I at the LaserVision.gr Institute for Laser in Athens have found that simultaneous topography-guided partial PRK with corneal CXL is a safe and effective approach for normalizing the cornea and enhancing the visual function of eyes with ectatic conditions. Combined CXL with topography-guided, partial PRK can address high amounts of irregular astigmatism in these eyes.

Our theoretical and clinical evidence supports the use of

the Athens Protocol, in which the surgeon performs CXL and topography-guided surface ablation in the same session rather than sequentially.

We have found that surface ablation using the topography-guided Allegretto Wave Eye-Q 400-Hz and recently the WaveLight EX500 (500-Hz) laser systems (Alcon Laboratories, Inc., Fort Worth, TX; the EX500 is not yet available in the United States) effectively and predictably normalizes the corneal surface and improves patients' functional vision. We believe there is a synergistic effect when this procedure is performed simultaneously with CXL. Our combined approach also has a favorable safety profile. Although postoperative haze and delayed epithelial healing have occurred, these have been minor complications in a small number of eyes within a very large series.

## MEETING PATIENTS' NEEDS FOR VISUAL REHABILITATION

The efficacy of CXL for stabilizing keratectasia has been well established.<sup>6</sup> The procedure does, however, cause some corneal flattening. Significant residual astigmatism limiting contact lens wear may be a persistent problem for some patients. In these cases, topography-guided partial PRK can be indicated.

Surface ablation on a keratoconic eye may sound unorthodox, but the goal of our treatment using the topography-guided software is to normalize the corneal surface and improve BCVA. This is a therapeutic procedure, not a refractive one; some eyes experience an increase in myopia postoperatively but also a significant improvement in surface regularity and BSCVA. We use an ablation pattern that removes no more than 50  $\mu\text{m}$  of stroma and treats, at most, 2.00 to 2.50 D of astigmatism and up to 1.00 D of myopia.

## THE PROTOCOL

Using the Athens Protocol, we begin with a 6.5-mm phototherapeutic keratectomy to remove 50  $\mu\text{m}$  of epithelium. We perform the topography-guided partial PRK, apply mitomycin C (0.02% for 20 seconds), and then do the CXL procedure. The excimer laser ablation resembles that employed in a hyperopic treatment. Laser energy is applied using a 5.5-mm effective optical zone, and it targets the steepening of the area adjacent to the cone in an attempt to

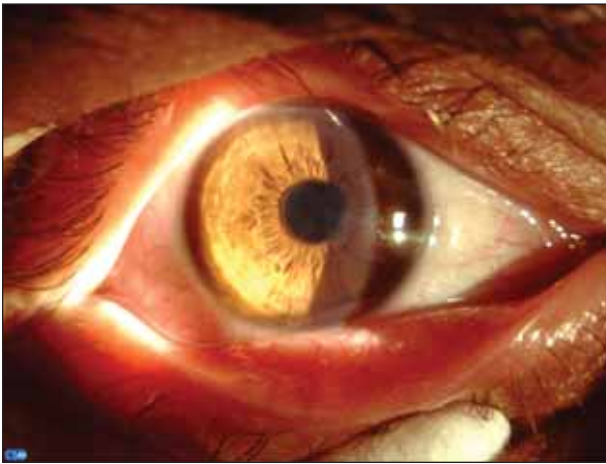

Figure 1. A clinical photograph (OD) of a 27-year-old man with advanced keratoconus. His preoperative BSCVA was 20/50 with -2.50 -5.00 X 80. He underwent treatment according to the Athens Protocol and now has a UCVA of 20/30 and a BSCVA of 20/20 with -1.00 -1.50 X 85. The slit-lamp photograph shows the corneal clarity and ground-glass appearance typical of CXL.

normalize the corneal surface. In support of our rationale for performing the two procedures simultaneously with the ablation first, data have shown that the corneal epithelium and Bowman membrane can act as barriers to the penetration of UVA light into the stroma.<sup>7</sup> Because phototherapeutic keratectomy/PRK removes the epithelium and Bowman membrane, it seems intuitive that the efficacy of the CXL procedure would increase. This concept is supported by clinical findings.<sup>8-10</sup>

Looking for signs of hyper-reflectivity, we inspected the optical coherence tomography of a patient who had CXL alone in one eye and the Athens Protocol in the other. We recently described hyper-reflectivity as a sign of the extent of cross-linking.<sup>10</sup> The area of CXL in this patient was much more broad and dense in the eye treated according to the Athens Protocol.

We also introduced the theory that the PRK-treated eye represents a better biomechanical model on which to perform CXL.<sup>8-10</sup> Hypothetically, an eye with a more regular surface would be better strengthened using CXL and would be more likely to remain stable after the procedure. This is in comparison to an eye that has ongoing strain from raised IOP and localized eye rubbing over the cone's peak. We believe that the redistribution of corneal strain through remodeling using surface ablation is a significant factor in the synergistic effect achieved when the two procedures are performed together. The simultaneous technique also avoids the removal of cross-linked corneal tissue, which occurs when CXL is performed before the laser treatment.

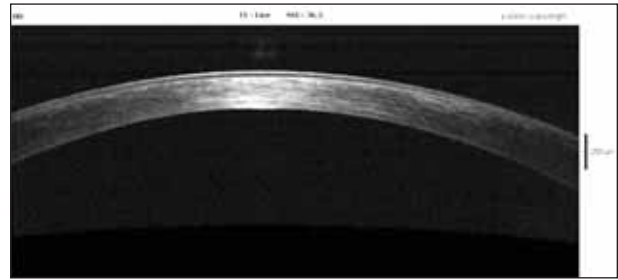

Figure 2. Corneal optical coherence tomography of the same eye as in Figure 1 taken 7 months after the Athens Protocol. Note the anterior corneal hyper-reflectivity consistent with CXL and the demarcation line at a depth of about 300  $\mu\text{m}$  depicting effective CXL.

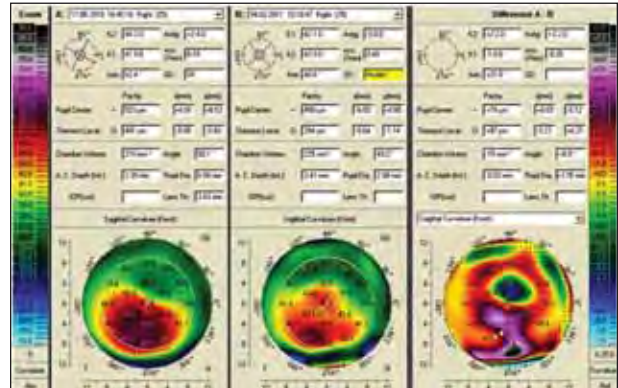


Figure 3. A comparison of the preoperative (left) and 7-month postoperative (middle) Pentacam Comprehensive Eye Scanner (Oculus, Inc., Lynnwood, WA) images showing significant normalization of the cone, keratometric flattening, and improved symmetry. The difference map is on the right.

**CLINICAL RESULTS**

We reported our results from a comparison of two large, consecutive series of eyes treated at the same session or with CXL first followed 1 year later by a topography-guided surface ablation (Figures 1-3). Our data showed statistically significant differences in several parameters favoring the same-day procedure.<sup>10</sup> The published study included 127 eyes in the sequential group and 198 eyes treated according to the Athens Protocol.

For the eyes in the sequentially treated group, the mean logMAR UCVA improved from 0.90 to 0.49, the mean logMAR BSCVA improved from 0.41 to 0.16, the mean keratometry values decreased by 2.75 D, the mean manifest refraction spherical equivalent decreased by 2.50 D, and the mean haze score was 1.20. For the eyes in the simultaneous group, there was a significantly greater improvement in both mean logMAR UCVA (from 0.96 to 0.30) and mean logMAR BSCVA (from 0.39 to 0.11) as

*(Continued on page 34)*

well as a significantly greater mean reduction in the manifest refraction spherical equivalent (-3.20 D) and keratometry value (-3.50 D). The mean haze score in the simultaneous group was 0.5—significantly lower than in the sequentially treated group. Central corneal thickness decreased by 70  $\mu\text{m}$  in both treatment arms, and there was no significant change in endothelial cell count in either group.

These findings demonstrate that performing the two procedures together offers the advantages of less PRK-associated scarring and better penetration of riboflavin and UVA to achieve a wider and deeper CXL effect with greater corneal flattening.

## CONCLUSION

Our findings suggest potentially promising results with same-day, simultaneous topography-guided PRK and collagen CXL (Athens Protocol) as a therapeutic intervention in highly irregular corneas with keratoconus and progressive post-LASIK ectasia. We have reported for the first time effective CXL treatment in cases with minimal thickness (< 350  $\mu\text{m}$ ). It is unfortunate that topography-guided ablations are not yet available in the United States. The future FDA approval of this technology and its potential to normalize highly irregular corneas—along with CXL—may significantly reduce the need for further inventions such as intracorneal rings or keratoplastic procedures in these cases. This treatment has definitely done so in European practices during the past 10 years. ■

*A. John Kanellopoulos, MD, is the director of the LaserVision.gr Eye Institute in Athens, Greece; an attending surgeon at the Department of Ophthalmology, Manhattan Eye, Ear, and Throat Hospital in New York; and a clinical professor of ophthalmology at New York University Medical School in New York. Dr. Kanellopoulos may be reached at 30 21 07 47 27 77; [ajkmd@mac.com](mailto:ajkmd@mac.com).*



1. Binder PS. Ectasia after laser in situ keratomileusis. *J Cataract Refract Surg*. 2003;29:2419-2429.
2. Randleman JB, Russell B, Ward MA, et al. Risk factors and prognosis for corneal ectasia after LASIK. *Ophthalmology*. 2003;110:267-275.
3. Tabbara K, Korb A. Risk factors for corneal ectasia after LASIK. *Ophthalmology*. 2006;113:1618-1622.
4. Klein SR, Epstein RJ, Randleman JB, et al. Corneal ectasia after laser in situ keratomileusis in patients without apparent preoperative risk factors. *Cornea*. 2006;25:388-403.
5. Binder PS. Analysis of ectasia after laser in situ keratomileusis: risk factors. *J Cat Refr Surg*. 2007;33:1530-1538.
6. Hafezi F, Kanellopoulos J, Wiltfang R, et al. Corneal collagen cross-linking with riboflavin and ultraviolet A to treat induced keratectasia after laser in situ keratomileusis. *J Cat Refr Surg*. 2007;33:2031-2040.
7. Kolozsvari L, Nogradi A, Hopp B, Bor Z. UV absorbance of the human cornea in the 240- to 400-nm range. *Invest Ophthalmol Vis Sci*. 2002;43(7):2165-2168.
8. Kanellopoulos AJ, Binder PS. Management of corneal ectasia after LASIK with combined, same-day, topography-guided partial transepithelial PRK and collagen cross-linking: the Athens Protocol. *J Refract Surg*. 2011;27(5):323-331.
9. Krueger RR, Kanellopoulos AJ. Stability of simultaneous topography-guided photorefractive keratectomy and riboflavin/UVA cross-linking for progressive keratoconus: case reports. *J Refract Surg*. 2010;26(10):S827-S832.
10. Kanellopoulos AJ. Comparison of sequential vs same-day simultaneous collagen cross-linking and topography-guided PRK for treatment of keratoconus. *J Refract Surg*. 2009;25(9):S812-S818.