

# What is the earliest test for glaucoma?

## Use of the ganglion cell complex as a new diagnostic indicator

### Dr Adrian S Bruce

BScOptom PhD FAAO FACO  
Australian College of Optometry  
and The University of Melbourne

### Iris Huang

BOptom PGDipAdvClinOptom  
PGCertOcTher  
Australian College of Optometry

GLAUCOMA IS AN OPTIC neuropathy characterised by the loss of retinal ganglion cells and the retinal nerve fibre layer.<sup>1</sup> There is a diversity of factors that may lead to glaucoma but key issues in common are the effect on the retinal ganglion cells and potentially devastating visual loss.<sup>2</sup>

What is the earliest test for glaucoma? The answer depends on the type of glaucoma. If the pressure is consistently high, that measurement alone will alert the clinician that further work-ups, monitoring and possible treatment are required. However, in many patients the pressure is not that high but the discs are asymmetrical or suspicious, or there are other risk factors. What should we be assessing?

As retinal ganglion cell (RGC) loss cannot be visualised in a standard clinical examination, the standard procedure for glaucoma assessment often relies on detection of secondary changes in the optic nerve head (ONH), careful examination of the retinal nerve fibre layer (RNFL) and visual field test.

#### Optic nerve head

Classic glaucomatous signs at the ONH include thinning or notching of the neuroretinal rim (NRR), asymmetry of NRR, excavation and enlarged cup to disc ratio over a period of time, Drance

haemorrhage, or bayoneting and beading of blood vessels.

#### Retinal nerve fibre layer

In some glaucoma patients, a diffused loss of RNFL can be seen as a wedge of diminished light reflection. This is best appreciated with a red-free (green or blue) filter. However, early glaucoma RNFL loss often appears as subtle attenuation of the light reflection and can be difficult to detect.

#### Visual field

Glaucomatous visual field defects include an early paracentral scotoma, which may slowly merge and form an arcuate defect that continues to the blind spot. A nasal step may be present and one hemifield more depressed than the other. The visual field defect should correspond to the NRR change and/or RNFL loss.

As clinical examination is subjective and clinician dependent, early glaucoma signs can be overlooked from time to time. Early treatment opportunities may be missed if relying primarily on a visual field defect. This is because a substantial reduction in RGC population can occur before clinically significant visual field defect can be detected. Since the introduction of optical coherence tomography (OCT), the technology has assisted clinicians in the detection of RNFL loss associated with glaucoma. Due to advances in OCT technology, we can now acquire a 6 x 6 mm cube of data in the peripapillary region in less than 1.5 seconds. Using OCT ONH scan to analyse peripapillary RNFL is now a widely employed parameter for diagnosing glaucoma.

More recently, the measurement of the perimacular ganglion cell layer has emerged as a new diagnostic parameter in glaucoma with spectral domain OCT. Various OCT machines now use this technique to capture the thickness of the innermost three retinal layers

around the macula. These three layers, known as the macular ganglion cell complex (GCC), are the retinal nerve fibre layer, ganglion cell layer and inner plexiform layer.<sup>3</sup> The GCC contain the axons, cell bodies and dendrites of the ganglion cells, respectively, which have been shown to be preferentially affected by glaucoma.<sup>4</sup> This new parameter may assist early glaucoma detection, especially in cases where the ganglion cell loss is predominately macular rather than peripheral.

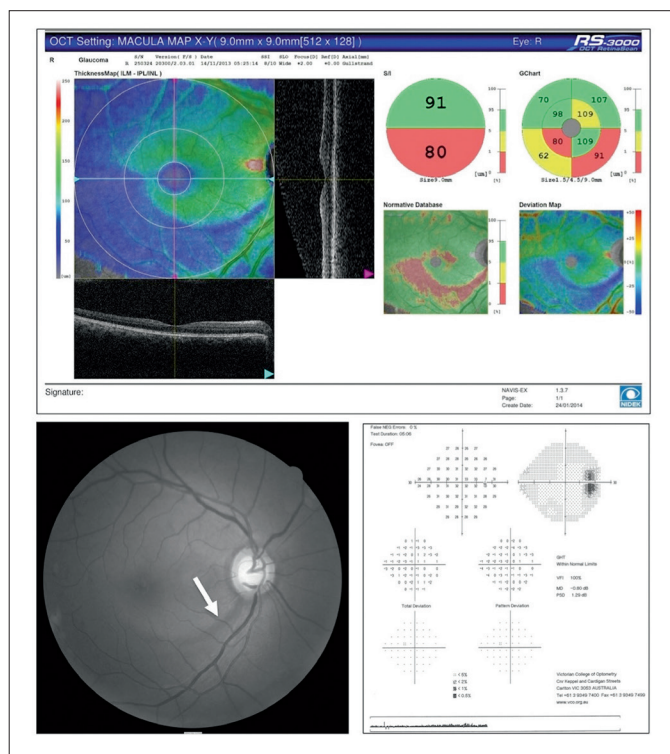
### CASE REPORTS

#### Examples of using GCC measurement in assisting glaucoma diagnosis

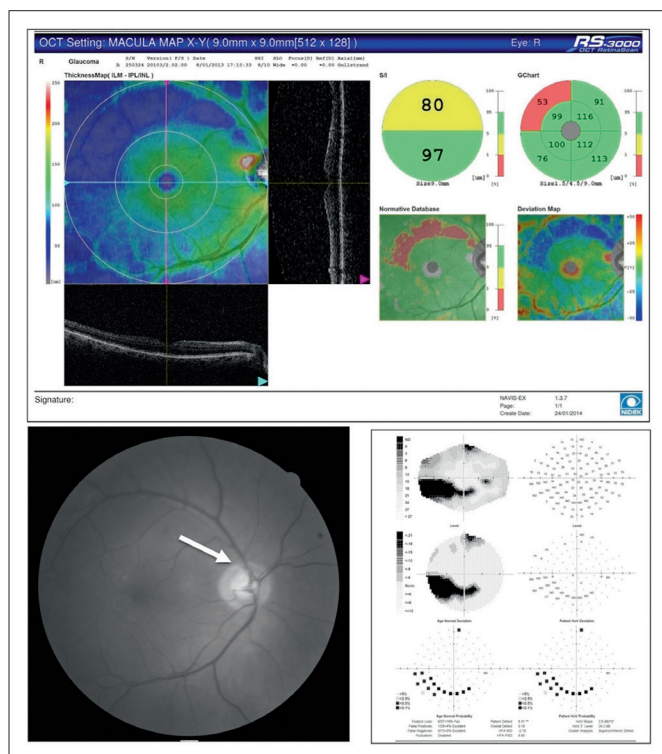
Case 1 (Figure 1) shows a large glaucomatous cupping with a slit of inferior RNFL defect (as shown in the red free photo). The Nidek OCT macular scan highlighted the inferior arcuate loss, enabling us to quantify the total GCC loss and compare superior and inferior hemifields. Note that there is no visual field defect in this case, once again echoing the previous studies that structural loss can precede detectable functional loss by up to five years.<sup>5</sup>

Case 2 (Figure 2) shows an exemplary structure-function relationship with a classic glaucomatous inferior arcuate field loss, which corresponds to the superior temporal rim notch. RNFL loss is not readily detectable in the red-free photo; however, the Nidek OCT macular GCC scan shows a clear superior arcuate loss.

Since the new macular GCC scan has gained popularity in glaucoma management, many studies have been performed in the past few years to investigate its diagnostic ability. Studies comparing the diagnostic performance of the GCC parameter to peripapillary RNFL have found a



▲ Figure 1. Nidek OCT scan of the macular ganglion cell complex (GCC) shows right inferior shallow arcuate loss in a 57-year-old female with early glaucoma. The right inferior GCC is 15 μm thinner than the left inferior GCC (not shown). The red-free fundus image shows inferior nerve fibre loss (arrow) but the visual field is normal.



▲ Figure 2. Nidek OCT scan of the macular ganglion cell complex (GCC) shows right superior arcuate loss in a 64-year-old male with glaucoma. The right superior GCC is 19 μm thinner than the left superior GCC (not shown). The red-free fundus image shows superior temporal rim notch (arrow) and the visual field shows a corresponding inferior arcuate loss.

GCC scan to be comparable with the ONH scan in detecting early, moderate and advance glaucoma.<sup>4</sup> The studies also found that GCC measurements and ONH scan had similar structure-function relationships with visual field sensitivity.

Limitations of GCC parameter were also discussed in many of these papers. Common issues that are also shared with peripapillary RNFL scan includes signal quality and image artifact. Any coexisting macular pathology such as ARMD may affect GCC thickness measurement. In addition, most GCC scans cover a 7 x 7 mm grid on the macula; patients who present with RNFL defect outside of this area may escape detection.

This is less of an issue now as imaging technology has advanced. Nidek OCT RS 3000 software V2.0.0 or higher allows 3-D scanning over a 9 x 9 mm square in only 1.6 seconds. This function provides clinicians with the opportunity to measure GCC thickness across a wider area. Furthermore, GCC measurement has a theoretical

advantage in glaucoma diagnosis as RGC loss occurs early in the pathogenesis of the disease. Besides, ONH scanning may be complicated by other non-glaucomatous conditions, such as extensive peripapillary atrophy in high myopia.

In summary, macular GCC scan is able to illustrate areas of glaucomatous ganglion cell loss with the advantage of correlation with visual field defects point by point, as shown in Case 2 above. Clinicians should carefully interpret the individual patient's clinical signs and consider including macular GCC thickness as part of the glaucoma assessment procedure.

1. Quigley HA. Examination of the retinal nerve fibre layer in the recognition of early glaucoma damage. *Trans Am Ophthalmol Soc* 1986; 84: 920-966.
2. Bruce AS, O'Day J, McKay D, Swann PG. *Posterior Eye Disease and Glaucoma A-Z*. Oxford: Elsevier 2008, 336 pp.
3. Morooka S, Hangai M, Nukada M, Nakano N, Takayama K, Kimura Y et al. Wide 3-dimensional macular ganglion cell complex imaging with spectral-domain optical coherence tomography in glaucoma. *Invest Ophthalmol Vis Sci* 2012; 53: 4805-4812.
4. Kim NR, Lee ES, Seong GJ, Kim JH, An HG, Kim CY. Structure-function relationship and diagnostic value of macular ganglion cell complex measurement using fourier-domain OCT in glaucoma. *Invest Ophthalmol Vis Sci* 2010; 51: 4646-4651.
5. Quigley HA, Katz J, Derick RJ et al. An evaluation of optic disc and nerve fibre layer examinations in monitoring progression of early glaucoma damage. *Ophthalmology* 1992; 99: 19-28.