

Review Article

Age-related maculopathy and the impact of blue light hazard

Peep V. Algvere,¹ John Marshall² and Stefan Seregard¹

¹Karolinska Institute, St Erik's Eye Hospital, Stockholm, Sweden

²Rayne Institute, St Thomas' Hospital, London, UK

ABSTRACT.

The pathogenesis of age-related maculopathy (ARM), the most common cause of visual loss after the age of 60 years, is indeed a complicated scenario that involves a variety of hereditary and environmental factors. The pathological cellular and molecular events underlying retinal photochemical light damage, including photoreceptor apoptosis, have been analysed in experimental animal models. Studies of age-related alterations of the retina and photoreceptors, the accumulation of lipofuscin in retinal pigment epithelium (RPE) cells, and the formation of drusen have greatly contributed to our knowledge. A new concept of an inflammatory response to drusen has emerged, suggesting immunogenic and systemic reactions in Bruch's membrane and the subretinal space. Oxidative stress and free radical damage also impact on the photoreceptors and RPE cells in the ageing eye. Based on the photoelectric effect, a fundamental concept in quantum physics, the consequences of high-energy irradiation have been analysed in animal models and cell culture. Short-wavelength radiation (rhodopsin spectrum), and the blue light hazard (excitation peak 440 nm), have been shown to have a major impact on photoreceptor and RPE function, inducing photochemical damage and apoptotic cell death. Following cataract surgery, there is a dramatic change in ocular transmittance. In aphakic or pseudophakic eyes (with clear intraocular lenses), high-energy (blue) and ultraviolet-A radiation strikes the retina. Epidemiological data indicate a significantly increased 5-year incidence of late ARM in non-phakic eyes compared with phakic eyes. In recent years, putative prophylactic measures against ARM have emerged. The implantation of 'yellow' intraocular lenses (IOLs) that absorb high-energy blue radiation is, from a theoretical point of view, the most rational approach, and, from a practical point of view, is easy to accomplish. With increasing age, RPE cells accumulate lipofuscin (chromophore A2E). It is noteworthy that the yellow IOL not only protects A2E-laden human RPE cells from blue light (peak 430 nm) damage, but also alleviates the detrimental effects of green (peak 550 nm) and white light. A prophylactic treatment using antioxidants is aimed at counteracting oxidative stress and free radical cellular damage. The Age-Related Eye Disease Study (AREDS), a randomized clinical trial, showed a significantly lower incidence of late ARM in a cohort of patients with drusen maculopathy treated with high doses of antioxidants than in a placebo group. In recent years, considerable progress in retinal research has been achieved, creating a platform for the search for new prophylactic and therapeutic measures to alleviate or prevent photoreceptor and RPE degeneration in ARM.

Key words: age-related maculopathy – short-wavelength radiation – blue light hazard – lipofuscin – free radicals – aphakia – retinal damage – 'yellow' intraocular lens (IOL) – antioxidants

Acta Ophthalmol. Scand. 2006; 84: 4–15

Copyright © Acta Ophthalmol Scand 2006.

doi: 10.1111/j.1600-0420.2005.00627.x

Introduction

It has long been speculated that visible light, even of ordinary everyday intensity, may cause retinal damage or contribute to the development of early and late age-related maculopathy (ARM). However, there are indications in some epidemiological studies that exposure to sunlight may be associated with the development of ARM (Cruickshanks et al. 1993, 2001). Extensive work in animal models and other experimental settings, such as cell culture, has unequivocally shown that visible light can cause retinal cellular damage to the photoreceptors and retinal pigment epithelium (RPE). Accumulating evidence indicates that in aphakic or pseudophakic eyes, there may be an increased risk of light damage to the retina, and particularly in response to blue light irradiation.

Photochemical retinal light damage

Ocular transmittance of radiation in young and elderly human eyes

Optical radiation includes ultraviolet light (100–400 nm), visible light (400–750 nm) and infrared radiation (750–10 000 nm). Most ultraviolet radiation below 295 nm is absorbed by the cornea, whereas ultraviolet-B (UVB) (280–315 nm) and ultraviolet-A (UVA) (315–400 nm) are blocked by the lens. However, a fraction of radiation with wavelengths shorter than 400 nm (centred at 320 nm) does reach the retina (Boettner & Wolter 1962).

In the young eye, ocular transmittance is very high, reaching close to

90% at 450 nm. The transmittance of elderly lenses is much lower and has considerable interindividual variation, but generally does not reach 70–80% until wavelengths of 540 nm. This is in contrast with aphakic eyes, in which substantial energy from radiation of wavelengths longer than 310 nm, thus including UVA, will strike the retina.

The photoelectric effect

At the birth of quantum physics a century ago, it was suggested that the energy of a photon is proportional to its radiation frequency: $E = hf$ (where h = Planck's constant, f = radiation frequency) (Planck 1900; quoted in Benson 1991). The photoelectric effect (Einstein 1905; quoted in Benson 1991) demonstrates that the high energy of short-wavelength radiation, such as X-rays, UV and blue light, has the capacity to induce an electric current from certain metal bodies. In contrast, longer wavelengths with low energy quanta (e.g. > 600 nm) are insufficient to produce a photoelectric effect in the experimental setting (Fig. 1). In recent years, the biological effects of different frequencies of radiation to the eye have been analysed and defined in some detail.

Photochemical class I damage

It was demonstrated long ago that relatively low light intensities could damage the retina in the experimental animal when long exposure duration

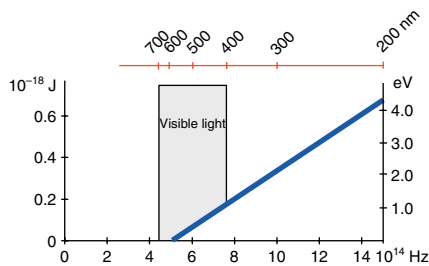


Fig. 1. The photoelectric effect demonstrates that, in a certain experimental setting, high-energy quanta induce an electric current in a metallic body, but low energy photons (550–700 nm) are unable to induce a current. Energy quanta in the blue light spectrum (400–500 nm) have a much higher capacity to remove electrons from molecules, creating reactive oxygen species, than visible light in the 500–600 nm range is able to. Radiation frequency expressed in Hertz (Hz), energy in joules (J) and electron volts (eV), wavelength in nanometres (nm).

was used. In the rat, this phototoxicity had the spectrum of rhodopsin and scotopic vision and displayed a degeneration of the rod photoreceptors (Noell et al. 1966). The energy distribution of sunlight reaching the earth is high in the rhodopsin spectrum (Fig. 2).

Photochemical class II damage

When light of relatively high intensity is used with short exposure time (minutes, hours), retinal damage will increase in response to shorter wavelengths, that is the high energy portion of the visible spectrum (400–500 nm). This has been referred to as the 'blue light hazard', and has an excitation peak around 440 nm (Fig. 2). In primates, the resulting retinal damage has been described as located in the RPE layer (Ham et al. 1978). The degree of retinal injury is dependent on oxygen concentration and antioxidants seem to reduce the light damage (Organisciak & Winkler 1994).

Thus, both photoreceptors and RPE cells may be damaged by light, but the type of injury is modified by several factors, such as intensity, duration, intermittence of exposure to light, and spectral distribution. Laube et al. (2004) reported that a small fraction of UV radiation (around 300 nm) is transmitted by the crystalline lens (Fig. 3). Generally, the first alterations occur in the photoreceptor outer segments, followed by changes in the RPE cells (Kuwabara & Funahashi 1976). Whether rods or cones are affected first seems to vary between different

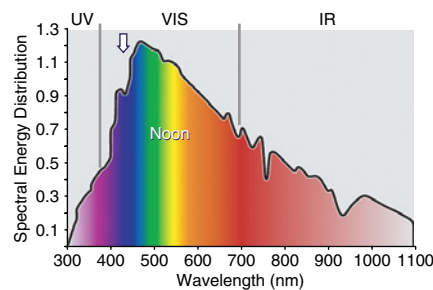


Fig. 2. Spectrum of sunlight reaching the earth. The visible light has a spectral range of 400–750 nm. The energy of the sunlight is high in the rhodopsin spectrum. The high-energy (short-wavelength) part of the spectrum (vertical arrow) comprises blue and violet light and is responsible for blue light hazard (excitation peak around 440 nm).

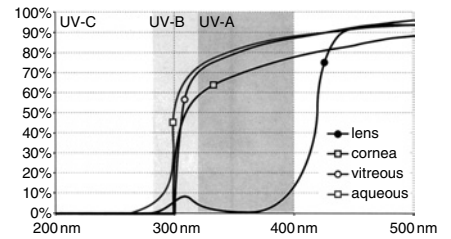


Fig. 3. Transmittance of ultraviolet radiation in the eye. The cornea, vitreous and aqueous transmit blue light and UVA radiation to the retina. The crystalline lens absorbs part of the blue light and most of the UVA radiation but transmits a small fraction of UVA and UVB at around 300 nm. (Reprinted by permission of Laube et al.; Ophthalmology 2004; 111 : 884.)

species. In the rat, which has a predominantly rod-based retina, the cone photoreceptors survive despite a widespread degeneration of rods (Cicerone 1976). However, in pigeons, which have a predominantly cone-based retina, the cone photoreceptors degenerate early, but this phenomenon may reflect the slower renewal of cone outer segments versus that of rods (Marshall 1985). Blue cones are particularly vulnerable when exposed to blue light (Sperling & Johnson 1980).

Age-related alterations of the retina

Population-based studies on the prevalence of ARM show a strong positive correlation with both age and smoking (Thornton et al. 2005). Retinal pigment epithelium cells are post-mitotic cells and should persist for the entire life of the individual. Under normal conditions, RPE cells do not divide, but they are able to proliferate under certain pathological conditions, such as retinal detachment. It has been calculated that each RPE cell will phagocytose about 3 billion outer segment discs during a 70-year lifetime (Marshall 1987).

There is an age-related loss of RPE cells in the retina, and the number of RPE cells is reduced, particularly in the macular centre. The phagocytotic workload must then be carried out by neighbouring RPE cells in an attempt to compensate for functional loss. In addition, the density of melanosomes in RPE cells decreases with age. Melanin plays a role in scavenging

free radicals and is responsible for absorption of light, thus minimizing stray light (Holz et al. 2004a). There is a continuous increase in intracellular lipofuscin in the RPE cells over time, which deteriorates cellular function and makes the retina more sensitive to radiation damage (Schütt et al. 2002). Furthermore, the formation of drusen in Bruch's membrane may compromise RPE cell function by impeding fluid transport (Starita et al. 1997) and inducing inflammatory responses (Hageman et al. 2001). In animal experiments, an increased susceptibility to light damage was reported in older rats compared with young control rats (O'Steen & Anderson 1974), indicating that the defence mechanisms in the elderly retina are insufficient to prevent cellular light damage. Accordingly, this scenario makes the ageing human retina, particularly the fovea, sensitive to light damage, and all the more so as the maximum irradiance falls on the macular area, as has been previously described (Algvere & Seregard 2002).

Rod photoreceptors seem to be more vulnerable and suffer more significant loss during ageing compared with cones (Gao & Hollyfield 1992). In human eyes, the number of rods was found to reduce by approximately 30% with age, whereas the number of cones did not change significantly (Curcio et al. 1993, 2000). Morphological studies have indicated a greater loss of rods in the macula than in the periphery. This concept is supported by recent investigations into the expression of the rod photoreceptor proteins rhodopsin and arrestin, which showed a significant decline in expression in the macula, but not in the periphery, with progression of ARM (Ethen et al. 2005). Whether this decline in rod density is genetic or whether it is related to general senescence, radiation (light) damage or other factors remains to be determined.

Yellow macular pigments

The macula displays yellow pigments of the carotenoid family, such as lutein and zeaxanthine. These pigments are located mainly within the Henle fibre layer and have an absorbance spectrum peaking at 460 nm; thus they act as filters for blue light and UV radiation (Krinsky et al. 2003). These carotenoids

are also excellent free radical scavengers. Approximately one half of the total carotenoids in the retina are found in the macula. However, the concentration of macular pigments drops to half its value 1.5 degrees from the fixation centre, thus conferring substantial protection to the fovea only (Kilbride et al. 1989).

It has been reported that the amount of carotenoids is reduced in elderly eyes (Gellermann et al. 2002). However, in recent studies, no significant differences in macular pigment density were found with age or between the various stages of ARM (Berendschot et al. 2002; Ciulla & Hammond 2004; Jahn et al. 2005). It was concluded that all findings to date are associative only and there seems to be no direct evidence that high macular pigment levels confer a protective effect (Davies & Morland 2004).

Lipofuscin

Lipofuscin is a hallmark of ageing, a product accumulating in post-mitotic cells, such as neurons, cardiac muscle cells and RPE cells (Terman et al. 2004). Lipofuscin represents incompletely degraded membrane material and waste products. Ageing of cells is associated with accumulation of lipofuscin and decreasing activity of enzyme systems. Lipofuscin is thus considered a biomarker for cellular ageing (autophagy) and cumulative oxidative damage (Schütt et al. 2002).

There is a continuous accumulation of lipofuscin in RPE cells with ageing and deteriorating cellular function. By the ninth decade of age, lipofuscin granules outnumber melanin granules and a fusion of melanolipofuscin commonly occurs, occupying a substantial part of the cytoplasmic space (Feeney-Burns et al. 1980). The maximal distribution of lipofuscin coincides with the maximal distribution of rods (Marshall 1987). Accordingly, the fovea centralis has a lower density of lipofuscin than the parafoveal region, which in turn, displays much more lipofuscin than the peripheral retina (Delori et al. 2001). This fact may reflect the higher cellular density coupled with the pronounced irradiance of the macular area, as compared with the peripheral retina.

In areas with elevated concentration of lipofuscin in the retina, RPE atrophy may develop in human ARM (Holz

et al. 2001; Bindewald et al. 2005). A concomitant reduced retinal sensitivity in areas with elevated auto fluorescence can be demonstrated on microperimetry (Holz et al. 2004a), thus confirming the cellular damage in this area of the retina. By the use of autofluorescence *in vivo*, the presence of lipofuscin was found to precede subsequent development of exudative ARM (Spaide 2003a; Schmitz-Valkenberg 2004).

Lipofuscin contains different fluorophores. A2E is a major retinoid fluorophore, derived from vitamin A-aldehyde and ethanolamine, and most probably originating from oxidative damage to the photoreceptor outer segments. Other components of lipofuscin seem to be derived from free radical-induced oxidation of polyunsaturated lipids (Fig. 4).

Lipofuscin is associated with several deleterious effects on cellular function. It contains substances that inhibit lysosomal degradation (Eldred 1998), and express photoreactivity (Wihlmark et al. 1997). Lipofuscin generates reactive oxygen species on photoexcitation (Boulton et al. 1993; Gaillard et al. 1995) and is phototoxic to RPE cells in culture (Davies et al. 2001). In addition, it was recently reported that chloroform-insoluble components of human RPE lipofuscin significantly increase with age, and that these components are likely to mediate the formation of reactive oxygen species, particularly in response to blue light (Rozanowska et al. 2004).

Drusen

There is a conspicuous accumulation of debris or waste products in the extracellular matrix between the RPE and the choroid (Bruch's membrane). Although they are mostly randomly distributed in the macula, drusen are likely to form in the perifoveal retina, where the concentration of rod photoreceptors is comparatively high. Accordingly, at the edge of a geographic atrophy the formation of drusen is often conspicuous, which is believed to reflect rod damage (Holz et al. 2004a).

Non-degraded material is extruded from the RPE cells. Basal laminar deposit is located between the RPE plasma membrane and the basal lamina. Basal linear deposit accumulates between the RPE basal lamina

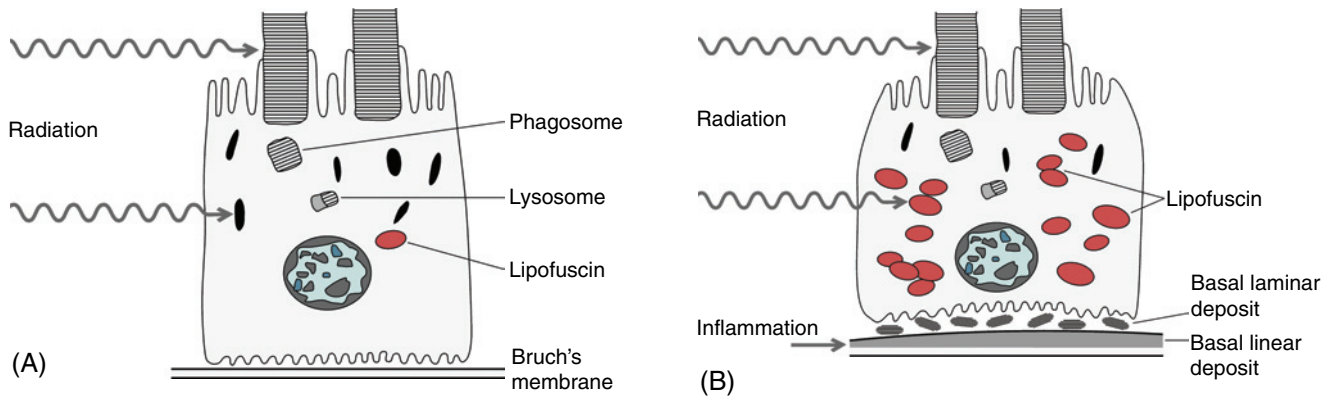


Fig. 4. Schematic illustration of ageing in RPE cells. (A) In response to radiation, the photoreceptor outer segments are subjected to the peroxidation of their polyunsaturated lipids, their tips are shed and phagocytosed by RPE, digested in lysosomes; the residual bodies eventually form lipofuscin. The short-wavelength radiation (blue light) will induce blue light damage, including oxidative mechanisms, mediated by lipofuscin chromophores, to several vital structures such as mitochondria and DNA. (B) With increasing age, the amount of lipofuscin (red symbols) in RPE will augment considerably, making the cell more vulnerable to irradiation and oxidative damage. Some undigested end-products are extruded from RPE cells to the extracellular space (basal laminar deposit) and to Bruch's membrane (basal linear deposit), in which a secondary inflammatory response may occur (clinically recognized as soft drusen).

and the inner collagenous layer of Bruch's membrane (Fig. 4B). Basal linear deposit is the ultrastructural correlate to soft drusen (Green & Enger 1993; Curcio & Millican 1999). The thickening of Bruch's membrane with cross-linking between the collagen fibres and increasing lipid incorporation render a decreased hydraulic conductivity and the membrane becomes more hydrophobic, impeding fluid transport (Starita et al. 1997; Guo et al. 1999). The main resistance develops in the inner collagenous layer of Bruch's membrane, most likely due to a progressive accumulation of lipid deposits in this layer (Pauleikoff et al. 1990; Starita et al. 1997; Holz et al. 2004a). These lipids contain phospholipids and neutral fats and show a continuous increase with age. The peroxidized lipids seem to be derived, at least partly, from polyunsaturated fatty acids in the photoreceptor outer segments (Spaide et al. 2003b).

Inflammatory response in ARM

There is accumulating evidence that local inflammation may exacerbate the effects of the primary extracellular deposits in Bruch's membrane clinically recognized as drusen. It is known from general pathology that foreign material deposited in the extracellular space, sooner or later, is likely to induce an inflammatory or immunogenic response. In surgically excised

subretinal fibrovascular membranes from human eyes with late ARM, inflammatory cells, such as macrophages and lymphocytes, are found regularly (Seregard et al. 1994; Spraul et al. 1999; Czaky et al. 2004). An activation of monocytes that express the angiogenic tumour necrosis factor (TNF- α) was recently demonstrated in patients with ARM (Cousins et al. 2004).

Morphological investigations indicate that cellular remnants, melanin granules, lipofuscin and other debris derived from RPE cells are extruded to the inner collagenous layer of Bruch's membrane (Johnson et al. 2003). A new concept has emerged, suggesting that immunogenic cells, such as dendritic cells, participate in the cellular response and that several complement components are activated (Hageman et al. 2001).

In an animal model of ARM, complement activation and immune complex deposition (IgG) in the RPE and choroid accompanied senescence in mice. These pathological events may induce an infiltration of macrophages that are supposed to aid in the clearance of drusen. However, it was suggested that impaired macrophage recruitment may allow the accumulation of complement C5a and IgG, which induces vascular endothelial growth factor (VEGF) production by the RPE and mediates the development of choroidal neovascularization (CNV) (Ambati et al. 2003). This experimental model implicates that impaired macrophage function *in vivo* allows the accretion of proteins associated with

complement activation and immune complexes in areas of basal linear deposits and drusen. Impaired macrophage mobilization would prevent clearance of basal linear deposits, including drusen and a variety of proteins.

This hypothesis is far from proven. Other experiments suggest that macrophages may have a pivotal role; both macrophages and RPE cells express angiogenic cytokines in CNV (Grossniklaus et al. 2002). A role for local, chronic inflammation in the formation of drusen in the ageing eye has been proposed (Anderson et al. 2002, 2004). It is noteworthy, however, that macrophage depletion diminishes lesion size or inhibits experimental CNV in an experimental mouse model, supporting the hypothesis that macrophages may even contribute to the severity of the lesion (Espinosa-Heidmann et al. 2003; Sakurai et al. 2003).

Factors have emerged that suggest a genetic predisposition for ARM, probably including certain constellations of different gene mutations. Bruch's membrane is a stratified extracellular-matrix complex that includes fibulins, which are extracellular-matrix proteins. Mutations in the fibulin 5 gene have been found in 1.7% of patients with ARM (Stone et al. 2004). Recently, a variant in the complement factor gene (CFH) on chromosome 1 was found to be strongly associated with late ARM. The CFH is a key regulator of the complement system and the polymorphism is in a

region of CFH that binds heparin and C-reactive protein (Edwards et al. 2005; Haines et al. 2005; Klein et al. 2005). In addition, the complement factor H, the major inhibitor of the alternative complement pathway, accumulates within drusen and is synthesized by the RPE; multiple HF1 variants were reported occurring at a frequency of 50% in ARM and 29% in controls (Hageman et al. 2005).

To date it seems reasonable to assume that inflammatory and immunological responses operate in the extracellular matrix between the RPE and choroid, although the pathogenetic mechanisms are far from clear.

Choroidal neovascularization (CNV)

Inflammatory response is likely to induce further pathological changes, including vascular alterations. An increased expression of angiogenic growth factors, such as VEGF, are present in the RPE and in the outer nuclear layer of the maculae with ARM (Kvanta et al. 1996; Kliffen et al. 1997). Macrophages, RPE cells and vascular endothelial cells express angiogenic cytokines and, in association with other pathogenetic mechanisms, induce a neovascular response (Grossniklaus et al. 2002).

The CNV generally grows into the inner portion of Bruch's membrane, ultrastructurally recognized as the basal linear deposit, an area into which peroxidized lipids have accumulated (Spaide 2003b; Holtz et al. 2004). The pathogenesis of CNV is ultimately a consequence of a disturbed balance between several pro- and antiangiogenic factors. The extensive literature on angiogenesis is not included in this survey.

Accordingly, intravitreal triamcinolone acetonide was found to inhibit experimental CNV in a laser-treated rat model (Ciulla et al. 2003), and when photodynamic therapy was combined with a triamcinolone injection, favourable results were achieved in human eyes with CNV (Spaide et al. 2005). It was recently reported that C-reactive protein and interleukin 6, markers of inflammation and indicators of the risk of cardiovascular disease, are elevated in neovascular ARM (Seddon et al. 2004, 2005). Furthermore, neovascular ARM seems to be associated with cardiovascular disease (Age-Related Eye Disease Study 2004).

Free radicals

Accumulating evidence indicates that oxidative (free radical) damage is a pathogenetic factor in ageing and has a significant influence on the development of ARM. It has been estimated that approximately 3% of the oxygen used produces reactive oxygen species. Reactive oxygen species can be derived from leakage of electrons from mitochondrial aerobic metabolism, and include superoxide, hydrogen peroxide and singlet oxygen.

Choroidal blood flow far supersedes that required to nourish the neural retina. Its venous blood flow is oxygenated to 90%. In the submacular area, choroidal blood flow is significantly higher than in the periphery (Alm & Bill 1973). Approximately 1% of the oxygen in the blood is extracted from the choroidal circulation, indicating that there is a tremendous excess of oxygen that is never used.

Due to the high blood perfusion rate, the oxygen tension in the retina is very high. Oxidative damage is likely to occur in an environment of extremely high oxygen tension, such as the centre of the macula, which has a continuous and lifelong exposure to radiation (photons). Reactive oxygen species (free radicals) are formed, particularly in response to short-wavelength irradiation. Photoreceptor outer segments are rich in polyunsaturated fatty acids. The outer segments, altered by irradiation, are phagocytosed by the RPE cells, which may become damaged by the engulfed reactive oxygen species. Experiments show that rod outer segments mediate mitochondrial DNA damage and apoptosis in human RPE cells in tissue culture (Jin et al. 2001). This scenario demonstrates the pivotal influence of photoreceptor outer segments on RPE function.

Lipid peroxidation has been defined as 'the oxidative deterioration of polyunsaturated lipids' (i.e. lipids that contain more than double carbon-carbon double bonds). Free radicals deteriorate lysosome function, giving rise to byproducts such as lipofuscin. With age, there is an increasing accumulation of lipofuscin in the RPE cells, featuring ARM. Lipofuscin accumulates in the lysosomes of RPE cells and is associated with several adverse effects on RPE cell function and survival.

A2E (N-retinidene-N-retinylethanolamine) is a major fluorophore of lipofuscin and is generated, at least partly, from transretinal. A2E generates free radicals in response to irradiation, particularly by blue light. The formation of reactive oxygen species will impair the oxygen-driven activity in the mitochondria, the 'power plant' of the cell, by altering its DNA. A2E specifically targets cytochrome oxidase (COX) inhibiting mitochondrial respiration (Schütt et al. 2000; Sparrow & Cai 2001). Mitochondrial changes may, in turn, lead to apoptosis of elderly RPE cells that have become loaded with lipofuscin.

The body has two lines of defence:

- (1) antioxidant enzymes, such as superoxide dismutase, catalase and peroxidase, and
- (2) antioxidant nutrients, such as alpha-tocopherol (vitamin E) and ascorbic acid (vitamin C).

However, with ageing the defensive mechanisms of the body seem to become insufficient. There is a continuous increase in lipofuscin in post-mitotic cells, particularly in the RPE, reflecting the insufficiency of their defence to oxidative damage.

It is reasonable to assume that when the defensive mechanisms become insufficient with increasing age, degenerative changes in RPE cells ultimately occur in response to a lifelong exposure to radiation and reactive oxygen species (Barja 2002). Research on RPE cells in tissue culture has identified several pathogenetic cellular events, such as the accumulation of lipofuscin and other chromophores, which are likely to mediate and aggravate mitochondrial DNA damage (Liang & Godley 2003). Protective effects from a variety of antioxidants have been demonstrated. Antioxidants capture free radicals, thereby to some extent alleviating the chain reaction of deleterious effects on other molecules.

Experimental blue light damage

Animal experiments show that retinal exposure to excessive levels of white light induce apoptotic cell death of photoreceptors and, with a short delay, do the same in RPE cells (Hafezi et al. 1997; Grimm et al.

2001). It has been unequivocally demonstrated that the blue light hazard is mediated through absorption of blue light by rhodopsin.

Accumulating evidence indicates that light exposure triggers photoreceptor apoptosis only in the presence of rhodopsin. The RPE protein RPE65, which is an important determinant for rhodopsin regeneration in mice, is a prerequisite for light damage (Iseli et al. 2002; Wenzel et al. 2005). No light damage could be induced in RPE65-deficient mice deprived of rhodopsin. Light damage occurs only when the retina is supplied with retinoid metabolites such as 11-*cis* retinal, the chromophore of rod and cone opsins, or other toxic byproducts (Grimm et al. 2000a). Repetitive photon absorptions in association with rhodopsin regeneration seem to be required in order to trigger photoreceptor apoptosis. It is conceivable, although not proven, that repetitive light stimuli in a mesopic level of adaptation may make the retina particularly sensitive to light damage.

The photoelectric effect, known from quantum physics, explains many of the biological events induced by short-wavelength irradiation. The high-energy photons in the spectrum of blue light and adjacent UVA radiation have the power to damage the cellular function and structure of photoreceptors and RPE. These photons create reactive oxygen species, which are deleterious to a variety of cellular organelles, particularly the mitochondrial DNA, and ultimately result in apoptotic cell death.

It is well established that the formation of reactive oxygen species increases with decreasing wavelength (Boulton et al. 1993; Rozanowska et al. 1998). On the cellular level, 470–490-nm light was reported to induce oxidant injury in both the inner and outer segments of rod photoreceptors, an event requiring rhodopsin activation (Demontis et al. 2002).

The increased risk of mitochondrial damage induced by blue light has been demonstrated in many experimental models. For example, red light of a certain intensity is insufficient to induce retinal damage, whereas blue light of the same intensity will cause retinal injury. Deep blue light has been described as 50–80 times more efficient at causing photoreceptor

damage than green light (Rapp & Smith 1992). Following exposure to blue light (400–480 nm), photoreceptor apoptosis was induced in the rat, the most pronounced cell death occurring 16 hours after irradiation in the dark. Immunoreactivity for caspase-3 was up-regulated in the outer nuclear layer of the retina and, concurrently, cytochrome C was released from the mitochondria. These events result in apoptotic cell death (Wu et al. 1999, 2002).

Using narrow-band blue (403 nm) and green (550 nm) light, adjusted to the same energy, exposure to blue light was found to severely damage rod photoreceptors, while green light did not (Grimm et al. 2001; Wenzel et al. 2005).

Photoconsumption of oxygen by human ocular lipofuscin increases with decreasing wavelengths of the exciting irradiation, the effects of blue light being much more pronounced than those of red light (Pawlack et al. 2002). Blue light damage is thus likely to be mediated by endogenous chromophores, such as lipofuscin (Boulton et al. 2001). It has been further demonstrated that chloroform-insoluble components (ChNS) of lipofuscin granules significantly increase with ageing, and that ChNS mediate photo-induced oxygen uptake (photogenerating singlet oxygen) with rates that increase with decreasing wavelengths (Rozanowska et al. 2004). Thus, the oxidative damage to RPE cells loaded with lipofuscin is enhanced in response to blue light, a phenomenon that occurs in cells in elderly subjects and in patients with ARM.

Light radiation (near-ultraviolet) was demonstrated to accelerate the formation of lipofuscin fluorophores and ageing of RPE cells in tissue culture (Li et al. 1999). Autofluorescence from lipofuscin can be demonstrated in response to blue light. In addition, exposure of RPE cells in culture to near UV light reduced the proliferation of the cells, accompanied by increased lipofuscin content. In turn, lipofuscin accumulation in RPE cells induced enhanced sensitivity to blue light irradiation (Wihlmark et al. 1997; Nilsson et al. 2003).

Thus, lipofuscin fluorophores seem to play an important role in the blue light hazard phenomenon. The fluorophore A2E mediates blue light-induced

(peak around 430 nm) damage to RPE cells, involving oxidative mechanisms, where DNA is the target of the photodynamic effects (Sparrow & Cai 2001; Sparrow et al. 2002, 2003). A2E targets mitochondria and induces apoptosis (Suter et al. 2000). A2E also acts as an inhibitor of lysosomal degradative functions (Bermann et al. 2001). It is notable that when oxygen was removed from the culture media of human RPE cells in culture, the blue light damage was found to be basically blocked (Sparrow et al. 2002).

In an experimental model, transgenic mice with over-expression of APO B100 and increased LDL cholesterol in the blood were more susceptible to blue light-induced formation of sub-RPE deposits than the controls; thus high-fat diet and blue light exposure aggravate oxidant injury (Espinosa-Heidmann et al. 2004).

As previously mentioned, the formation of lipofuscin in RPE cells requires a normal visual cycle. The absence of retinoid metabolites such as retinal prevents RPE apoptosis (Grimm et al. 2000a; Katz & Redmond 2001). Accordingly, light damage to the retina is dependent on the amount of rhodopsin available for bleaching and RPE65-deficient mice, lacking rhodopsin, are protected against light-induced apoptosis of RPE cells (Grimm et al. 2001).

These results have been explained on the basis of rhodopsin photoreversal: blue light regenerates rhodopsin from its bleaching intermediates and can thus provide increased numbers of bleachable rhodopsin molecules (Grimm et al. 2000b). Blue light promotes the photoisomerization of all-trans-retinal, which leads to the regeneration of rhodopsin and an increase in phototransduction, thus in turn promoting photoreceptor apoptosis (Margrain et al. 2004). This concept was supported by experiments on mutant mice that lack rhodopsin and in these animals no blue light photoreceptor damage could be induced. Accordingly, when both metabolic rhodopsin regeneration and photoreversal bleaching were inhibited in wild-type mice, blue light exposure induced only moderate lesions. Green light had no effect (Grimm et al. 2001).

It should be emphasized, however, that light-induced retinal degeneration is a complex series of events, involving caspase-dependent apoptosis and a

number of caspase-independent pathways to cellular death (Hao et al. 2002; Wenzel et al. 2005).

The dramatic change in ocular transmittance in pseudophakic eyes

The crystalline lens of the young and healthy human eye has a high level of transparency for optic radiation of short wavelengths (400–500 nm). The photochemical class 2 damage or blue light hazard peaks at 430–440 nm. It is noteworthy that there is already an accumulation of lipofuscin in RPE cells during the second and third decades of life (Delori et al. 2001).

There is a progressive increase in absorbance within the blue light spectrum due to colour changes in the crystalline lens; this is attributable to several factors, such as oxidation products of tryptophan and glycosylation of lens proteins (Mellerio 1994). The crystalline lens becomes increasingly yellowish with age and the pigmentation of the lens eventually acts as a protective barrier against blue light (Fig. 5). This ‘normal’ change is associated with a slight decrease in scotopic vision. For example, by the age of 53 years, the scotopic vision of the human eye has decreased by 33% compared with that in childhood. By the age of 75 years, scotopic vision has reduced by 75%. At the same time, the protection provided by the crystalline lens against UV radiation and blue light

has increased to approximately 90%. The crystalline lens absorbs most UVB and UVA radiation up to 390–400 nm.

Blue light retinal damage in pseudophakic eyes

When the cataractous lens is removed and replaced by a clear intraocular lens (IOL), a dramatic increase in the ocular transmittance of radiation occurs. In the aphakic eye (with no IOL) there is almost unlimited transmission of blue light and a portion of the UVA radiation to the retina. A cascade of cellular effects is induced when the short-wavelength radiation strikes the retina.

Due to the increased transmission of radiation to the retina in non-phakic eyes, the stress caused by high-energy photons on photoreceptor and RPE cells is substantially augmented. Extensive laboratory work indicates a manifold of cellular events in response to high-energy radiation, such as increased lipid peroxidation, deterioration of lysosome function and accumulation of lipofuscin with chromophores, such as A2E (Fig. 4A, B).

As previously mentioned, A2E is one of the chromophores in lipofuscin responsible for the blue light sensitivity of RPE. A2E generates singlet oxygen, which, through intermediate products, induces mitochondrial and DNA damage. Thus, the removal of a cataractous lens leaves the RPE vulnerable at an age when its content of blue light-sensitive A2E is high and will continue to increase with the years (Sparrow et al. 2004).

The deleterious effects of short-wavelength irradiation on RPE cells loaded with lipofuscin have been demonstrated. In response to blue light irradiation, RPE cells that did not contain substantial amounts of A2E remained viable, whereas RPE cells that had amassed A2E underwent apoptotic cell death (Sparrow et al. 2004). Thus, A2E is one major mediator of the blue light hazard (peak around 430 nm). In the ageing eye, chloroform-insoluble components (ChNS) of lipofuscin also accumulate and these are particularly apt to enhance the oxidative damage induced by free radicals in response to blue light irradiation (Rozanowska et al. 2004).

Although several other mechanisms producing cellular damage may be operating in the pseudophakic eye,

short-wavelength radiation is in all probability a major factor.

Progression of ARM in pseudophakic eyes

Some clinical reports have suggested that cataract surgery may increase the development or progression to neovascular ARM or geographic atrophy (Pollack et al. 1996, 1997; Chaîne et al. 1998). The Beaver Dam Eye Study (Madison, Wisconsin) indicated that aphakic or pseudophakic eyes at baseline had more than double the odds for ARM progression and for the development of late ARM than phakic eyes (Klein et al. 1998). Similarly, in the Blue Mountains Eye Study (Sydney, Australia), a significant increase in late ARM at 5 years was reported in pseudophakic eyes as compared with phakic eyes (Mitchell et al. 2002).

In a comprehensive analysis of the pooled data from the Beaver Dam Eye Study and the Blue Mountains Eye Study, comprising 6019 participants (11 393 eyes), an increased risk for late ARM was found at 5 years after cataract surgery (Wang et al. 2003). Almost all eyes that developed late-stage ARM during the 5-year period had some early stage ARM lesions at baseline. Late ARM (neovascular ARM or geographic atrophy) had developed in 6.0–7.5% of non-phakic eyes compared with 0.7% of phakic eyes at 5 years after surgery. Neovascular ARM developed in 4.2% of right and 4.1% of left non-phakic eyes over the 5-year period, compared with 0.4% of right and 0.3% of left eyes. After adjustment for gender, smoking and the presence of indistinct drusen and retinal pigment abnormalities at baseline, non-phakic eyes were found to have a considerably higher risk for developing late ARM compared with phakic eyes (odds ratio = 5.7). These results are in line with those of a post-mortem study, in which increased prevalence of disciform and neovascular ARM was found in pseudophakic eyes as compared with age-matched controls (van der Schaft et al. 1994).

There may be other reasons for the increased incidence of late ARM in non-phakic eyes. Cystoid macular oedema (CME), presumably associated with inflammatory changes, is common after

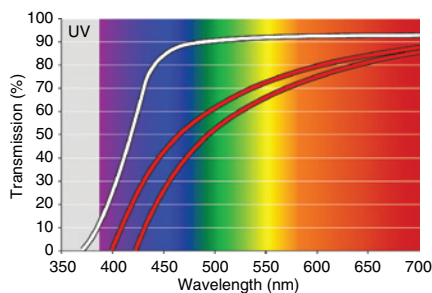


Fig. 5. Transmittance of the human lens as function of age. At 5 years of age, the lens is transparent for blue and violet light and even for some UVA < 400 nm (white line). With increasing age, the absorption of short-wavelength light is augmented. The elderly crystalline lens operates as a ‘yellow’ filter, blocking a considerable fraction of blue light, as indicated by the transmittance from about 50–80 years (red lines).

cataract surgery. The greatest incidence of clinically significant postoperative CME occurs 1–3 months after surgery. In the majority of cases this condition resolves within weeks or months. In approximately 1% of cataract extractions, chronic CME persists for more than 6 months (Dick et al. 2001). Notwithstanding this, the impact of CME on the development of late ARM remains uncertain and ambiguous.

It is reasonable to assume that an increased susceptibility to phototoxic light damage after cataract surgery persists, making the retina more vulnerable to longlasting radiation, particularly in elderly subjects (Pollack et al. 1996).

Putative prophylactic measures

‘Yellow’ intraocular lenses (IOLs)

The IOLs with UV-filter were introduced in the 1980s. Ultraviolet filter IOLs are supposed to confer protection against radiation below 400 nm; for longer wavelengths the transmittance increases substantially compared with that of the normal ageing crystalline lens. However, it was recently reported that a number of traditional IOLs actually transmit more than 10% of UVA radiation between 350 nm and 400 nm (Laube et al. 2004); these high-energy

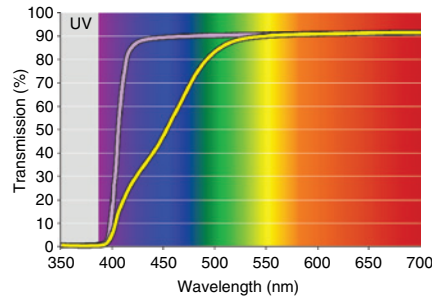


Fig. 7. A traditional UV-absorbing IOL protects the retina from UV radiation (violet line). A ‘yellow’ IOL also protects the retina from violet and blue light (yellow line).

photons have the capacity to induce deleterious cellular effects (Fig. 3).

New types of ‘yellow’ IOLs have been introduced, which have a filtering effect that mimics that of the ageing human lens by attenuating light from wavelengths between 400 nm and 500 nm (Figs 6 and 7). The yellow IOLs provide a better degree of protection against UV radiation and blue light than traditional IOLs that have only UV filtering capabilities (Mainster 2005 & Sparrow 2003).

Experimental data indicate that the yellow filters protect RPE cells that are exposed to blue, green and white light, respectively. Pigmented rabbits were exposed to xenon light; one eye of the animals was protected by a yellow filter and a clear polymethylmethacrylate

(PMMA) lens was placed in front of the fellow eye. The total irradiance of the eyes was equalized by neutral density filters in front of the PMMA material. Electrophysiological recordings showed significantly more damage to both neuroretinal and RPE function in eyes behind the PMMA material than in those behind yellow filters (Nilsson et al. 1990).

Human RPE cells were allowed to accumulate A2E in tissue culture to levels that are comparable to the amounts present *in vivo*. When protected by a yellow IOL, transmission of blue light (peak 430 nm) was attenuated by approximately 50% and apoptotic cell death was reduced by 80% compared with irradiation in the absence of IOL. In contrast, when four different traditional IOLs were tested in the same experimental setting, the reduction of the number of non-viable cells was only 10–20% when exposed to blue light, 40–60% in response to green light (peak 550 nm) and 20–40% in response to white light (390–750 nm). The experiments thus demonstrate that even green and white light may have detrimental effects on A2E-laden RPE cells, such as those in elderly eyes. These adverse effects are alleviated by a yellow IOL. In conclusion, the blue light-absorbing IOL was associated with significant reduction (78–82%) in the death of A2E-laden RPE cells that were exposed to blue, green or white light (Sparrow et al. 2004).

The yellow IOL gives a yellowish hue to the ocular image which, generally, does not seem to be a problem. The yellow IOLs induce a reduction of the scotopic sensitivity (Mainster 2005 & Sparrow 2003). This moderate loss of scotopic vision was found to be of the same magnitude as that of a 53-year-old human lens. Patients with the blue light-blocking IOL exhibit a significant threshold elevation at 410 nm (violet light) and at 450 nm (blue light). However, no significant differences in visual performance were found at 500 nm or 560 nm (green light) between patients implanted with the yellow IOL and those implanted with the clear IOL (Jackson 2005).

The yellow IOLs reduce the optical chromatic aberration by blocking blue light. In addition, there is an enhancement of contrast sensitivity and a reduction of glare (Wolffsohn et al. 2000). These phenomena are

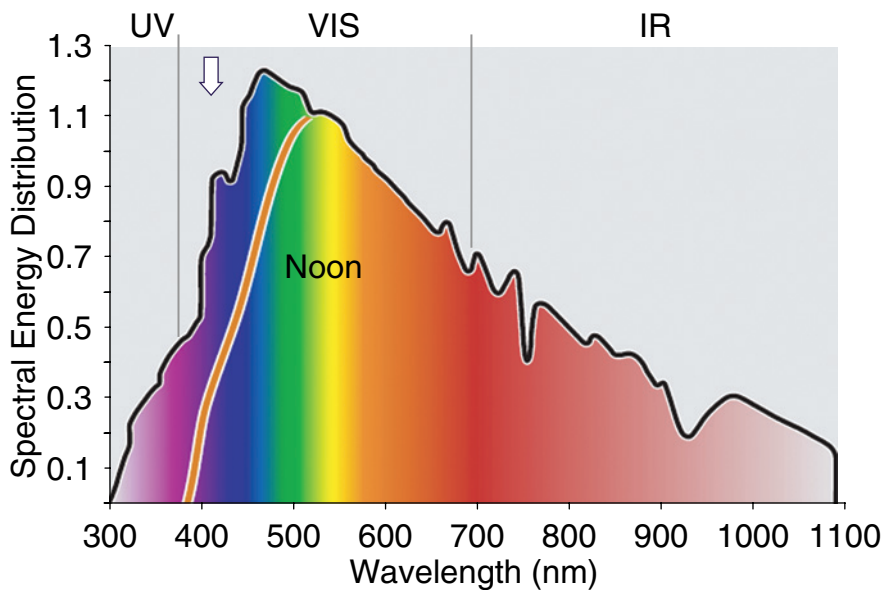


Fig. 6. The spectral energy of sunlight in the aphakic eye. When the crystalline lens is removed, the retina will lose the protection for short-wavelength radiation that is attenuated by the elderly crystalline lens (vertical arrow). A ‘yellow’ IOL protects the retina from high-energy photons by attenuating blue light and absorbing most of the violet (red line).

definitively advantageous for elderly eyes or in subjects with ARM. However, perception of the colour blue is certainly affected. On the other hand, blue cones do not contribute to high visual acuity. Clinical experience indicates that people with a clear IOL in one eye and a yellow IOL in the fellow eye are not disturbed by the slight differences in the images.

Thus, experimental and theoretical data indicate that a yellow IOL is likely to confer protection to retinal cells. The blocking of UVA radiation from the retina is important. Although the indications for the use of yellow IOLs have not been elucidated, it is, from a theoretical point of view, most rational to use a yellow IOL for cataract surgery in patients at risk for ARM and in those with ARM (Margrain et al. 2004; Nilsson 2004; Braunstein & Sparrow 2005). A randomized clinical trial is warranted to assess to what extent yellow IOLs will reduce the risk for or progression of ARM.

Prophylactic treatment with antioxidants

Another approach to prophylactic treatment for ARM is based on the capacity of various antioxidants to alleviate or reduce the detrimental effects of reactive oxygen species in response to radiation and other noxious stimuli. Extensive laboratory investigations have demonstrated the role of oxidative stress and the inhibitory effects of antioxidants on RPE cellular function (Beatty et al. 2000; Sundelin & Nilsson 2001).

The Age-related Eye Disease Study (AREDS) (2001), a randomized, placebo-controlled clinical trial, comprising 3640 participants, using supplementation with high-dose antioxidants (average follow-up 6.5 years) showed a significant reduction in rates of at least moderate visual loss in certain categories of ARM. Participants were randomized to daily antioxidants (vitamin C 500 mg, vitamin E 400 IU, β -carotene 15 mg, zinc 80 mg and copper 2 mg) or placebo. Subjects with extensive intermediate size drusen, at least one large druse, non-central geographic atrophy in one or both eyes, or advanced ARM in one eye had a statistically significant odds

reduction for the development of advanced (late) ARM. At 5 years, the estimated probability of progression to advanced ARM (neovascular ARM, geographic atrophy) was 28% for those assigned to placebo, and 20% for those assigned to antioxidants plus zinc.

There was no difference in mortality in the various subgroups treated with antioxidants or placebo (Age-related Eye Disease Study 2001). Further analyses indicated that participants randomly assigned to receive zinc (zinc alone or antioxidants plus zinc) had a lower mortality rate than those not taking zinc (Age-related Eye Disease Study 2004).

It is known from earlier studies that high doses of β -carotene may increase the risk of lung cancer in smokers (Omenn et al. 1996; US Preventive Services Task Force 2003). Therefore, β -carotene was excluded from the antioxidant regimen for smokers in the AREDS. A meta-analysis of antioxidant supplements for prevention of gastrointestinal cancers revealed that certain combinations of vitamins, such as β -carotene and vitamin A, increased mortality (Bjelakovic et al. 2004). However, trials in which vitamin C was given separately or in different combinations with β -carotene, vitamin A or vitamin E showed no significant effect on gastrointestinal cancers or mortality.

It is conceivable that very high doses of a solitary antioxidant can induce adverse effects. One meta-analysis suggested that high-dose vitamin E supplements may increase all-cause mortality (Miller et al. 2005). Notwithstanding, the AREDS formulation had a 14% reduction in mortality risk after an average of 6.5 years (Chew & Clemons 2005).

The Health Professionals Follow-up Study (Leitzmann et al. 2003) found that men who consumed more than 100 mg/day of supplemental zinc had a higher risk of advanced prostate cancer, but not of organ-confined cancers. However, a later study concluded that 80 mg/day of supplemental zinc does not increase the risk of prostate cancer (Jarrard 2005).

The putative role of nutritional factors (e.g. a low antioxidant intake) in the incidence of disease has been approached. For example, in patients with low levels of antioxidant intake,

the prevalence rate of neovascular ARM was reported to be about twice as high as that in subjects with high levels of intake (Snellen et al. 2002). A protective role for the intake of fruit and fish has been suggested (Seddon et al. 2003; Cho et al. 2004).

The US National Eye Institute concluded that people at risk of developing advanced ARM lowered this risk by about 25% when treated according to the AREDS. It has been estimated that if people in the USA at risk of advanced ARM receive AREDS-recommended supplements, more than 300 000 of them would avoid developing advanced ARM during the next 5 years (Age-related Eye Disease Study 2003). Accordingly, the American Academy of Ophthalmology has recommended the AREDS formula for antioxidant supplementation.

Notwithstanding, further research is warranted to elucidate the complicated balance between oxidative damage and the effects of antioxidant and nutritional prophylaxis.

References

- Age-related Eye Disease Study (AREDS) (2003): Potential public health impact of Age-related Eye Disease Study results. AREDS Report 11. *Arch Ophthalmol* **121**: 1621–1624.
- Age-related Eye Disease Study (AREDS) (2004): Associations of mortality with ocular disorders and intervention of high-dose antioxidants and zinc in the Age-related Eye Disease Study. AREDS Report 13. *Arch Ophthalmol* **122**: 716–726.
- Age-related Eye Disease Study (AREDS) (2001): A randomized, placebo-controlled, clinical trial of high-dose supplementation with vitamins C and E, beta carotene and zinc for age-related macular degeneration and vision loss. AREDS Report 8. *Arch Ophthalmol* **119**: 1417–1436.
- Algvere PV & Seregard S (2002): Age-related maculopathy: pathogenetic features and new treatment modalities. *Acta Ophthalmol Scand* **80**: 136–143.
- Alm A & Bill A (1973): Ocular and optic nerve blood flow at normal and increased intraocular pressures in monkeys (*Macaca irus*): a study with radioactively labelled microspheres including flow determination of brain and some other tissues. *Exp Eye Res* **15**: 15–29.
- Ambati J, Anand A, Fernandez S et al. (2003): An animal model of age-related macular degeneration in senescent Ccl-2- or Ccr-2-deficient mice. *Nature Med* **9**: 1390–1397.
- Anderson DH, Mullins RF, Hageman GS & Johnson LV (2002): A role for local

- inflammation in the formation of drusen in the ageing eye. *Am J Ophthalmol* **134**: 411–431.
- Anderson DH, Talaga KC, Rivest AJ, Barron E, Hageman GS & Johnson LV (2004): Characterization of beta amyloid assemblies in drusen: the deposits associated with ageing and age-related macular degeneration. *Exp Eye Res* **78**: 243–256.
- Barja G (2002): Endogenous oxidative stress: relationship to ageing, longevity and caloric restriction. *Ageing Res Rev* **1**: 397–411.
- Beatty S, Koh H-H, Phil M, Henson D & Boulton M (2000): The role of oxidative stress in the pathogenesis of age-related macular degeneration. *Surv Ophthalmol* **45**: 115–134.
- Benson H (1991): University Physics. New York: Wiley and Sons, Inc.; 820–826.
- Berendschot TTJM, Willems-Assink JJM, Basiaanse M, de Jong PTVM & van Norren D (2002): Macular pigment and melanin in age-related maculopathy in a general population. *Invest Ophthalmol Vis Sci* **43**: 1928–1932.
- Bermann M, Schütt F, Holz FG & Kopitz J (2001): Does A2E, a retinoid component of lipofuscin and inhibitor of lysosomal degradative functions, directly affect the activity of lysosomal hydrolases? *Exp Eye Res* **72**: 191–195.
- Bindewald A, Schmitz-Valckenberg S, Jorzik JJ et al. (2005): Classification of abnormal fundus autofluorescence patterns in the junctional zone of geographic atrophy in patients with age-related macular degeneration. *Br J Ophthalmol* **89**: 874–878.
- Bjelakovic G, Nikolova D, Simonetti RG & Gluud C (2004): Antioxidant supplements for prevention of gastrointestinal cancers: a systematic review and meta-analysis. *Lancet* **364**: 1219–1228.
- Boettner EA & Wolter JR (1962): Transmission of the ocular media. *Invest Ophthalmol* **1**: 776–783.
- Boulton M, Dontsov A, Jarvisevans J, Ostrovsky M & Svistunenko D (1993): Lipofuscin is a photoinducible free-radical generator. *J Photochem Photobiol B* **19**: 201–204.
- Boulton M, Rozanowska M & Rozanowska B (2001): Retinal photodamage. *J Photochem Photobiol B* **64**: 144–161.
- Braunstein RE & Sparrow JR (2005): A blue-blocking intraocular lens should be used in cataract surgery. *Arch Ophthalmol* **123**: 547–549.
- Chaine G, Hullo A, Sahel J et al (1998): France-DMLA Study Group. Case-control study of risk factors for age-related macular degeneration. *Br J Ophthalmol* **82**: 996–1002.
- Chew EY & Clemons T (2005): Vitamin E and Age-related Eye Disease Study supplementation for age-related macular degeneration. [Editorial.] *Arch Ophthalmol* **123**: 395–396.
- Cho E, Seddon JM, Rosner B, Willett WC & Hankinson SE (2004): Prospective study of intake of fruits, vegetables, vitamins and carotenoids and risk of age-related maculopathy. *Arch Ophthalmol* **122**: 883–892.
- Cicerone CM (1976): Cones survive rods in the light-damaged eye of the albino rat. *Science* **194**: 1183–1185.
- Ciulla TA, Criswell MH, Danis RP et al. (2003): Choroidal neovascular membrane inhibition in a laser-treated rat model with intraocular sustained release triamcinolone acetonide microimplants. *Br J Ophthalmol* **87**: 1032–1037.
- Ciulla TA & Hammond BR (2004): Macular pigment density and ageing, assessed in the normal elderly and those with cataracts and age-related macular degeneration. *Am J Ophthalmol* **138**: 582–587.
- Cousins SW, Espinosa-Heidmann DG & Csaky KG (2004): Monocyte activation in patients with age-related macular degeneration. *Arch Ophthalmol* **122**: 1013–1018.
- Cruikshanks KJ, Klein R & Klein BR (1993): Sunlight and age-related macular degeneration. The Beaver Dam Eye Study. *Arch Ophthalmol* **111**: 514–518.
- Cruikshanks KJ, Klein R, Klein BE & Nondahl DM (2001): Sunlight and the 5-year incidence of early age-related maculopathy. The Beaver Dam Eye Study. *Arch Ophthalmol* **119**: 246–250.
- Curcio CA, Medeiros NE & Millican CL (1993): Photoreceptor loss in age-related macular degeneration. *Invest Ophthalmol Vis Sci* **37**: 1236–1249.
- Curcio CA & Millican CL (1999): Basal linear deposit and large drusen are specific for early age-related maculopathy. *Arch Ophthalmol* **117**: 329–339.
- Curcio CA, Owsley C & Jackson GR (2000): Spare the rods, save the cones in ageing and age-related maculopathy. *Invest Ophthalmol Vis Sci* **41**: 2015–2018.
- Czaky K, Baffi J, Chan C-C & Byrnes GA (2004): Clinicopathologic correlation of progressive fibrovascular proliferation associated with occult choroidal neovascularization in age-related macular degeneration. *Arch Ophthalmol* **122**: 650–652.
- Davies NP & Morland AB (2004): Macular pigments: their characteristics and putative role. *Prog Retin Eye Res* **23**: 533–559.
- Davies S, Elliott MH, Floor E (2001): Photocytotoxicity of lipofuscin in human retinal pigment epithelial cells. *Free Radic Biol Med* **31**: 256–265.
- Delori FC, Goger DG & Dorey CK (2001): Age-related accumulation and spatial distribution of lipofuscin in RPE of normal subjects. *Invest Ophthalmol Vis Sci* **42**: 1855–1866.
- Demontis GC, Longoni B & Marchiafava PL (2002): Molecular steps in light-induced oxidative damage to retinal rods. *Invest Ophthalmol Vis Sci* **43**: 2421–2427.
- Dick JSB, Jampol LM & Haller JA (2001): Macular oedema. In: Ryan SJ (ed). *Retina*. Vol. 2, 3rd edn. St. Louis, Missouri: Mosby; 987–981.
- Edwards AO, Ritter R, Abel KJ, Manning A, Panhuysen C & Farrer LA (2005): Complement factor H polymorphism and age-related macular degeneration. *Science* **308**: 421–424.
- Eldred GE (1998): Lipofuscin and other lysosomal storage deposits in the retinal pigment epithelium. In: Marmor MF & Wolfensberger TJ (eds). *The Retinal Pigment Epithelium: Function and Disease*. New York: Oxford University Press; 651–668.
- Espinosa-Heidmann DG, Sall J & Hernandez Cousins SW (2004): Basal laminar deposit formation in APO B100 transgenic mice: complex interactions between dietary fat, blue light and vitamin E. *Invest Ophthalmol Vis Sci* **45**: 260–266.
- Espinosa-Heidmann DG, Suner IJ, Hernandez EP, Monroy D, Czaky KG & Cousins SW (2003): Macrophage depletion diminishes lesion size and severity in experimental choroidal neovascularization. *Invest Ophthalmol Vis Sci* **44**: 3586–3592.
- Ethen CM, Feng X, Olsen TW & Ferrington DA (2005): Declines in arrestin and rhodopsin in the macula with progression of age-related macular degeneration. *Invest Ophthalmol Vis Sci* **46**: 769–775.
- Feeney-Burns L, Berman ER & Rothman H (1980): Lipofuscin of human retinal pigment epithelium. *Am J Ophthalmol* **90**: 783–791.
- Gaillard ER, Atherton SJ, Eldred G & Dillon J (1995): Photophysical studies on human retinal lipofuscin. *Photochem Photobiol* **61**: 448–453.
- Gao H & Hollyfield JG (1992): Ageing of the human retina. Differential loss of neurons and retinal pigment epithelial cells. *Invest Ophthalmol Vis Sci* **33**: 1–17.
- Gellerman W, Ermakov IV, Ermakova MR, McClane RW, Zhao DY, Bernstein PS (2002): In vivo resonant Raman measurement of macular carotenoid pigments in the young and the ageing human retina. *J Opt Soc Am A* **19**: 1172–1186.
- Green WR & Enger C (1993): Age-related macular degeneration: histopathological studies. *Ophthalmology* **100**: 1519–1535.
- Grimm C, Remé CE, Rol PO et al. (2000b): Blue light's effects on rhodopsin: photoreversal of bleaching in living rat eyes. *Invest Ophthalmol Vis Sci* **41**: 3984–3990.
- Grimm G, Wentzel A, Hafezi F, Yu S, Redmond TM & Remé CE (2000a): Protection of RPE65-deficient mice identifies rhodopsin as a mediator of light-induced retinal degeneration. *Nat Genet* **25**: 63–66.
- Grimm C, Wenzel A, Williams TP, Rol PO, Hafezi F & Remé CE (2001): Rhodopsin-mediated blue light damage to the rat retina: effect of photoreversal bleaching. *Invest Ophthalmol Vis Sci* **42**: 497–505.
- Grossniklaus HE, Ling JX, Wallace TM et al. (2002): Macrophage and retinal pigment epithelium expression of angiogenic cytokines in choroidal neovascularization. *Mol Vis* **8**: 199–126.
- Guo L, Hussain AA, Limb A & Marshall J (1999): Age-dependant variation in metalloproteinase activity of isolated human Bruch's membrane and choroids. *Invest Ophthalmol Vis Sci* **40**: 2676–2682.
- Hafezi F, Marti A, Munz K & Remé CE (1997): Light-induced apoptosis: differential

- timing in the retina and pigment epithelium. *Exp Eye Res* **64**: 963–970.
- Hageman GS, Anderson DH, Johnson LV et al. (2005): A common haplotype in the complement regulatory gene factor H (HF1/CFH) predisposes individuals to age-related macular degeneration. *Proc Natl Acad Sci U S A* **102**: 7227–7232.
- Hageman GS, Luthert PJ, Victor-Chong NH, Johnson LV, Anderson DH & Mullins RF (2001): An integrated hypothesis that considers drusen as biomarkers of immunomediated processes at the RPE–Bruch’s membranes interface in ageing and age-related macular degeneration. *Prog Retin Eye Res* **20**: 705–732.
- Haines JL, Hauser MA, Schmidt S et al. (2005): Complement factor H variant increases the risk of age-related macular degeneration. *Science* **308**: 419–421.
- Ham WT, Ruffolo JJ, Mueller HA, Clarke AM & Moon ME (1978): Histologic analysis of photochemical lesions produced in rhesus retina by short-wavelength light. *Invest Ophthalmol Vis Sci* **17**: 1029–1035.
- Hao WS, Wentzel A, Obin MS et al. (2002): Evidence for two apoptotic pathways in light-induced retinal degeneration. *Nature Genet* **32**: 254–260.
- Holz FG, Bellman C, Staudt S, Schütt F & Vöcker HE (2001): Fundus autofluorescence and development of geographic atrophy in age-related macular degeneration. *42*: 1051–1056.
- Holz FG, Pauleikhoff D, Klein R & Bird AC (2004b): Pathogenesis of lesions in late age-related macular disease. *Am J Ophthalmol* **137**: 504–510.
- Holz FG, Paulenikhoff D, Spaide RF & Bird AC (2004a): Age-Related Macular Degeneration. Berlin/Heidelberg/New York: Springer-Verlag; 34–35.
- Iseli H-P, Wentzel A, Hafezi F, Remé CE & Grimm C (2002): Light damage susceptibility and RPE65 in rats. *Exp Eye Res* **75**: 407–413.
- Jackson G (2005): Scotopic vision may be affected by blue-blocking lens. [Ophthalmology Times.] www.ophtalmologytimes.com. [Accessed 1 July 2005.]
- Jahn C, Wüstemeyer H, Brinkman C et al. (2005): Macular pigment density in age-related maculopathy. *Graefes Arch Clin Exp Ophthalmol* **243**: 222–227.
- Jarrard DF (2005): Does zinc supplementation increase the risk of prostate cancer? *Arch Ophthalmol* **123**: 102–103.
- Jin G-F, Hurst JS & Godley BF (2001): Rod outer segments mediate mitochondrial DNA damage and apoptosis in human retinal pigment epithelium. *Curr Eye Res* **23**: 11–19.
- Johnson PT, Lewis GP, Talaga KC, Brown MH, Kappel PJ, Fisher SK, Anderson DH & Johnson LV (2003): Drusen-associated degeneration in the retina. *Invest Ophthalmol Vis Sci* **44**: 4481–4488.
- Katz ML & Redmond TM (2001): Effect of RPE65 knockout on accumulation of lipofuscin fluorophores in the retinal pigment epithelium. *Invest Ophthalmol Vis Sci* **42**: 3023–3030.
- Kilbride PE, Alexander KR, Fishman M & Fishman GA (1989): Human macular pigment assessed by imaging fundus reflectometry. *Vision Res* **29**: 663–674.
- Klein R, Klein BE, Jensen SC & Cruickshanks KJ (1998): The relationship of ocular factors to the incidence and progression of age-related maculopathy. *Arch Ophthalmol* **116**: 506–513.
- Klein RJ, Zeiss C, Chew EY et al. (2005): Complement factor H polymorphism in age-related macular degeneration. *Science* **308**: 385–389.
- Kliffen M, Sharma HS, Mooy CM, Kerkliet S & de Jong PTVM (1997): Increased expression of angiogenic growth factors in age-related maculopathy. *Br J Ophthalmol* **81**: 154–162.
- Krinsky NI, Landrum JT & Bone RA (2003): Biological role of the protective effect of lutein and zeaxanthin in the eye. *Annu Rev Nutr* **23**: 171–201.
- Kuwabara T & Funahashi M (1976): Light effect on the synaptic organ of the rat. *Invest Ophthalmol* **15**: 407–411.
- Kvanta A, Algvare PV, Berglin L & Seregard S (1996): Subfoveal fibrovascular membranes in age-related macular degeneration express vascular endothelial growth factor. *Invest Ophthalmol Vis Sci* **37**: 1929–1934.
- Laube T, Apel H & Koch H-R (2004): Ultraviolet radiation absorption of intraocular lenses. *Ophthalmology* **111**: 880–885.
- Leitzmann MF, Stampfer MJ, Wu K, Colditz GA, Willet WC & Giovannucci EL (2003): Zinc supplement use and the risk of prostate cancer. *J Natl Cancer Inst* **95**: 1004–1007.
- Li W, Yanoff M, Li Y & He Z (1999): Artificial senescence of bovine retinal pigment epithelial cells induced by near-ultraviolet in vitro. *Mech Ageing Dev* **110**: 137–155.
- Liang FQ & Godley BF (2003): Oxidative stress-induced mitochondrial DNA damage in human retinal pigment epithelial cells: a possible mechanism for RPE ageing and age-related macular degeneration. *Exp Eye Res* **76**: 397–403.
- Mainster MA (2005): Intraocular lenses should block UV radiation and violet but not blue light. *Arch Ophthalmol* **123**: 550–555.
- Mainster MA & Sparrow JR (2003): How much blue light should an IOL transmit? *Br J Ophthalmol* **89**: 1523–1529.
- Margrain TH, Boulton M, Marshall J et al. (2004): Do blue light filters confer protection against age-related macular degeneration? *Prog Retin Eye Res* **23**: 523–531.
- Marshall J (1985): Radiation and the ageing eye. *Ophthalmic Physiol Opt* **5**: 241–263.
- Marshall J (1987): The ageing retina: physiology or pathology. *Eye* **1**: 282–295.
- Mellerio J (1994): Light effects on the retina. In: Albert DM & Jakobiec FA (eds). *Principles and Practice of Ophthalmology, Basic Sciences*. Philadelphia: Saunders; 1326–1345.
- Miller ER, Pastor-Barriuso R, Dalal D et al. (2005): Meta-analysis: high-dose vitamin E supplementation may increase all-cause mortality. *Ann Intern Med* **142**: 37–46.
- Mitchell P, Wang JJ, Foran S & Smith W (2002): Five-year incidence of age-related maculopathy lesions. The Blue Mountain Eye Study. *Ophthalmology* **109**: 1092–1097.
- Nilsson SE (2004): Are there advantages in implanting a yellow IOL to reduce the risk of AMD? *Acta Ophthalmol Scand* **82**: 123–125.
- Nilsson SE, Sundelin SP, Wihlmark U & Brunk UT (2003): Ageing of cultured retinal pigment epithelial cells: oxidative reactions, lipofuscin formation and blue light damage. *Doc Ophthalmol* **106**: 13–16.
- Nilsson SEG, Textorius O, Andersson BE & Swenson B (1990): Does a blue light absorbing IOL material protect the neuro-retina and pigment epithelium better than currently used materials? *Lasers Light Ophthalmol* **3**: 1–10.
- Noell WK, Walker W, Kang B & Berman S (1966): Retinal damage by visible light. *Invest Ophthalmol* **5**: 450–473.
- O’Steen WK & Anderson KV (1974): Photoreceptor degeneration in albino rats: dependency on age. *Invest Ophthalmol* **13**: 334–339.
- Omenn GS, Goodman GE, Thornquist MD et al. (1996): Effects of a combination of beta carotene and vitamin A on lung cancer and cardiovascular disease. *N Engl J Med* **334**: 1150–1155.
- Organisciak DT & Winkler BS (1994): Retinal light damage: practical and theoretical considerations. *Prog Retinal Eye Res* **13**: 1–29.
- Pauleikhoff D, Harper CA, Marshall J & Bird AC (1990): Ageing changes in Bruch’s membrane: a histochemical and morphological study. *Ophthalmology* **97**: 171–178.
- Pawlack A, Rozanowska M, Zareba M et al. (2002): Action spectra for the photoconsumption of oxygen by human ocular lipofuscin and lipofuscin extracts. *Arch Biochem Biophys* **403**: 59–62.
- Pollack A, Marcovich A, Bukelman A & Oliver M (1996): Age-related macular degeneration after extracapsular cataract extraction with intraocular lens implantation. *Ophthalmology* **103**: 1546–1554.
- Pollack A, Marcovich A, Bukelman A, Zalish M, Oliver M (1997): Development of exudative age-related macular degeneration after cataract surgery. *Eye* **11**: 523–530.
- Rapp LM & Smith SC (1992): Morphologic comparisons between rhodopsin-mediated and short-wavelength classes of retinal light damage. *Invest Ophthalmol Vis Sci* **33**: 3367–3377.
- Rozanowska M, Pawlak A, Rozanowski B et al. (2004): Age-related changes in the photo-reactivity of retinal lipofuscin granules: role of chloroform-insoluble components. *Invest Ophthalmol Vis Sci* **45**: 1052–1060.
- Rozanowska M, Wessels J, Boulton M et al. (1998): Blue light induced singlet oxygen generation by retinal lipofuscin in non-polar media. *Free Radic Biol Med* **24**: 1107–1112.

- Sakurai E, Anand A, Ambati BK, van Rooijen N & Ambati J (2003): Macrophage depletion inhibits experimental choroidal neovascularization. *Invest Ophthalmol Vis Sci* **44**: 3578–3585.
- van der Schaft TL, Mooy CM, de Bruijn WC et al. (1994): Increased prevalence of disciform macular degeneration after cataract extraction with implantation of an intraocular lens. *Br J Ophthalmol* **78**: 441–445.
- Schmitz-Valckenberg S, Bültmann S, Dreyhaupt J et al. (2004): Fundus autofluorescence and fundus perimetry in the junctional zone of geographic atrophy in patients with age-related macular degeneration. *Invest Ophthalmol Vis Sci* **45**: 4470–4476.
- Schütt F, Bergmann M, Holz FG & Kopitz J (2002): Isolation of intact lysosomes from human RPE cells and effects of A2E on the integrity of the lysosomal and other cellular membranes. *Graefes Arch Clin Exp Ophthalmol* **240**: 983–988.
- Schütt F, Davies S, Kopitz J, Holz FG & Boulton ME (2000): Photodamage to human RPE cells by A2E, a retinoid component of lipofuscin. *Invest Ophthalmol Vis Sci* **41**: 2303–2308.
- Seddon JM, Cote J & Rosner B (2003): Progression of age-related macular degeneration. Association with dietary fat, trans-unsaturated fat, nuts and fish intake. *Arch Ophthalmol* **121**: 1728–1737.
- Seddon JM, Gensler G, Milton RC, Klein ML & Rifai N (2004): Association between C-reactive protein and age-related macular degeneration. *JAMA* **291**: 704–710.
- Seddon JM, George S, Rosner B & Rifai M (2005): Progression of age-related macular degeneration. Prospective assessment of C-reactive protein, interleukin 6 and other cardiovascular biomarkers. *Arch Ophthalmol* **123**: 774–782.
- Seregard S, Algvere PV & Berglin L (1994): Immunochemical characterization of surgically removed subfoveal fibrovascular membranes. *Graefes Arch Clin Exp Ophthalmol* **232**: 325–329.
- Snellen ELM, Verbeek ALM, van de Hoogen GWP, Cruysberg JRM, Hoyng CB (2002): Neovascular age-related macular degeneration and its relationship to antioxidant intake. *Acta Ophthalmol Scand* **80**: 368–371.
- Spaide RF (2003b): Choroidal neovascularization in age-related macular degeneration – what is the cause? *Retina* **23**: 595–614.
- Spaide RF (2003a): Fundus autofluorescence and age-related macular degeneration. *Ophthalmology* **110**: 392–399.
- Spaide RF, Sorensen J & Maranan L (2005): Photodynamic therapy with verteporfin combined with intravitreal injection of triamcinolone acetonide for choroidal neovascularization. *Ophthalmology* **112**: 301–304.
- Sparrow JR & Cai B (2001): Blue light-induced apoptosis of A2E-containing RPE: involvement of caspase-3 and protection by Bcl-2. *Invest Ophthalmol Vis Sci* **42**: 1356–1362.
- Sparrow JR, Miller AS & Zhou J (2004): Blue light-absorbing intraocular lens and retinal pigment epithelium in vitro. *J Cataract Refract Surg* **30**: 873–878.
- Sparrow JR, Zhou J, Ben-Shabat S et al. (2002): Involvement of oxidative mechanisms in blue light-induced damage to A2E-laden RPE. *Invest Ophthalmol Vis Sci* **43**: 1222–1227.
- Sparrow JR, Zhou J & Cai B (2003): DNA is a target of the photodynamic effects elicited in A2E-laden RPE by blue light illumination. *Invest Ophthalmol Vis Sci* **44**: 2245–2251.
- Sperling HG & Johnson C (1980): Differential spectral photic damage to primate cones. *Vision Res* **20**: 1117–1125.
- Spraul CW, Lang GE, Grossniklaus HE, Lang GK (1999): Histologic and morphometric analysis of the choroid, Bruch's membrane, and retinal pigment epithelium in post-mortem eyes with age-related macular degeneration and histologic examination of surgically excised choroidal neovascular membranes. *Surv Ophthalmol* **44** Suppl 1: 10–32.
- Starita C, Hussain AA, Patmore A & Marshall J (1997): Localization of the site of major resistance to fluid transport in Bruch's membrane. *Invest Ophthalmol Vis Sci* **38**: 762–767.
- Stone EM, Braun TA, Russel SR et al. (2004): Missense variations in the fibulin 5 gene and age-related macular degeneration. *New Engl J Med* **351**: 346–353.
- Sundelin SP & Nilsson SEG (2001): Lipofuscin-formation in retinal pigment epithelial cells is reduced by antioxidants. *Free Radic Biol Med* **31**: 217–225.
- Suter M, Remé C, Grimm C et al. (2000): Age-related macular degeneration. The lipofuscin component N-retinyl-N-retinylidene ethanohamine detaches proapoptotic proteins from mitochondria and induces apoptosis in mammalian retinal pigment epithelial cells. *J Biol Chem* **275**: 39625–39630.
- Terman A, Dalen H, Eaton JW, Neuzil J & Brunk UT (2004): Ageing of cardiac myocytes in culture: oxidative stress, lipofuscin accumulation and mitochondrial turnover. *Ann N Y Acad Sci* **1019**: 70–77.
- Thornton J, Edwards R, Mitchell P, Harrison RA, Buchan I & Kelly SP (2005): Smoking and age-related macular degeneration: a review of association. *Eye* **19**: 935–944.
- US Preventive Services Task Force (2003): Routine vitamin supplementation to prevent cancer and cardiovascular disease: recommendations and rationale. *Ann Intern Med* **139**: 51–55.
- Wang JJ, Klein R, Smith W et al. (2003): Cataract surgery and the 5-year incidence of late-stage age-related maculopathy. Pooled findings from the Beaver Dam and Blue Mountain Eye Studies. *Ophthalmology* **110**: 1960–1967.
- Wenzel A, Grimm C, Samardzija M & Remé CE (2005): Molecular mechanisms of light-induced photoreceptor apoptosis and neuroprotection for retinal degeneration. *Prog Retin Eye Res* **24**: 275–306.
- Wihlmark U, Wrigstad A, Roberg K, Nilsson SEG & Brunk UT (1997): Lipofuscin accumulation in cultured retinal pigment epithelial cells causes enhanced sensitivity to blue light irradiation. *Free Radic Biol Med* **22**: 1229–1234.
- Wolffsohn JS, Cochrane AL, Khoo H, Yoshimitsu Y & Wu S (2000): Contrast is enhanced by yellow lenses because of selective reduction of short-wavelength light. *Optom Vis Sci* **77**: 73–81.
- Wu J, Gorman A, Zhou X, Sandra C & Chen E (2002): Involvement of Caspase-3 in photoreceptor cell apoptosis induced by in vivo blue light exposure. *Invest Ophthalmol Vis Sci* **43**: 3349–3354.
- Wu J, Seregard S, Spångberg B, Oskarsson M & Chen E (1999): Blue light induced apoptosis in rat retina. *Eye* **13**: 577–583.

Received on August 30th, 2005.
Accepted on October 12th, 2005.

Correspondence:
Professor Peep V. Algvere MD
St Erik's Eye Hospital
Polhemsgatan 50
SE-112 82 Stockholm
Sweden
Tel: + 46 8 672 3365
Fax: + 46 8 652 1316
Email: peep.algvere@sankterik.se