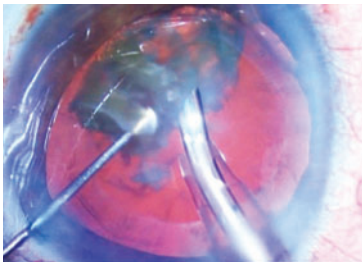


Surgery

LASER CATARACT EASING COMPLEX CASES TO ROUTINE



ALMOST A DECADE after the first femtosecond laser for cataract surgery became commercially available, laser cataract surgery continues to have a limited role in clinical practice, some surgeons may surmise. An international panel of surgeons experienced with laser cataract surgery share their clinical perspectives with the aims of learning from each other and identifying directions for new research.

(See story on page 11 : Insights)

Practice Management

WHEN PRIVATE EQUITY SEEKS YOUR MEDICAL PRACTICE

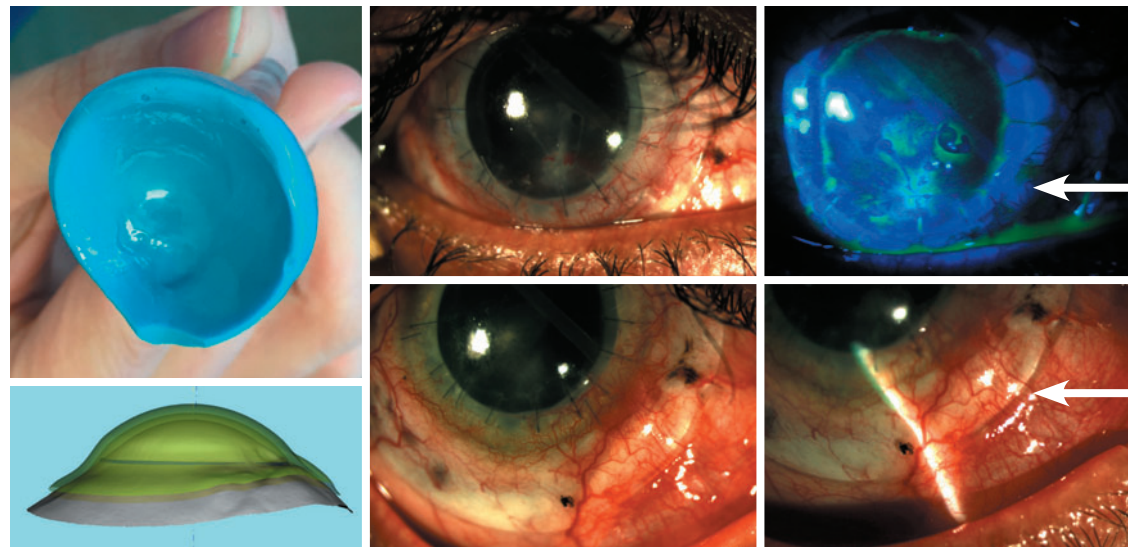
OPHTHALMOLOGISTS face difficult decisions when approached by private equity firms, and selling to these firms has both advantages and disadvantages, according to Ruth D. Williams, MD. About 26% of ophthalmologists are in solo practices, making them attractive targets for such investors.

(See story on page 33 : Private equity)

► OphthalmologyTimes.com

Dry eye strategies from lab to clinic

Management evolves from nasal neurostimulation, prosthetic replacement of ocular surface ecosystem



IN VIEW: Images of the right cornea in a young monocular male who lost his fellow eye in a chemical injury and developed exposure, corneal scarring, and glaucoma in the right eye that required a tube shunt. He had a penetrating graft, but had inferior exposure, epitheliopathy, and haze in the inferior cornea (upper panel). After being fit with a molded scleral lens (EyePrintPRO), the patient's cornea surface, stromal haze, and vision improved (lower panel). Far left, the mold of the cornea. (Images courtesy of Stephen C. Pflugfelder, MD)

By Nancy Groves;
Reviewed by Stephen C. Pflugfelder, MD

NEW APPROACHES with novel devices and technologies for dry eye disease continue to flow from laboratory to ophthalmic practice, radically changing the management or conceal of ocular surface disorders, said Stephen C. Pflugfelder, MD.

Consider how scleral lenses have revolutionized the therapy of cornea and ocular surface diseases and improved corneal transplant outcomes, with new solutions continuing to emerge, said Dr. Pflugfelder, professor and holder of the James and Margaret Elkins Chair in Ophthalmology, Baylor College of Medicine, Houston.

Due largely to the pioneering work of the late Perry Rosenthal, MD, in the 1990s, scleral lens technology was modernized to create seamless inner and outer lens surfaces as well as optimize the corneal vault and maintain a fluid-filled reservoir.

(Continues on page 24 : Ocular surface)



STEPS TO SELF-HELP

14 habits of highly successful
Ophthalmology Times readers **PAGE 7**



See the Passion in Each Patient.

Keep life in sight.

Learn
more about
TECNIS® IOLs
at TecnisIOL.com



Not actual patients.

INDICATIONS AND IMPORTANT SAFETY INFORMATION

Rx Only

ATTENTION: Reference the Directions for Use for a complete listing of Indications and Important Safety Information. **INDICATIONS:** The TECNIS® 1-Piece Lens is indicated for the visual correction of aphakia in adult patients in whom a cataractous lens has been removed by extracapsular cataract extraction. These devices are intended to be placed in the capsular bag. **WARNINGS:** Physicians considering lens implantation should weigh the potential risk/benefit ratio for any conditions described in the TECNIS® 1-Piece IOL Directions for Use that could increase complications or impact patient outcomes. The TECNIS® 1-Piece IOL should not be placed in the ciliary sulcus. **PRECAUTIONS:** Do not reuse, resterilize, or autoclave. **ADVERSE EVENTS:** In 3.3% of patients, reported adverse events of cataract surgery with the 1-Piece IOL included macular edema. Other reported reactions occurring in less than 1% of patients were secondary surgical intervention (pars plana vitrectomy with membrane peel) and lens exchange (due to torn lens haptic).

*Compared against AcrySof® IQ (SN60WF), HOYA AF-1™ FY-60AD and enVista® IOLs (MX60).

Reference: 1. Data on file. Chromatic aberration of the TECNIS® Symphony IOL. Johnson & Johnson Surgical Vision, Inc. Santa Ana, CA.

TECNIS is a trademark of Johnson & Johnson Surgical Vision, Inc.
All other trademarks are the intellectual property of their respective owners.
©Johnson & Johnson Surgical Vision, Inc. 2019 | TecnisIOL.com | PP2018CT5383



Leading Innovation

Transformative technology.
Reliable outcomes.

High-Quality Vision

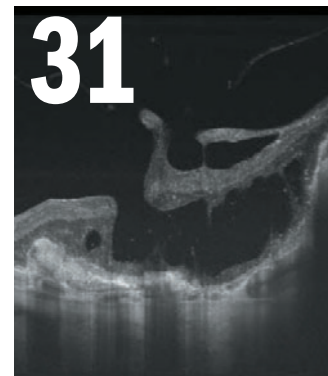
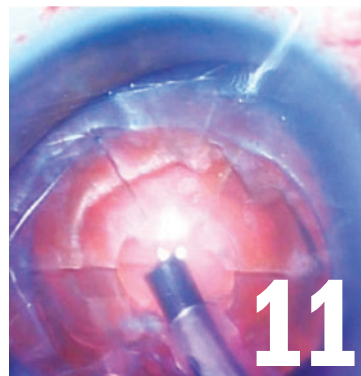
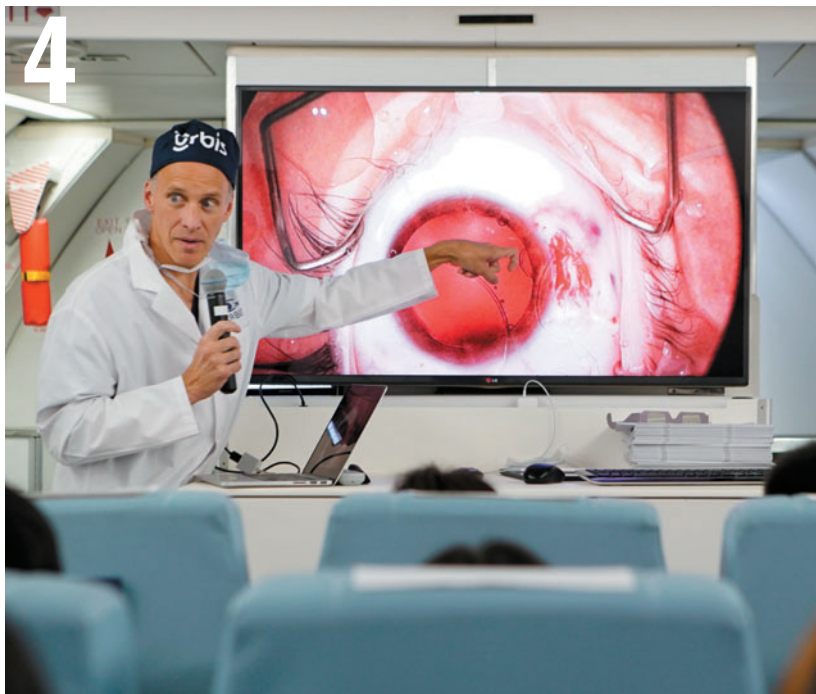Unmatched image contrast.^{1*}
Outstanding visual acuity.

Exceptional Satisfaction

Broadest IOL portfolio.
Enhancing each lifestyle.

Bring Vision to Life.

Johnson & Johnson VISION



Surgery

11 NEW INSIGHTS ON LASER CATARACT SURGERY

An international panel of laser cataract surgery (LCS) expert-users identify directions for new research

Special Report

27 TOPICAL HEMATOPOIETIC THERAPIES FOR DRY EYE

Autologous serum tears is safe, effective for treating ocular surface disorders, says Victor L. Perez, MD

Clinical Diagnosis

32 COMMUNITY SCREENINGS VITAL TO EYE HEALTH

Screening in community venues could reduce vision loss associated with glaucoma, says L. Jay Katz, MD

In This Issue

4 FOCAL POINTS 7 EDITORIAL 28 MARKETPLACE

What's Trending

See what the ophthalmic community is reading on *OphthalmologyTimes.com*

1 PODCAST: (Part 1) Why the fuss about AI in ophthalmology?

<http://bit.ly/2E7FRmS>

2 PODCAST: (Part 2) Embracing AI in DR, glaucoma and at the podium

<http://bit.ly/2BK5lp5>

3 Triggerfish pressure sensor promising

<http://bit.ly/2TPYQYE>

4 Livin' in the real world

<http://bit.ly/2GGzOYn>

Digital App

Introducing the *Ophthalmology Times* app for iPad and iPhone. Download it for free today at OphthalmologyTimes.com/OTapp

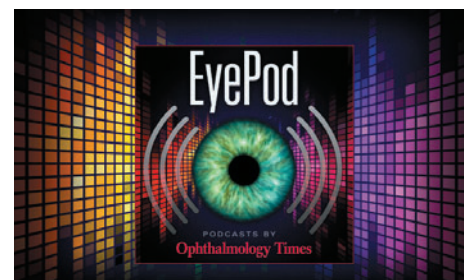


eReport

Sign up for *Ophthalmology Times*' weekly eReport at <http://bit.ly/XjksXX>



Podcast



Check out the latest EyePod episode: John S. Grande, CFP discusses strategies for how investors can protect their portfolio when there's market volatility.

Listen to the full interview here: <http://bit.ly/2GI7xQT>

Facebook

Like *Ophthalmology Times* at [Facebook.com/OphthalmologyTimes](https://www.facebook.com/OphthalmologyTimes)

Orbis educational footprint soars to new heights

Novel telemedicine technology platform allows for real-time mentoring in clinical setting

By **Julianne Mobilian**, Associate Editor, Ophthalmology Times

Orbis International, which operates the Flying Eye Hospital—the world’s only ophthalmic teaching hospital on an MD-10 aircraft—is best known for its charitable missions, where ophthalmologists travel to underserved countries and deliver sight-saving procedures aboard the (landed) aircraft.

However, this work is not without great cost and effort. Teams of nurses, anesthesiologists, and biomedical engineers must be assembled, and travel does not come cheap—especially when medical equipment needs to be transported.

But what if such service could be delivered instantly, without the expenses or logistics of traveling? Thanks to a telemedicine platform (Cybersight) that digitally bridges the gap between volunteer ophthalmologists and trainee ophthalmologists, this is possible.

TAKE-HOME

► **Using Cybersight telemedicine technology, the Orbis Flying Eye Hospital can teach procedures in real-time and mentor doctors-in-training abroad.**

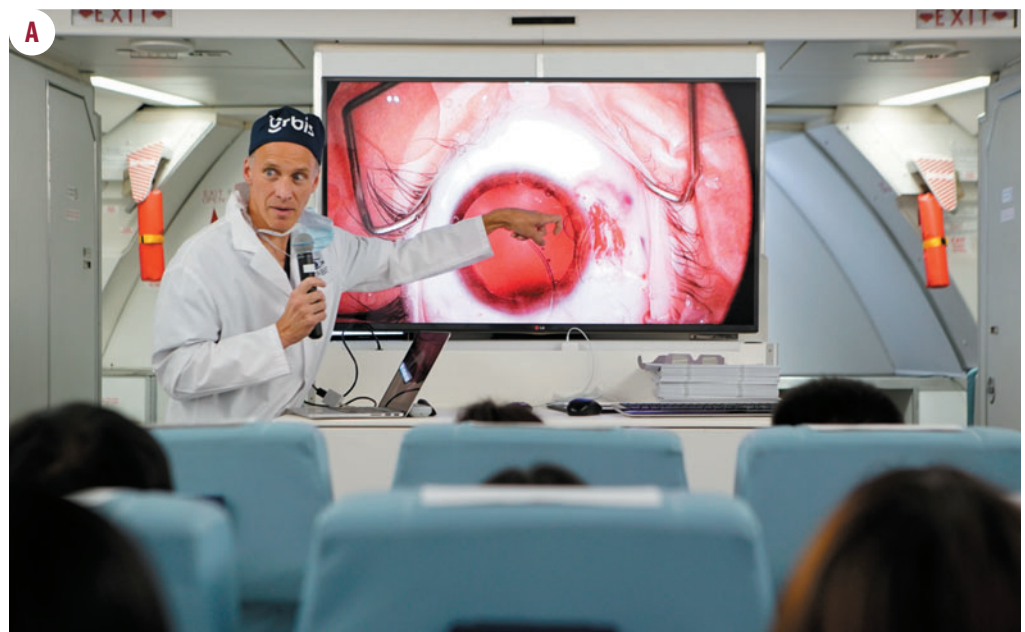EDUCATION AT CLICK OF A BUTTON

Cybersight uses real-time video, online courses, and artificial intelligence (AI)-equipped consultation service to help train and mentor other ophthalmologists in low- and middle-income countries.

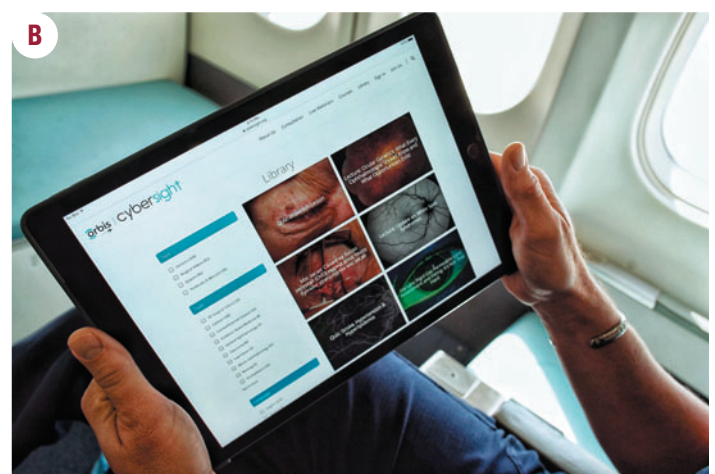


Dr. Neely

Ultimately, the program’s goal is help rural and impoverished communities create sustainable methods of ophthalmic care which were previously unavailable, said Daniel E. Neely, MD, professor of ophthalmology, Midwest Eye Institute, Indiana School of Medicine, University of Indiana,



(FIGURE 1) **A** The Orbis Flying Eye Hospital is a state-of-the-art teaching facility complete with classroom. The nonprofit organization is best known for its charitable missions, where ophthalmologists travel to underserved countries and deliver sight-saving procedures aboard the (landed) aircraft.



B Orbis’ Cybersight online training service also features a digital library, which houses surgical demonstration videos, medical lectures, and quizzes. (Images courtesy of Orbis International)

Indianapolis, and medical advisor for Orbis.

The program fosters a mentor-mentee relationship between an accredited ophthalmologist and a trainee ophthalmologist who lives in an underserved part of the world.

“You can only send people and equipment to so many places, but you can go everywhere, an unlimited number of times, with technology,” Dr. Neely said. “That is the power and force multiplier that technology provides us.”

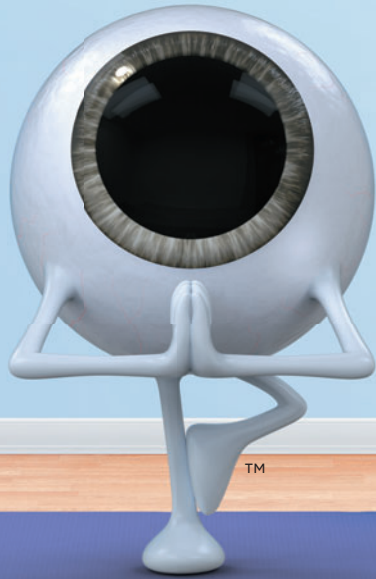
Thanks to Cybersight, Orbis was able to train more than 5,000 professionals in 165 countries, and also facilitated more than 2,100 patient consultations in 2018.

It’s also useful, as mentees can create individual profiles and have access to Cybersight’s digital library, which houses surgical demonstration videos, medical lectures, and quizzes.

Mentees are also able to have their course

Continues on page 10 : Orbis

Less stress. Pure success.



OMIDRIA® (phenylephrine and ketorolac intraocular solution) 1% / 0.3% is added to ophthalmic irrigating solution used during cataract surgery or intraocular lens replacement and is indicated for maintaining pupil size by preventing intraoperative miosis and reducing postoperative ocular pain.

The data are compelling and consistent—OMIDRIA makes cataract surgery better for you and your patients

Published and presented clinical studies report that in post-launch (i.e., not included in current labeling), prospective and retrospective, double-masked and open-label, cohort and case-controlled, single- and multi-center analyses, the use of OMIDRIA, compared to the surgeons' standard of care, statistically significantly:

- Prevents Intraoperative Floppy Iris Syndrome (IFIS)¹
- Reduces complication rates (epinephrine comparator)²
- Decreases use of pupil-expanding devices (epinephrine comparator)²⁻⁷
- Reduces surgical times (epinephrine comparator)^{2,4,6,7}
- Prevents miosis during femtosecond laser-assisted surgery (epinephrine comparator)^{5,8}
- Improves uncorrected visual acuity on day after surgery (epinephrine comparator)²
- Delivers NSAID to the anterior chamber and related structures better than routine preoperative topical drug administration, resulting in effectively complete postoperative inhibition of COX-1 and COX-2^{9,10}

Separately reimbursed under Medicare Part B

Contact your OMIDRIA representative today or visit omidria.com to learn more

IMPORTANT SAFETY INFORMATION

OMIDRIA must be added to irrigating solution prior to intraocular use.

OMIDRIA is contraindicated in patients with a known hypersensitivity to any of its ingredients.

Systemic exposure of phenylephrine may cause elevations in blood pressure.

Use OMIDRIA with caution in individuals who have previously exhibited sensitivities to acetylsalicylic acid, phenylacetic acid derivatives, and other nonsteroidal anti-inflammatory drugs (NSAIDs), or have a past medical history of asthma.

The most commonly reported adverse reactions at $\geq 2\%$ are eye irritation, posterior capsule opacification, increased intraocular pressure, and anterior chamber inflammation.

Please see the Full Prescribing Information for OMIDRIA at www.omidria.com/prescribinginformation.

You are encouraged to report Suspected Adverse Reactions to the FDA.

Visit www.fda.gov/medwatch, or call 1-800-FDA-1088.

References: 1. Silverstein SM, Rana V, Stephens R, Segars L, Pankratz J, Shivani R, et al. Effect of phenylephrine 1.0%-ketorolac 0.3% injection on tamsulosin-associated intraoperative floppy-iris syndrome. *J Cataract Refract Surg.* 2018;44(9):1103-1108. 2. Rosenberg ED, Nattis AS, Alevi D, et al. Visual outcomes, efficacy, and surgical complications associated with intracameral phenylephrine 1.0%/ketorolac 0.3% administered during cataract surgery. *Clin Ophthalmol.* 2018;12:21-28. 3. Bucci FA Jr, Michalek B, Fluet AT. Comparison of the frequency of use of a pupil expansion device with and without an intracameral phenylephrine and ketorolac injection 1%/0.3% at the time of routine cataract surgery. *Clin Ophthalmol.* 2017;11:1039-1043. 4. Visco D. Effect of phenylephrine/ketorolac on iris fixation ring use and surgical times in patients at risk of intraoperative miosis. *Clin Ophthalmol.* 2018;12:301-305. 5. Walter K, Delwadia N. Miosis prevention in femtosecond cataract surgery using a continuous infusion of phenylephrine and ketorolac. Presented at: 2018 American Society of Cataract and Refractive Surgery (ASCRS) and American Society of Ophthalmic Administrators (ASOA) Annual Meeting; April 13-17, 2018; Washington, DC. 6. Matossian C. Clinical outcomes of phenylephrine/ketorolac vs. epinephrine in cataract surgery in a real-world setting. Presented at: American Society of Cataract and Refractive Surgery (ASCRS) and American Society of Ophthalmic Administrators (ASOA) Annual Meeting; April 13-17, 2018; Washington, DC. 7. Al-Hashimi S, Donaldson K, Davidson R, et al. Medical and surgical management of the small pupil during cataract surgery. *J Cataract Refract Surg.* 2018;44:1032-1041. 8. Gayton JL. E-poster presented at: 15th International Congress on Vision Science and Eye; 2017 Aug 10-11; London, UK. 9. Katsev DA, Katsev CC, Pinnow J, Lockhart CM. Intracameral ketorolac concentration at the beginning and end of cataract surgery following preoperative topical ketorolac administration. *Clin Ophthalmol.* 2017;11:1897-1901. 10. Waterbury LD. Alternative drug delivery for patients undergoing cataract surgery as demonstrated in a canine model. *J Ocul Pharmacol Ther.* 2018;34:154-160.



OMIDRIA®
(phenylephrine and ketorolac
intraocular solution)
1% / 0.3%

Ophthalmology Times MISSION STATEMENT

Ophthalmology Times is a physician-driven media brand that presents cutting-edge advancements and analysis from around the world in surgery, drug therapy, technology, and clinical diagnosis to elevate the delivery of progressive eye health from physician to patient.

Ophthalmology Times' vision is to be the leading content resource for ophthalmologists.

Through its multifaceted content channels, *Ophthalmology Times* will assist physicians with the tools and knowledge necessary to provide advanced quality patient care in the global world of medicine.

CHIEF MEDICAL EDITOR Peter J. McDonnell, MD Wilmer Eye Institute Johns Hopkins University Baltimore, MD

ASSOCIATE MEDICAL EDITORS

Dimitri Azar, MD

University of Illinois, Chicago
Chicago, IL

Anne L. Coleman, MD
Jules Stein Eye Institute, UCLA
Los Angeles, CA

Ernest W. Kornmehl, MD

Harvard & Tufts Universities
Boston, MA

Robert K. Maloney, MD
Los Angeles, CA

Joan Miller, MD

Massachusetts Eye & Ear
Infirmary
Harvard University
Boston, MA

Randall Olson, MD

University of Utah
Salt Lake City, UT

Robert Osher, MD

University of Cincinnati
Cincinnati, OH

Anterior Segment/Cataract Cornea/External Disease

Ashley Behrens, MD
Wilmer Eye Institute, Johns Hopkins University
Baltimore, MD

Elizabeth A. Davis, MD
University of Minnesota,
Minneapolis, MN

Uday Devgan, MD
Jules Stein Eye Institute, UCLA
Los Angeles, CA

Richard S. Hoffman, MD
Oregon Health & Science University
Portland, OR

Samuel Masket, MD
Jules Stein Eye Institute, UCLA
Los Angeles, CA

Bartly J. Mondino, MD
Jules Stein Eye Institute, UCLA
Los Angeles, CA

Mark Packer, MD
Boulder, CO

Michael Raizman, MD
Massachusetts Eye & Ear, Harvard University Boston, MA

Ehsan "Ethan" Sadri, MD, FACS
Newport Beach, CA

Michael Snyder, MD
Cincinnati Eye Institute
Cincinnati, OH

Farrell "Toby" Tyson, MD
Cape Coral, FL

Glaucoma

Robert D. Fechtner, MD
SUNY Upstate Medical University
Syracuse, NY

Neeru Gupta, MD
University of Toronto
Toronto, Canada

Richard K. Parrish II, MD
Bascom Palmer Eye Institute, University of Miami
Miami, FL

Robert Ritch, MD
New York Eye & Ear Infirmary
New York, NY

Joel Schuman, MD
NYU Langone Medical Center
New York, NY

Kuldev Singh, MD

Stanford University
Stanford, CA

Joshua D. Stein, MD
University of Michigan
Ann Arbor, MI

Robert N. Weinreb, MD
Hamilton Glaucoma Center
University of California, San Diego

Neuro-Ophthalmology

Andrew G. Lee, MD
Blanton Eye Institute, Houston Methodist Hospital
Houston, TX

Oculoplastics/ Reconstructive Surgery

Robert Goldberg, MD
Jules Stein Eye Institute, UCLA
Los Angeles, CA

John T. LiVecchi, MD
University of Florida College of Medicine
Gainesville, FL

Shannah L. Merbs, MD
Wilmer Eye Institute, Johns Hopkins University
Baltimore, MD

Pediatric Ophthalmology

Norman B. Medow, MD
Albert Einstein College of Medicine
Bronx, NY

Jennifer Simpson, MD
University of California, Irvine
Irvine, CA

H. Jay Wisnicki, MD
New York Eye & Ear Infirmary, Beth Israel Medical Center,
Albert Einstein College of Medicine
New York, NY

Practice Management

Joseph C. Noreika, MD
Medina, OH

Frank Weinstock, MD
Boca Raton, FL

Refractive Surgery

William Culbertson, MD
Bascom Palmer Eye Institute, University of Miami
Miami, FL

Peter S. Hersh, MD

University of Medicine & Dentistry of New Jersey
Newark, NJ

Jonathan H. Talamo, MD
Harvard University
Boston, MA

Kazuo Tsubota, MD
Keio University School of Medicine
Tokyo, Japan

Retina/Vitreous

Stanley Chang, MD
Columbia University
New York, NY

David Chow, MD
University of Toronto
Toronto, Canada

Pravin U. Dugel, MD
Phoenix, AZ

Sharon Fekrat, MD
Duke University
Durham, NC

Julia Haller, MD
Wills Eye Institute, Thomas Jefferson University
Philadelphia, PA

Tarek S. Hassan, MD
Oakland University
Rochester, MI

Michael Ip, MD
Doheny Eye Institute
Los Angeles, CA

Carl D. Regillo, MD
Wills Eye Institute, Thomas Jefferson University
Philadelphia, PA

Lawrence J. Singerman, MD
Case Western Reserve University
Cleveland, OH

Uveitis

Emmett T. Cunningham Jr., MD, PhD
Stanford University
Stanford, CA

Chief Medical Editors-Emeritus

Jack M. Dodick, MD
New York University School of Medicine
New York, NY (1976-1996)

David R. Guyer, MD
New York, NY (1996-2004)

OFFICIAL PUBLICATION SPONSOR OF



Ophthalmology Times

FEBRUARY 15, 2019 ■ VOL. 44, NO. 3

CONTENT

Chief Medical Editor Peter J. McDonnell, MD

Group Editorial Director Sheryl Stevenson
sheryl.stevenson@ubm.com 440/891-2625

Associate Editor Julianne Mobilian
julianne.mobilian@ubm.com 440/891-2608

Design Director Robert McGarr

Senior Graphic Designer Lecia Landis

Graphic Designer Steph Bentz

Anterior Segment Techniques
Ernest W. Kornmehl, MD

coding.doc L. Neal Freeman, MD, MBA

Money Matters John J. Grande, Traudy F. Grande,
and John S. Grande, CFPs®

Neuro-Ophthalmology Andrew G. Lee, MD

Ophthalmic Heritage Norman B. Medow, MD

Tech Talk H. Jay Wisnicki, MD

Uveitis Update
Emmett T. Cunningham Jr., MD, PhD, MPH

PUBLISHING /ADVERTISING

**Executive Vice President, Senior Managing Director,
UBM Life Sciences Group** Thomas W Ehardt

Group Publisher Leonardo Avila
leonardo.avila@ubm.com 302/239-5665

Publisher Erin Schlusel Stever
erin.schlusel@ubm.com 215/962-5399

National Account Manager Cherie Pearson
cherie.pearson@ubm.com 609/636-0172

Account Manager, Recruitment Advertising
Joanna Shippoli joanna.shippoli@ubm.com
440/891-2615

Sales Director, Digital Media Don Berman
don.berman@ubm.com 203/523-7013

Reprints Licensing and Reuse of Content: Contact our official partner, Wright's Media, about available usages, license fees, and award seal artwork at Advanstar@wrightsmedia.com for more information. Please note that Wright's Media is the only authorized company that we've partnered with for Advanstar UBM materials.

Permissions/International Licensing
Jillyn Frommer jillyn.frommer@ubm.com
732/346-3007

PRODUCTION

Production Director Karen Lenzen
klenzen@hcl.com 218/740-6371

AUDIENCE DEVELOPMENT

Audience Development Manager Kelly Kemper
kelly.kemper@ubm.com 612/253-2039

UBM Media provides certain customer contact data (such as customers' names, addresses, phone numbers, and e-mail addresses) to third parties who wish to promote relevant products, services, and other opportunities that may be of interest to you. If you do not want UBM Media to make your contact information available to third parties for marketing purposes, simply call toll-free 866-529-2922 between the hours of 7:30 a.m. and 5 p.m. CST and a customer service representative will assist you in removing your name from UBM Media's lists. Outside the U.S., please phone 218-740-6477.

Ophthalmology Times does not verify any claims or other information appearing in any of the advertisements contained in the publication, and cannot take responsibility for any losses or other damages incurred by readers in reliance of such content.

Ophthalmology Times cannot be held responsible for the safekeeping or return of unsolicited articles, manuscripts, photographs, illustrations or other materials.

Ophthalmology Times is a member of the Association of Independent Clinical Publications Inc.

Library Access Libraries offer online access to current and back issues of *Ophthalmology Times* through the EBSCO host databases.

To subscribe, call toll-free 888-527-7008. Outside the U.S. call 218-740-6477.



Ophthalmology Times Industry Council

Leslie Amodei
Optos Inc., Vice President of Global Product Marketing

Rahim K. Hirji, RPh
Omers Corp., Director - Marketing

Neil Levine
Regeneron Healthcare Solutions
Executive Director, Marketing
Ophthalmology

Cody McKenzie
Glaukos, Director - U.S. Marketing

Tom Mitro
Aerie Pharmaceuticals
President and Chief Operating Officer

Brian O'Neal
Alcon Laboratories Inc., Head of Marketing - U.S. Surgical

Ram Palanki
Santen, Senior Vice President of Commercial, Americas

John Saharek
Imprimis Pharmaceuticals, Chief Commercial Officer

Erin Schallhorn
Carl Zeiss Meditec, Sr. Director, Medical Affairs and Professional Education

Julie Speed
Johnson & Johnson Vision, Sr. Director of Marketing Americas, Surgical

Tracy Valorie
Bausch + Lomb, US Pharmaceuticals and Surgical
Valeant Pharmaceuticals North America, LLC
Sr. Vice President and General Manager

How to Contact Ophthalmology Times

Editorial
Millennium Place East
25115 Country Club Blvd.
North Olmsted, OH 44070
440/826-2800, FAX: 440/756-5227

Subscription Services
Toll-Free: 888/527-7008 or
218/740-6477
FAX: 218/740-6417

Advertising
485 Route 1 South
Building F, Suite 210,
Iselin, NJ 08830-3009
732/596-0276, FAX: 732/596-0003

Production
325 W. 1st St.
STE 300 Duluth, MN 55802
800/346-0085
FAX: 218/740-7223, 218/740-6576

Steps to self-help

The 14 habits of highly successful *Ophthalmology Times* readers



By Peter J. McDonnell, MD

director of the Wilmer Eye Institute, Johns Hopkins University School of Medicine, Baltimore, and chief medical editor of *Ophthalmology Times*.

He can be reached at 727 Maumenee Building 600 N. Wolfe St. Baltimore, MD 21287-9278
Phone: 443/287-1511 Fax: 443/287-1514
E-mail: pmcdonn1@jhmi.edu

THE “SELF-HELP” INDUSTRY in the United States offers its services to people who wish to improve themselves or some aspects of their lives. Americans spend an estimated \$10 billion annually on books and seminars offered by the gurus in this field.

Fortunately, for us ophthalmologists, the incredibly helpful issue of *Ophthalmology Times* that arrives in our mailbox or e-mail every two weeks is completely free.

One alert *Ophthalmology Times* reader recently shared with me a podcast addressing “The Top Habits of Highly Successful People.” The speakers are not physicians and have an emphasis on financial success; they summarize the findings of some famous self-help authors and speakers. I thought many of the points made are relevant to ophthalmologists.

Some examples include that golf-pro Tiger Woods always wears red shirts on Sundays whereas a baseball player wears the same unwashed lucky T-shirt every day for a week. (*Editor’s note:* Cool as this may seem, I am not prepared to endorse this second habit for my fellow ophthalmologists looking to grow their practices.)

TRY THESE HABITS OUT FOR SIZE

Other habits that I do commend for your consideration include:

- Wake up early (50% of self-made millionaires get out of bed at least 3 hours before their work-day starts).
- Maintain a regular exercise schedule to relieve stress, maintain health, feel better all day (the average millionaire exercises about 6 hours per week compared with 2.5 hours for the average American).
- Have some quiet time in the morning for reflec-

tion/meditation/prayer/yoga/focused thinking to prepare for the day.

- Kiss one or more loved ones before heading off to the salt mines (i.e., the office).
- Pay credit card bills the same day every month (never forget and pay ridiculous credit card interest rates).
- Work hard and smart (the average millionaire works 38 hours per week compared with 32 hours for the average American).
- Read or listen to books for pleasure and knowledge (millionaires average 5.5 hours per week versus 2 hours for the average American).
- Stop wasting time with Facebook, etc. (the average millionaire spends 2.5 hours per week on social media compared with 14 hours for the average American).
- Spend time with family (8.5 hours for millionaires versus 3.6 hours for the average American).
- Don’t skimp on sleep (the average millionaire sleeps about 7.5 hours per night).
- Begin tasks with the end in mind (we should all have strategic plans and goals for our practices/careers).
- Provide a service to society (What could be a better service than helping people see?).
- Spend time with people who inspire you (“you are the average of the five people you spend most of your time with”).
- Make it a priority to read your Chief Medical Editor’s column in *Ophthalmology Times* every 14 days.


Okay, none of these so-called gurus mentioned that last one, so I added it.

But I do think that most of the ophthalmologists I admire check off many—if not most—of the above boxes. ■

Reference

- <https://www.moneyguy.com/2018/10/financial-success-habits/>

THE CYCLE OF INFLAMMATION IN DRY EYE DISEASE²




Ocular Surface Stress



Inflammation



Tear Film Instability



Signs & Symptoms



XIIDRA MAY INTERRUPT THE CYCLE OF INFLAMMATION CENTRAL TO DRY EYE DISEASE^{1,2}

The exact mechanism of action of Xiidra in Dry Eye Disease is not known.¹

Xiidra blocks the interaction of ICAM-1 and LFA-1, which is a key mediator of the inflammation central to Dry Eye Disease. *In vitro* studies have shown that Xiidra may inhibit the recruitment of previously activated T cells, the activation of newly recruited T cells, and the release of pro-inflammatory cytokines.¹

.....
Check out Xiidra-ECP.com
.....

Indication

Xiidra[®] (lifitegrast ophthalmic solution) 5% is indicated for the treatment of signs and symptoms of dry eye disease (DED).

Important Safety Information

Xiidra is contraindicated in patients with known hypersensitivity to lifitegrast or to any of the other ingredients.

In clinical trials, the most common adverse reactions reported in 5-25% of patients were instillation site irritation, dysgeusia and reduced visual acuity. Other adverse reactions reported in 1% to 5% of the patients were blurred vision, conjunctival hyperemia, eye irritation, headache, increased lacrimation, eye discharge, eye discomfort, eye pruritus and sinusitis.

To avoid the potential for eye injury or contamination of the solution, patients should not touch the tip of the single-use container to their eye or to any surface.

Contact lenses should be removed prior to the administration of Xiidra and may be reinserted 15 minutes following administration.

Safety and efficacy in pediatric patients below the age of 17 years have not been established.

For additional safety information, see accompanying Brief Summary of Safety Information on the adjacent page and Full Prescribing Information on Xiidra-ECP.com.

References:

1. Xiidra [Prescribing Information]. Lexington, MA: Shire US. 2. TFOS DEWS II Research Subcommittee. Report of the Research Subcommittee of the Tear Film & Ocular Surface Society Dry Eye WorkShop II (2017). *Ocul Surf.* 2017;15(3):269-275.





BRIEF SUMMARY:

Consult the Full Prescribing Information for complete product information.

INDICATIONS AND USAGE

Xiidra® (lifitegrast ophthalmic solution) 5% is indicated for the treatment of the signs and symptoms of dry eye disease (DED).

DOSAGE AND ADMINISTRATION

Instill one drop of Xiidra twice daily (approximately 12 hours apart) into each eye using a single-use container. Discard the single-use container immediately after using in each eye. Contact lenses should be removed prior to the administration of Xiidra and may be reinserted 15 minutes following administration.

CONTRAINDICATIONS

Xiidra is contraindicated in patients with known hypersensitivity to lifitegrast or to any of the other ingredients in the formulation.

ADVERSE REACTIONS

Clinical Trials Experience

Because clinical studies are conducted under widely varying conditions, adverse reaction rates observed in clinical studies of a drug cannot be directly compared to rates in the clinical trials of another drug and may not reflect the rates observed in practice. In five clinical studies of dry eye disease conducted with lifitegrast ophthalmic solution, 1401 patients received at least 1 dose of lifitegrast (1287 of which received lifitegrast 5%). The majority of patients (84%) had ≤ 3 months of treatment exposure. 170 patients were exposed to lifitegrast for approximately 12 months. The majority of the treated patients were female (77%). The most common adverse reactions reported in 5-25 % of patients were instillation site irritation, dysgeusia and reduced visual acuity. Other adverse reactions reported in 1% to 5% of the patients were blurred vision, conjunctival hyperemia, eye irritation, headache, increased lacrimation, eye discharge, eye discomfort, eye pruritus and sinusitis.

Postmarketing Experience

The following adverse reactions have been identified during postapproval use of Xiidra. Because these reactions are reported voluntarily from a population of uncertain size, it is not always possible to reliably estimate their frequency or establish a causal relationship to drug exposure.

Rare cases of hypersensitivity, including anaphylactic reaction, bronchospasm, respiratory distress, pharyngeal edema, swollen tongue, and urticaria have been reported. Eye swelling and rash have been reported.

USE IN SPECIFIC POPULATIONS

Pregnancy

There are no available data on Xiidra use in pregnant women to inform any drug associated risks. Intravenous (IV) administration of lifitegrast to pregnant rats, from pre-mating through gestation day 17, did not produce teratogenicity at clinically relevant systemic exposures. Intravenous administration of lifitegrast to pregnant rabbits during organogenesis produced an increased incidence of omphalocele at the lowest dose

tested, 3 mg/kg/day (400-fold the human plasma exposure at the recommended human ophthalmic dose [RHOD], based on the area under the curve [AUC] level). Since human systemic exposure to lifitegrast following ocular administration of Xiidra at the RHOD is low, the applicability of animal findings to the risk of Xiidra use in humans during pregnancy is unclear.

Animal Data

Lifitegrast administered daily by intravenous (IV) injection to rats, from pre-mating through gestation day 17, caused an increase in mean preimplantation loss and an increased incidence of several minor skeletal anomalies at 30 mg/kg/day, representing 5,400-fold the human plasma exposure at the RHOD of Xiidra, based on AUC. No teratogenicity was observed in the rat at 10 mg/kg/day (460-fold the human plasma exposure at the RHOD, based on AUC). In the rabbit, an increased incidence of omphalocele was observed at the lowest dose tested, 3 mg/kg/day (400-fold the human plasma exposure at the RHOD, based on AUC), when administered by IV injection daily from gestation days 7 through 19. A fetal No Observed Adverse Effect Level (NOAEL) was not identified in the rabbit.

Lactation

There are no data on the presence of lifitegrast in human milk, the effects on the breastfed infant, or the effects on milk production. However, systemic exposure to lifitegrast from ocular administration is low. The developmental and health benefits of breastfeeding should be considered, along with the mother's clinical need for Xiidra and any potential adverse effects on the breastfed child from Xiidra.

Pediatric Use

Safety and efficacy in pediatric patients below the age of 17 years have not been established.

Geriatric Use

No overall differences in safety or effectiveness have been observed between elderly and younger adult patients.

NONCLINICAL TOXICOLOGY

Carcinogenesis, Mutagenesis, Impairment of Fertility

Carcinogenesis: Animal studies have not been conducted to determine the carcinogenic potential of lifitegrast.

Mutagenesis: Lifitegrast was not mutagenic in the *in vitro* Ames assay. Lifitegrast was not clastogenic in the *in vivo* mouse micronucleus assay. In an *in vitro* chromosomal aberration assay using mammalian cells (Chinese hamster ovary cells), lifitegrast was positive at the highest concentration tested, without metabolic activation.

Impairment of fertility: Lifitegrast administered at intravenous (IV) doses of up to 30 mg/kg/day (5400-fold the human plasma exposure at the recommended human ophthalmic dose (RHOD) of lifitegrast ophthalmic solution, 5%) had no effect on fertility and reproductive performance in male and female treated rats.



Manufactured for: Shire US Inc., 300 Shire Way, Lexington, MA 02421. For more information, go to www.Xiidra.com or call 1-800-828-2088. Marks designated ® and ™ are owned by Shire or an affiliated company. ©2018 Shire US Inc. SHIRE and the Shire Logo are trademarks or registered trademarks of Shire Pharmaceutical Holdings Ireland Limited or its affiliates. Patented: please see <https://www.shire.com/legal-notice/product-patents> Last Modified: 01/2018 S33769

ORBIS

(Continued from page 4)

and lab homework graded by a volunteer ophthalmologist for accuracy with Cybersight, an extension of the platform praised by Dr. Neely as being a multipart, in-depth conversation.

“I don’t simply tell a mentee what to do on a patient case they have submitted,” he said. “I ask them questions, they provide follow-up information and updates, and we work together toward getting the best possible outcome for the patient.”

Dr. Neely has completed almost 1,200 online consults during his span of 17 years with Orbis International.

“Technology is the facilitator, but the interpersonal communication is the most powerful tool we have,” he said.

CHALLENGES

The human element is crucial when it comes to learning development, which can be challenging given that each person is thousands of miles from each other.

“You get the best teaching when a relationship develops beyond watching a webinar,” Dr. Neely said. “You need trust and confidence in your teacher when being mentored, whether that is via technology or face to face.”

As with most technologies, there are still strides to be made—particularly when it comes to retina imaging and treatment, according to Dr. Neely.

Due to the inconsistencies of the local hospitals Orbis partners with, some have access to the equipment, but most do not.

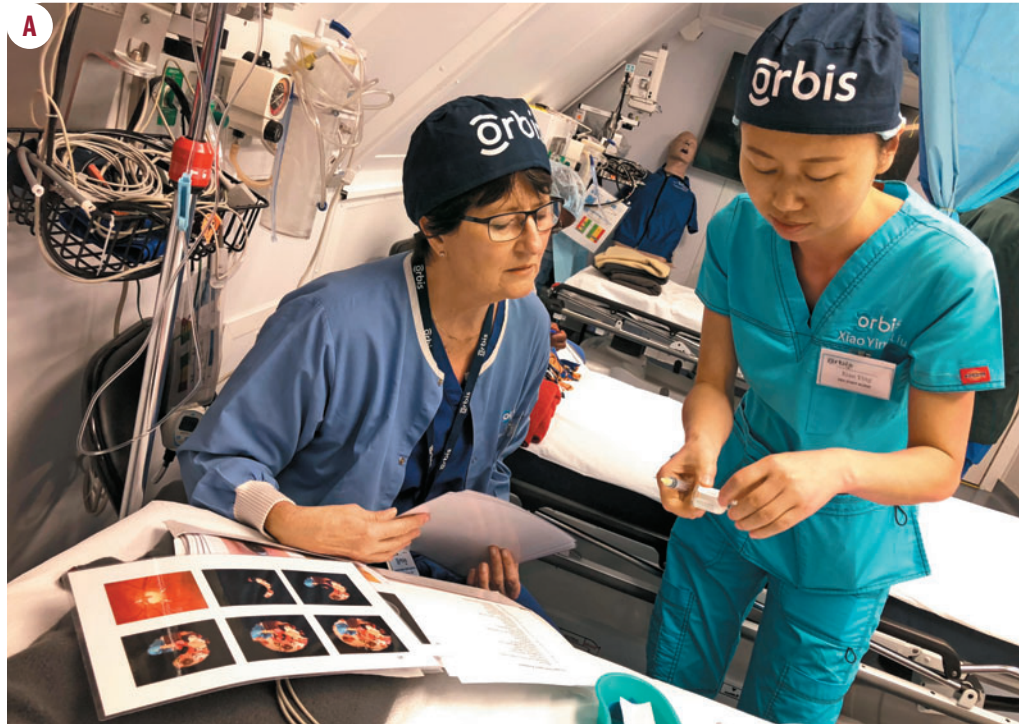“We still struggle to provide the highest-quality retina consultations because the subspecialty is very imaging technology-intensive: fundus photos, optical coherence tomography, fluorescein angiography, etc.,” he said.

THE PATH AHEAD

Collaboration with Visulytix, an AI company that integrates its technology (Pegasus) with Cybersight’s platform could address the issue.

The AI-powered software analyzes retina images, which can be taken with a standard retina camera or even a smartphone. The images are then uploaded to Visulytix’s cloud service, and in a matter of eight seconds, the AI system generates a report to Cybersight with an analysis.

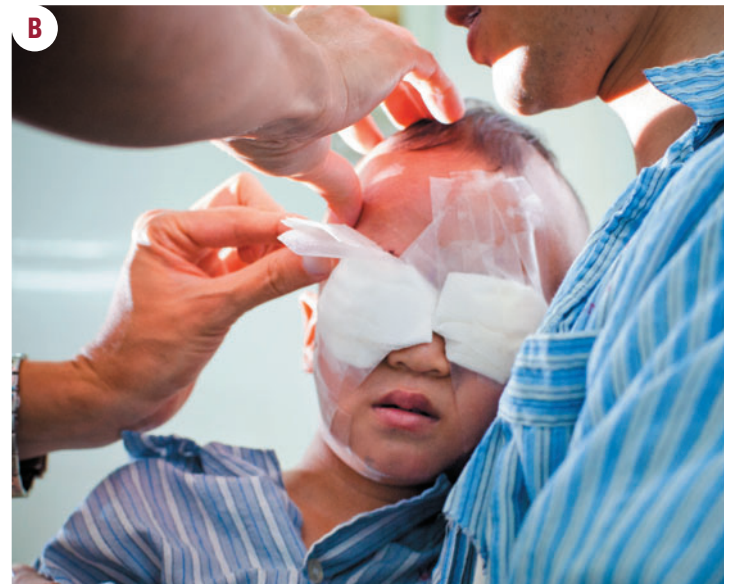The addition of the AI-powered software to Cybersight “enables doctors in low-resource countries to be some of the first to have access



(FIGURE 2) **A** The human element is crucial when it comes to learning development, which can be challenging given that each person is thousands of miles from each other.

B The addition of AI-powered software to Cybersight enables doctors in low-resource countries to be some of the first to have access to this latest advancement in medical AI to help them detect, diagnose, and treat patients with blinding eye diseases.

(Images courtesy of Orbis International)



to this latest advancement in medical AI to help them detect, diagnose, and treat patients with blinding eye diseases,” Dr. Neely said.

In terms of educational outreach, Cybersight speaks volumes for the future of charitable missions.

“I would like to see a day when we can easily do live, remote ‘hands-on’ teaching,” he said. “By that, I mean the ability to have a mentor and a mentee in two different countries who can examine a patient together or perform a surgery remotely with the mentor as a virtual assistant.”

While Orbis is piloting these things now, there are still kinks to work out, such as having enough bandwidth and limited latency.

“It’s coming—we can do it in a few places

now, but I want to see us be able to do it everywhere we work,” Dr. Neely said. ■

Reference

1. Orbis International. What we do: Cybersight. Orbis International web site. https://www.orbis.org/en/what-we-do/cybersight?gclid=Cj0KCQiAg_HhBRDNARisAGHLV50hMuchtzP2tOGipYLv1L20cEbDv9eJEmNqNU341aPX7jfaAlqTK0caAvqSEALw_wcB. Accessed Dec. 6, 2018.

DANIEL E. NEELY, MD

P: 317/944-2020

Dr. Neely is professor of ophthalmology at the Indiana University School of Medicine Glick Eye Institute and specializes in all aspects of pediatric ophthalmology.

Laser cataract surgery making complex cases more routine

International panel shares overview of current and future applications, benefits, challenges

By Cheryl Guttman Krader; Reviewed by Frank Goes Jr., MD; Thomas Laube, MD; Javier Mendicute, MD; Bernardo Mutani, MD; David O'Brart, MD; Jose Luis Rodríguez-Prats, MD; and Julian Stevens, MD

Almost a decade after the first femtosecond laser for cataract surgery became commercially available, laser cataract surgery (LCS) continues to have a limited role in clinical practice. Surgeons who have adopted the technique and become expert-users firmly believe that the laser adds value now and holds great promise for the future.

During the 36th Congress of the European Society of Cataract and Refractive Surgeons (ESCRS) in a meeting led by Julian D. Stevens, MD, Moorfields Eye Hospital, London, an international panel of LCS expert-users shared their experiences with the aims of learning from each other and identifying directions for new research.

The consensus of the group was that, even for routine cases, there is a role for using the femtosecond laser because it makes cataract surgery more straightforward, more reproducible, and safer. In addition, because laser pretreatment shortens the non-laser portion of the procedure, LCS reduces surgery-related ergonomic stress that can shorten a cataract surgeon's career.

The panel's discussion particularly highlighted the benefit of using the femtosecond laser for treating pre-existing astigmatism, which has relevance in a large percentage of routine cases, and brought to the forefront its role in complex situations, including eyes with a dense black or intumescent cataract. Looking ahead, the participants agreed that with the expected evolution toward capsulotomy-fixated implants, access to LCS will have an unequivocal advan-

tage for enabling delivery of optimal refractive and functional outcomes.

INTRASTROMAL ASTIGMATIC KERATOTOMY

Compared with manual penetrating astigmatic keratotomy (AK), femtosecond laser-assisted AK (FS-AK) has advantages for providing better rotational/angular alignment, better patient comfort, and reduced risk of infection. Data presented during meeting provided evidence that FS-AK is more effective than the manual approach and its result is more stable.

David O'Brart, MD, St. Thomas' Hospital, London, presented findings from analyses of outcomes in groups of patients who underwent FS-AK or manual limbal relaxing incisions (LRIs) in the context of a randomized controlled trial comparing LCS and conventional surgery [*J Cataract Refract Surg.* 2018;44:955-963]. The analyses included eyes with no visually significant comorbidities that were treated for >1 D of corneal astigmatism with a plano refractive target.

At 1 month after surgery, postoperative cylinder was ≤ 0.50 D in 18 (42%) of 43 eyes in the FS-AK group and in only 8 (20%) of 41 eyes in the LRI group. Dr. O'Brart reported that there were statistically significant differences favoring FS-AK in analyses of difference vector and correction index.

Thomas Laube, MD, private practice, Düsseldorf, Germany, presented results from a retrospective study demonstrating the efficacy and stability of FS-AK for reducing corneal and refractive astigmatism [*Open Journal of Ophthalmol.* 2017;7:262-272]. The study included 42 eyes with 0.5 D to 1.5 D of regular corneal astigmatism and total corneal irregular astigmatism < 0.300 μm . The AKs were 8.0 mm diameter paired symmetrical arcs centered according to the scanned capsule and created at a depth between 20% and 80% of corneal pachymetry. Reference marks were placed on the conjunctiva using a sterile disposable ink pen (Devon utility marker, Covidien) that is visible on the Catalys OCT image. Maximum arc length in Dr. Laube's series was 65°. Dr. Stevens noted, however, that arc lengths of 90° have been safely used for FS-AK.

“With the intrastromal cuts, there are anterior and posterior belts of intact tissue, and the corneas are relatively stiff in cataract patients who tend to be older,” he explained.

Dr. Laube analyzed astigmatic change using the Alpines vector method and found manifest cylinder was reduced significantly from 0.94 ± 0.62 D preoperatively to 0.64 ± 0.45 D at 1 month after surgery ($p = 0.03$) (Figure 1 on Page 12). Continued follow-up showed no significant change after 12 months ($p = 0.90$) at which time manifest cylinder was ≤ 0.5 D in 60% of eyes compared with just 38.1% preoperatively.

“The majority of patients were happy that they no longer needed glasses for distance vision,” Dr. Laube said.

Dr. Stevens noted that with LRIs, the astigmatic effect can continue to regress for up to 10 years. In contrast, he has collected data showing the effect of FS-AK achieves stability early on and remains unchanged for at least 5 years.

Providing some tips for performing FS-AK, Dr. Stevens noted that gas generated by the treatment is needed to break corneal fibers

Continues on page 12 : Laser cataract



Dr. Stevens



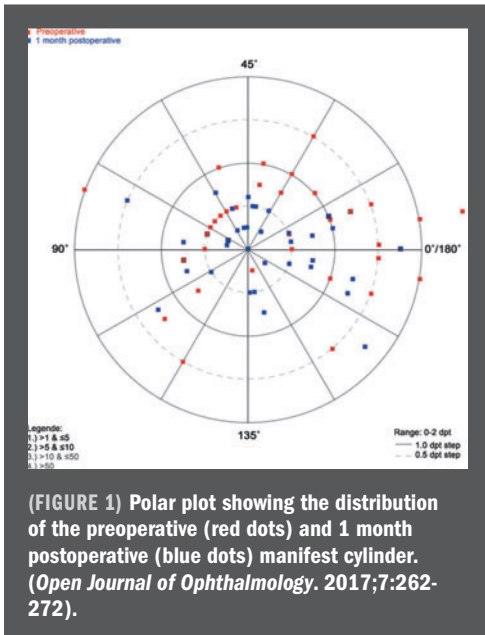
Dr. O'Brart



Dr. Laube

TAKE-HOME

► An international panel of laser cataract surgery (LCS) expert-users share their experiences, identifying directions for new research.



LASER CATARACT

(Continued from page 11)

and separate the arc walls. Therefore, it is important to use sufficient power, especially in younger patients.

Dr. Stevens also said that there is an increased risk for pupil constriction when performing FS-AK because the laser treatment is commonly placed over the iris. To mitigate this effect, he pre-treats the eyes with ketorolac drops and schedules the cases to minimize the delay between the laser and operating room portions of the procedure.

MAKING COMPLEX CASES MORE ROUTINE

INTUMESCENT CATARACT

Frank Goes Jr., MD, private practice, Antwerp, Belgium, presented his experience using a laser system (Catalys Precision Laser System, Johnson & Johnson Vision) to perform “ultrafast” capsulotomy in an eye with an intumescent cataract.



Dr. Goes

“I have no doubt it was a good idea to use the laser when operating on an intumescent lens,” Dr. Goes said.

He explained that, during manual capsulorhexis or standard laser capsulotomy, release of intralenticular pressure in an eye with an intumescent cataract creates a risk for radial tearing of the anterior capsule. Dr. Goes adjusted the settings for performing the capsulotomy to shorten his capsulotomy time to just 0.3 seconds (Table 1 on Page 12). The increase in speed did not compromise quality, he said.

Table 1. Catalys Precision Laser System settings and time for conventional and ultrafast capsulotomy

PARAMETER	CONVENTIONAL	ULTRAFAST
Incision depth (μm)	600	400
Horizontal spot spacing (μm)	5	10
Vertical spot spacing (μm)	10	16
Pulse energy (μJ)	4	10.0
Total energy (J)	0.7	0.4
Laser time (seconds)	1.5	0.3

Using trypan blue in the operating room to aid visualization, Dr. Goes saw that the capsule disk was not free-floating, but it was free of tags, and he removed it successfully without any radial tearing.

The meeting participants agreed that more evidence is needed to support use of the modified settings as a standard for laser capsulotomy in eyes with an intumescent cataract. Dr. Stevens noted that because a significant number of such cases present to Moorfields, he might have the opportunity to amass a series for a prospective study.

It was also noted that a double capsulotomy technique, involving an initial “mini” opening and a second larger capsulotomy, has been described as an alternative for safe capsulotomy in eyes with an intumescent cataract [*J Refract Surg*. 2014;30:742-745]. In this method, the first capsulotomy allows for release of intralenticular pressure. After fluid lens material is removed from the anterior chamber, the eye is redocked for the second capsulotomy.

Dr. Stevens observed that the need for redock-

ing adds time to the procedure and increases the risk for subconjunctival hemorrhage. Because of those issues, he called for manufacturers to modify their systems and eliminate the need for redocking after operators remove their foot from the pedal.

Dr. Goes’ case also prompted a discussion about reducing capsulotomy time in routine cases in order to minimize the potential for eye movement that would affect the accuracy of laser pulse placement. Dr. Stevens suggested that because the lasers work well

“out of the box” with the use of the manufacturer-recommended settings, surgeons are reluctant to experiment with modifications because they are worried about higher rates of incomplete capsulotomy.

Continues on page 14 : **Experience**

ACRYSOF® IQ TORIC IOL IMPORTANT PRODUCT INFORMATION

CAUTION: Federal (USA) law restricts this device to the sale by or on the order of a physician.

INDICATIONS: The AcrySof® IQ Toric posterior chamber intraocular lenses are intended for primary implantation in the capsular bag of the eye for visual correction of aphakia and pre-existing corneal astigmatism secondary to removal of a cataractous lens in adult patients with or without presbyopia, who desire improved uncorrected distance vision, reduction of residual refractive cylinder and increased spectacle independence for distance vision.

WARNING/PRECAUTION: Careful preoperative evaluation and sound clinical judgment should be used by the surgeon to decide the risk/benefit ratio before implanting a lens in a patient with any of the conditions described in the Directions for Use labeling. Toric IOLs should not be implanted if the posterior capsule is ruptured, if the zonules are damaged, or if a primary posterior capsulotomy is planned. Rotation can reduce astigmatic correction; if necessary lens repositioning should occur as early as possible prior to lens encapsulation. All viscoelastics should be removed from both the anterior and posterior sides of the lens; residual viscoelastics may allow the lens to rotate. Optical theory suggests that high astigmatic patients (i.e. > 2.5 D) may experience spatial distortions. Possible toric IOL related factors may include residual cylindrical error or axis misalignments. Prior to surgery, physicians should provide prospective patients with a copy of the Patient Information Brochure available from Alcon for this product informing them of possible risks and benefits associated with the AcrySof® IQ Toric Cylinder Power IOLs. Studies have shown that color vision discrimination is not adversely affected in individuals with the AcrySof® Natural IOL and normal color vision. The effect on vision of the AcrySof® Natural IOL in subjects with hereditary color vision defects and acquired color vision defects secondary to ocular disease (e.g., glaucoma, diabetic retinopathy, chronic uveitis, and other retinal or optic nerve diseases) has not been studied. Do not resterilize; do not store over 45° C; use only sterile irrigating solutions such as BSS® or BSS PLUS® Sterile Intraocular Irrigating Solutions.

ATTENTION: Reference the Directions for Use labeling for a complete listing of indications, warnings and precautions.

Alcon A Novartis Division

© 2018 Novartis 7/18 US-TOR-18-E-1605

FOR ROTATIONAL STABILITY, THERE'S NO COMPARISON^{1,2}



1. Lee BS, Chang DF. Comparison of the rotational stability of two toric intraocular lenses in 1273 consecutive eyes. *Ophthalmology*. 2018;0:1-7.
2. Potvin R, et al. Toric intraocular lens orientation and residual refractive astigmatism: an analysis. *Clin Ophthalmol*. 2016;10:1829-1836.

Please see Important Product Information on the adjacent page.

EXPERIENCE

(Continued from page 12)

ANTERIOR LENTICONUS

Jose Luis Rodríguez-Prats, MD, Clínica Visahermosa, Oftalvíst, Alicante, Spain, also presented a case in which use of the laser for capsulotomy proved beneficial. The case involved an eye with anterior lenticonus associated with Alport syndrome.



Dr. Rodríguez-Prats

“Performing anterior continuous curvilinear capsulorhexis in these eyes is difficult due to the structurally abnormal anterior capsule,” he said.

The patient described by Dr. Rodríguez-Prats underwent bilateral FLACS with the Catalys laser using the device’s software calipers to manually delineate the anterior capsulotomy. Multifocal toric IOLs were implanted with the aid of intraoperative aberrometry for power selection.

Preoperative UCVA was 0.8 OU in moderate photopic conditions; subjective refraction was -5.25 -7.25 x 180 OD and -6.75 -8.50 x 165 OD. Postoperatively, the patient achieved distance UCVA of 0.9 OU. BCVA was 1.0 OU, and his refraction was plano -0.50 x 5 OD and +0.50 -1.0 x 170 OS. At 45 days after surgery, both IOLs remained well centered.

DENSE BLACK CATARACT

Javier Mendicute, MD, Donostia University Hospital and Innova Begitek Ophthalmology Clinics, Donostia-San Sebastián, Spain, reviewed the benefits of LCS when operating on very dense (black) cataracts. In his opinion, the possi-



Dr. Mendicute

bility of using the laser in black cataracts depends on the imaging system’s ability to identify anatomic structures in the situation where

there is poor media transparency as well as the accuracy and penetration ability of the laser.

The type of OCT, its working wavelength, and the speed of image capture determine the quality of the image obtained through opaque media and the possibility of identifying the posterior capsule when there is limited lens transparency. Dr. Mendicute noted that he believes swept-source OCT is the best option for posterior capsule identification because it has faster acquisition time and deeper penetration than Scheimpflug technology or time-domain or spectral-domain OCT (Figure 2). He noted, however, that he has had the

opportunity to use all femtosecond platforms in the market and that all of the equipment available today allows the automatic identification of anatomical references.

“Because of the imaging technology that allows identification of the posterior capsule and their precision, femtosecond lasers can be used to safely treat the lens close to the posterior capsule,” Dr. Mendicute said.

The best fragmentation pattern to achieve the minimum use of energy and maximum efficiency when treating a dense black cataract is debatable. Dr. Mendicute said that a grid pattern can require a lot of energy and result in a lot of bubble generation. His approach uses a pattern that he named “microcrater, divide and conquer” in recognition of Howard Gimbel, MD (Figure 3). Using the femtosecond laser, he creates a 2-mm central disc and three radial cuts.

“After phacoemulsification of the central disc, there is a point of support to split the lens into six fragments that are easily removable,” Dr. Mendicute said.

Bernardo Mutani, MD, Torino, Italy, presented his experience with LCS using the Catalys laser

in an eye with a foldable posterior chamber phakic IOL (Visian ICL, STAAR Surgical).

Because the imaging system did not recognize the anterior surface of the cataract, Dr. Mutani said he needed to manually customize the anterior capsule to fit on the anterior surface of the lens.



Dr. Mutani

Thereafter, he was able to use his routine laser settings to successfully complete both the capsulotomy, which was centered on the pupil, and lens fragmentation.

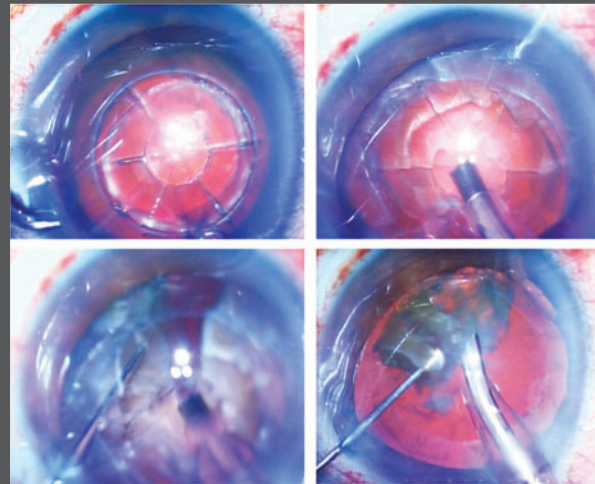
Dr. Mutani noted that trapping of cavitation bubbles in the space between the phakic IOL and the anterior lens capsule, which could impair laser energy delivery for the fragmentation step, was not a problem in this case that involved a cortical cataract.

“It is our experience that less gas is generated when treating a cortical cataract compared with a nuclear cataract,” Dr. Mutani said.

In the discussion following Dr. Mutani’s presentation, concern was also raised that in eyes with a phakic IOL, the laser’s imaging sys-

Intraoperative imaging				
LenSx	Catalys	Lenstar	Victus	Ziemer LDV
OCT	OCT	Scheimpflug	OCT	OCT
Spectral domain OCT (820-880 nm)	Spectral domain OCT (820-920 nm)	3D confocal structured Automatic biometry	Swept Source OCT	Spectral domain OCT

(FIGURE 2) Available femtosecond lasers for cataract surgery use different imaging technologies.



(FIGURE 3) The “microcrater, divide and conquer” approach for removing a dense black cataract.

(Figures 2 and 3 courtesy of Javier Mendicute, MD)

tem may give erroneous readings of the capsule surfaces.

Dr. Stevens noted that due to these challenges, he chooses to do standard cataract surgery in eyes with a phakic IOL. ■

FRANK GOES JR., MD

E: frankjr@goes.be

THOMAS LAUBE, MD

E: thomas@drlaube.de

Dr. Laube receives speakers’ fees from Johnson & Johnson GmbH.

JAVIER MENDICUTE, MD

E: jmendicu@chdo.osakidetza.net

Dr. Mendicute is a consultant to and receives research grants and support from Alcon, Johnson & Johnson Vision, and Carl Zeiss Meditec, and he is a member of the speakers’ bureau for Alcon and Bausch + Lomb.

BERNARDO MUTANI, MD

E: bernardo.mutani@oculisticaclk.it

DAVID O’BRART, MD

E: davidobrart@aol.com

Dr. O’Brart has been a consultant to and received a non-commercial research grant from Alcon.

JOSE LUIS RODRÍGUEZ-PRATS, MD

E: jldrodrprats@gmail.com

JULIAN STEVENS, MD

E: jds@uk.com

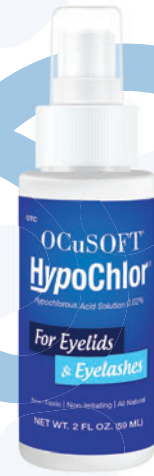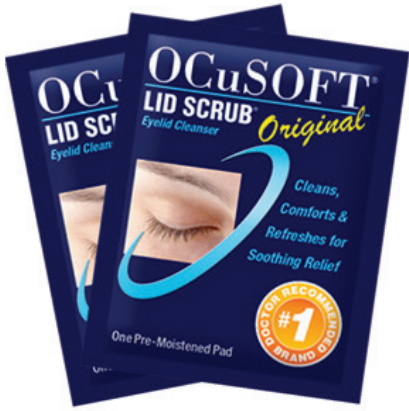Drs. Goes, Mutani, Rodríguez-Prats, and Stevens have no relevant financial interests to disclose.

The meeting of expert-users was organized by targomed GmbH and supported by an educational grant from Johnson & Johnson Vision.

CLEAN

THEN

SPRAY

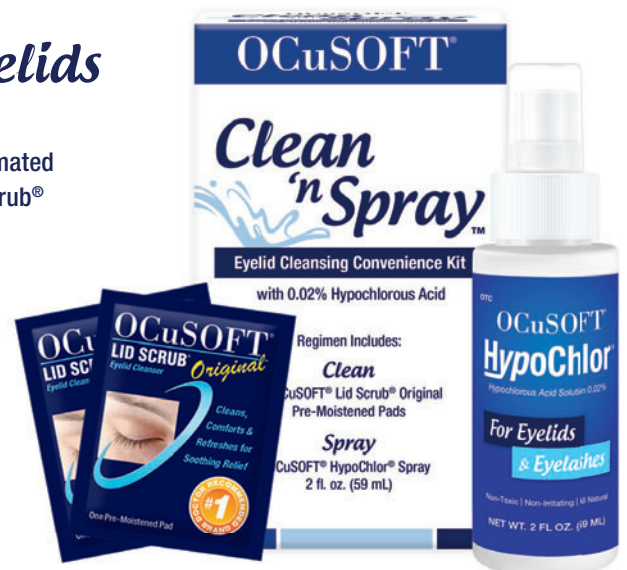

Healthy Eyes Start with Healthy Eyelids

The root cause of anterior blepharitis is the overproduction of oils. Surfactants in OCuSOFT® Lid Scrub® Eyelid Cleanser dissolve and remove oil, debris and desquamated skin. When the most severe conditions occur, the combination of OCuSOFT® Lid Scrub® and OCuSOFT® HypoChlor® (0.02% Hypochlorous acid) is ideal.

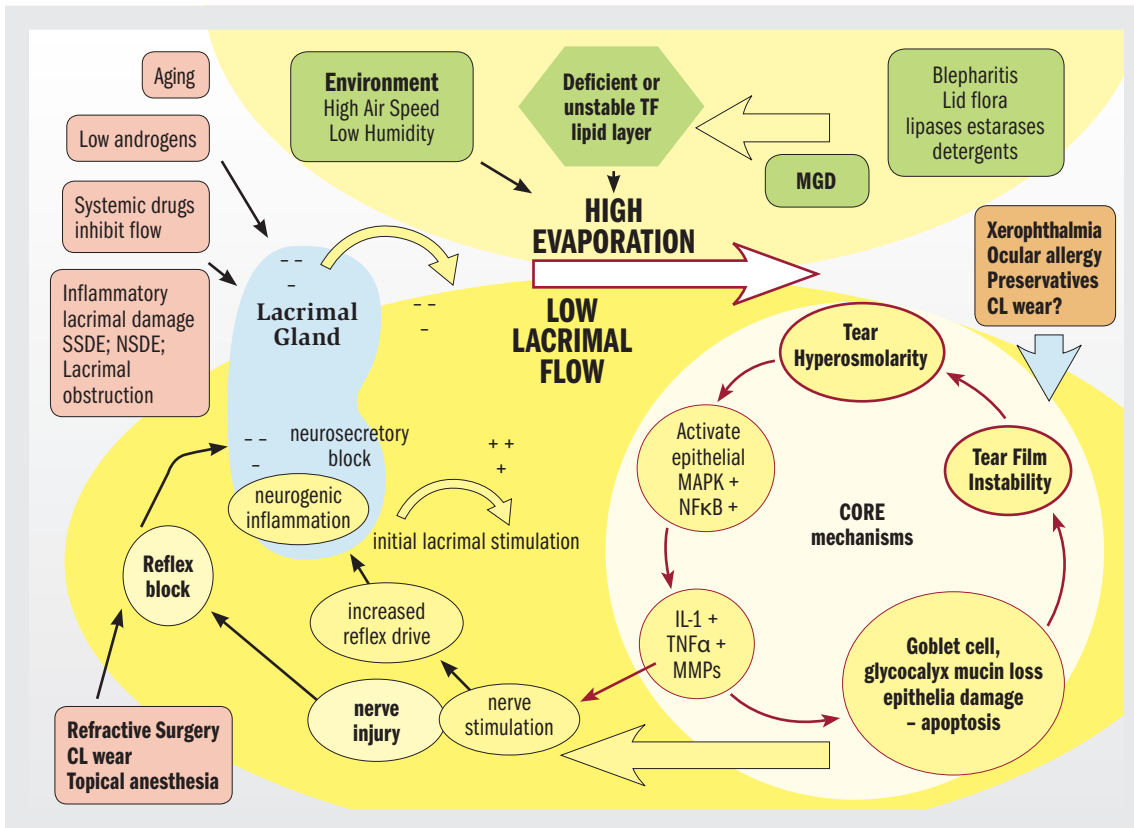
To achieve optimum results, **CLEAN** all oil, debris and other contaminants associated with eyelid irritations using OCuSOFT® Lid Scrub® Eyelid Cleanser and then **SPRAY** OCuSOFT® HypoChlor® for fast action against microorganisms.

OCuSOFT® Clean 'n Spray™



For more information and to order, call (800) 233-5469 or visit www.ocusoft.com

OCuSOFT®



(FIGURE 1) Mechanisms of dry eye. (Figure provided by Christopher J. Rapuano, MD; credit to DEWS Report. Research in dry eye: report of the Research Subcommittee of the International Dry Eye WorkShop (2007). *Ocul Surf.* 2007;5:179-193.)

consuming, and sensitive to the environment and external factors, said Dr. Rapuano, chief of Wills Eye Cornea Service, and professor of ophthalmology, Sidney Kimmel Medical College, Thomas Jefferson University, Philadelphia.

SUBJECTIVE ASSESSMENT

Some traditional questionnaires used for DED identification include the OSDI, the NEI-VFQ25, IDEEL, and McMonnies Questionnaire. The OSDI is complicated and takes patients a while to complete, Dr. Rapuano noted.

More recent tests are concise. For example, SPEED and the UNC Dry Eye Management Scale are much simpler and easier for patients to take (Figures 3 and 4).

A traditional method of evaluating of the tear film was with Schirmer's I test (without anesthesia), later anesthesia was added with Schirmer's II. This test has moderately variable results and can cause superficial damage to the conjunctiva and cornea. Schirmer's testing also takes 5 minutes—quite a while in the clinic, he added.

Another older test called tear ferning involves the indirect evaluation of mucus in tear film. A small tear sample is collected with a pipette and placed on a glass slide. After 10 minutes, the sample is examined under a light microscope. Normal mucus results in normal ferning. This sort of qualitative analysis is not helpful in the office, but it might have a place in research settings, Dr. Rapuano noted.

TEAR FILM TESTING

Tear breakup time, traditional test, evaluates tear stability. It is done prior to any other drops being in-

Continues on page 18 : Testing

DETECTING DRY EYE: WHAT TO KEEP, OBTAIN, OR OMIT

New diagnostic modalities have enhanced clinical abilities, whereas some standbys still get the job done

By Conni Bergmann Koury; Reviewed by Christopher J. Rapuano, MD

take-home

► Dry eye can be straightforward to determine the etiology for diagnosis and treatment—but not always. Newer diagnostic tools have improved clinicians' ability to treat and follow patients with dry eye.

B

ecause dry eye disease (DED) is a multifactorial disease involving the hypo-secretion of tears and excessive tear evaporation—meibomian gland dysfunction—it can be complicated to identify, said Christopher J. Rapuano, MD.

There is a huge overlap between entities, and signs/symptoms of DED often do not match clinically (Figures 1 and 2).

Some concerns that physicians have regarding DED diagnostic tests are they are often not standardized; there may be no well-accepted universal endpoints for the measure; and many tests are technique-dependent, time-

COMING 2019

Open your eyes to
what's on the
horizon in dry eye.

Sign up for updates at [TearCare.com](https://www.tearcare.com)

TearCare is indicated for the application of localized heat when the current medical community recommends the application of a warm compress to the eyelids. Such applications would include Meibomian Gland Dysfunction (MGD), Dry Eye, or Blepharitis.

©2019 Sight Sciences. All rights reserved. 06221.A



15

TESTING

(Continued from page 16)

stilled or test performed, by placing fluorescein dye with saline in the eye. The patient blinks, and the seconds before a smooth surface is seen are counted. This is a relatively objective, easy, fast, and reproducible diagnostic. It also correlates well with ocular surface disease signs and symptoms, and remains useful in practice, Dr. Rapuano noted.

Corneal fluorescein testing is also non-toxic and fast as well as relatively objective. It reveals significant corneal epithelial damage. This is also an old test that is also still worth doing, he added.

Rose bengal staining, on the other hand, is an older test that is no longer needed, he said. Though a fast and objective way of showing conjunctival damage, it is toxic, painful to the patient, and difficult to obtain, Dr. Rapuano noted.

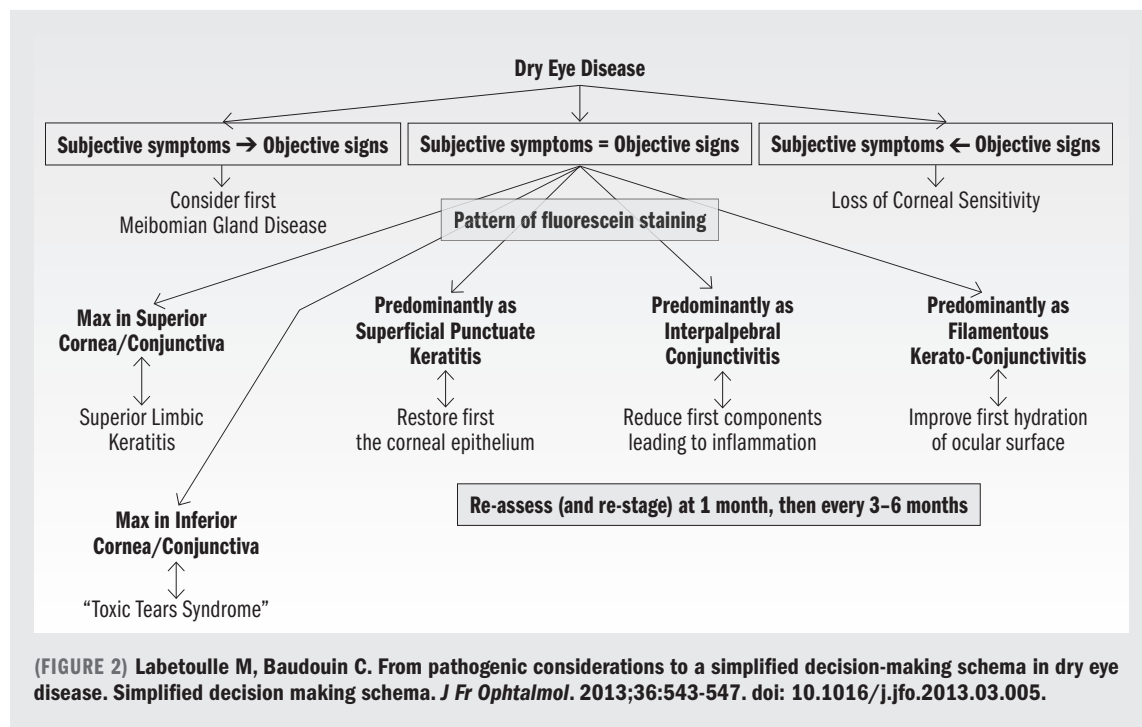
Lissamine green has replaced rose bengal staining; it is also fast, objective, and indicates areas of significant conjunctival epithelial damage. Lissamine is non-toxic, well tolerated, and easy to get, he said.

OSMOLARITY NEWER KID ON THE BLOCK

Tear osmolality in essence looks for excess salt in tears. Higher numbers indicate a more abnormal reading. TearLab is the most widely used test in this arena. It must be performed before other drops and exams are administered, and both eyes must be tested. The osmolality is abnormal when >308 mOsm/L or intereye difference is greater than 8 indicating instability.

The MMP9 test (Quidel) identifies higher levels of this marker of inflammation, indicative of worse DED. TearLab's Discovery test in development will test both osmolality and MMP-9, and the company will be adding inflammatory and perhaps allergy markers in the future.

The LipiView I (Johnson & Johnson Vision) is an older device that measures the thickness of the lipid layer of the tear film. The device



(FIGURE 2) Labetoulle M, Baudouin C. From pathogenic considerations to a simplified decision-making schema in dry eye disease. Simplified decision making schema. *J Fr Ophtalmol.* 2013;36:543-547. doi: 10.1016/j.jfo.2013.03.005.

(FIGURE 3) Standardized Patient Evaluation of Eye Dryness.

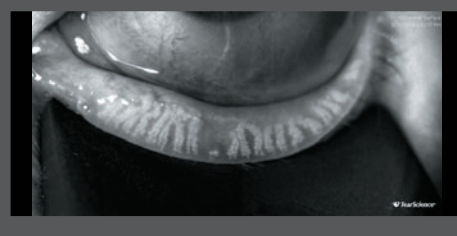(FIGURE 4) UNC Dry Eye Management Scale.

also provides an analysis of partial blinking, which is useful to show and discuss with patients.

IMAGING

LipiView II (TearScience/Johnson & Johnson Vision) provides objective imaging of the meibomian glands, thus giving a window into their health (Figure 5). Oculus Keratograph 5M performs multiple analyses of the tear film as well as tear meniscus, eye redness, meibomian

(FIGURE 5) LipiView II provides objective imaging of the meibomian glands, thus giving a window into their health. (Image courtesy of TearScience/Johnson & Johnson Vision)



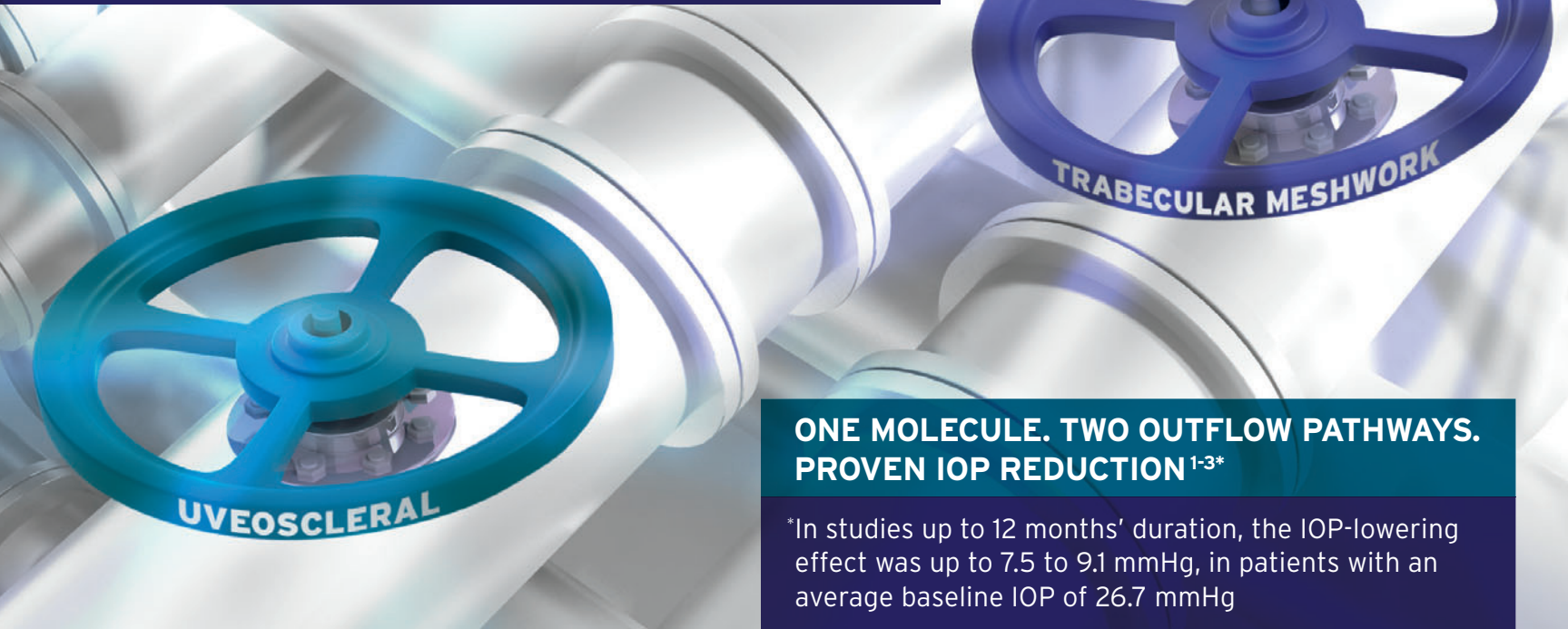
gland imaging, and noncontact tear breakup time. The device generates a report and scale creating what is called a JENVIS dry eye report

(Figure 6), which is meant to provide information on how the factors interact and disease severity.

Continues on page 21 : **Imaging**

VYZULTA DELIVERS A DUAL MECHANISM OF ACTION

FOR THE REDUCTION OF IOP IN GLAUCOMA PATIENTS¹



**ONE MOLECULE. TWO OUTFLOW PATHWAYS.
PROVEN IOP REDUCTION^{1-3*}**

*In studies up to 12 months' duration, the IOP-lowering effect was up to 7.5 to 9.1 mmHg, in patients with an average baseline IOP of 26.7 mmHg

INDICATION

VYZULTA™ (latanoprostene bunod ophthalmic solution), 0.024% is indicated for the reduction of intraocular pressure (IOP) in patients with open-angle glaucoma or ocular hypertension.

IMPORTANT SAFETY INFORMATION

- Increased pigmentation of the iris and periorbital tissue (eyelid) can occur. Iris pigmentation is likely to be permanent
- Gradual changes to eyelashes, including increased length, increased thickness, and number of eyelashes, may occur. These changes are usually reversible upon treatment discontinuation
- Use with caution in patients with a history of intraocular inflammation (iritis/uveitis). VYZULTA should generally not be used in patients with active intraocular inflammation
- Macular edema, including cystoid macular edema, has been reported during treatment with prostaglandin analogs. Use with caution in aphakic patients, in pseudophakic patients with a torn posterior lens capsule, or in patients with known risk factors for macular edema

IMPORTANT SAFETY INFORMATION (CONTINUED)

- There have been reports of bacterial keratitis associated with the use of multiple-dose containers of topical ophthalmic products that were inadvertently contaminated by patients
- Contact lenses should be removed prior to the administration of VYZULTA and may be reinserted 15 minutes after administration
- Most common ocular adverse reactions with incidence $\geq 2\%$ are conjunctival hyperemia (6%), eye irritation (4%), eye pain (3%), and instillation site pain (2%)

For more information, please see Brief Summary of Prescribing Information on next page.

References:

1. VYZULTA Prescribing Information. Bausch & Lomb Incorporated. 2017.
2. Weinreb RN, Sforzolini BS, Vittitow J, Liebmann J. Latanoprostene bunod 0.024% versus timolol maleate 0.5% in subjects with open-angle glaucoma or ocular hypertension: the APOLLO study. *Ophthalmology*. 2016;123(5):965-973.
3. Medeiros FA, Martin KR, Peace J, Sforzolini BS, Vittitow JL, Weinreb RN. Comparison of latanoprostene bunod 0.024% and timolol maleate 0.5% in open-angle glaucoma or ocular hypertension: the LUNAR study. *Am J Ophthalmol*. 2016;168:250-259.

For more information about VYZULTA and how it works, visit vyzultanow.com

BAUSCH + LOMB

VYZULTA and the V design are trademarks of Bausch & Lomb Incorporated or its affiliates.
©2018 Bausch & Lomb Incorporated. All rights reserved. VYZ.0118.USA.18



VYZULTA™
(latanoprostene
bunod ophthalmic
solution), 0.024%

BRIEF SUMMARY OF PRESCRIBING INFORMATION

This Brief Summary does not include all the information needed to use VYZULTA safely and effectively. See full Prescribing Information for VYZULTA.

VYZULTA™ (latanoprostene bunod ophthalmic solution), 0.024%, for topical ophthalmic use.

Initial U.S. Approval: 2017

1 INDICATIONS AND USAGE

VYZULTA™ (latanoprostene bunod ophthalmic solution) 0.024% is indicated for the reduction of intraocular pressure (IOP) in patients with open-angle glaucoma or ocular hypertension.

4 CONTRAINDICATIONS

None

5 WARNINGS AND PRECAUTIONS

5.1 Pigmentation

VYZULTA™ (latanoprostene bunod ophthalmic solution), 0.024% may cause changes to pigmented tissues. The most frequently reported changes with prostaglandin analogs have been increased pigmentation of the iris and periorbital tissue (eyelid).

Pigmentation is expected to increase as long as latanoprostene bunod ophthalmic solution is administered. The pigmentation change is due to increased melanin content in the melanocytes rather than to an increase in the number of melanocytes. After discontinuation of VYZULTA, pigmentation of the iris is likely to be permanent, while pigmentation of the periorbital tissue and eyelash changes are likely to be reversible in most patients. Patients who receive prostaglandin analogs, including VYZULTA, should be informed of the possibility of increased pigmentation, including permanent changes. The long-term effects of increased pigmentation are not known.

Iris color change may not be noticeable for several months to years. Typically, the brown pigmentation around the pupil spreads concentrically towards the periphery of the iris and the entire iris or parts of the iris become more brownish. Neither nevi nor freckles of the iris appear to be affected by treatment. While treatment with VYZULTA™ (latanoprostene bunod ophthalmic solution), 0.024% can be continued in patients who develop noticeably increased iris pigmentation, these patients should be examined regularly [see Patient Counseling Information (17) in full Prescribing Information].

5.2 Eyelash Changes

VYZULTA may gradually change eyelashes and vellus hair in the treated eye. These changes include increased length, thickness, and the number of lashes or hairs. Eyelash changes are usually reversible upon discontinuation of treatment.

5.3 Intraocular Inflammation

VYZULTA should be used with caution in patients with a history of intraocular inflammation (iritis/uveitis) and should generally not be used in patients with active intraocular inflammation as it may exacerbate this condition.

5.4 Macular Edema

Macular edema, including cystoid macular edema, has been reported during treatment with prostaglandin analogs. VYZULTA should be used with caution in aphakic patients, in pseudophakic patients with a torn posterior lens capsule, or in patients with known risk factors for macular edema.

5.5 Bacterial Keratitis

There have been reports of bacterial keratitis associated with the use of multiple-dose containers of topical ophthalmic products. These containers had been inadvertently contaminated by patients who, in most cases, had a concurrent corneal disease or a disruption of the ocular epithelial surface.

5.6 Use with Contact Lens

Contact lenses should be removed prior to the administration of VYZULTA because this product contains benzalkonium chloride. Lenses may be reinserted 15 minutes after administration.

6 ADVERSE REACTIONS

The following adverse reactions are described in the Warnings and Precautions section: pigmentation (5.1), eyelash changes (5.2), intraocular inflammation (5.3), macular edema (5.4), bacterial keratitis (5.5), use with contact lens (5.6).

6.1 Clinical Trials Experience

Because clinical trials are conducted under widely varying conditions, adverse reaction rates observed in the clinical trials of a drug cannot be directly compared to rates in the clinical trials of another drug and may not reflect the rates observed in practice.

VYZULTA was evaluated in 811 patients in 2 controlled clinical trials of up to 12 months duration. The most common ocular adverse reactions observed in patients treated with latanoprostene bunod were: conjunctival hyperemia (6%), eye irritation (4%), eye pain (3%), and instillation site pain (2%). Approximately 0.6% of patients discontinued therapy due to ocular adverse reactions including ocular hyperemia, conjunctival irritation, eye irritation, eye pain, conjunctival edema, vision blurred, punctate keratitis and foreign body sensation.

8 USE IN SPECIFIC POPULATIONS

8.1 Pregnancy

Risk Summary

There are no available human data for the use of VYZULTA during pregnancy to inform any drug associated risks.

Latanoprostene bunod has caused miscarriages, abortion, and fetal harm in rabbits. Latanoprostene bunod was shown to be abortifacient and teratogenic when administered intravenously (IV) to pregnant rabbits at exposures \geq 0.28 times the clinical dose.

Doses \geq 20 μ g/kg/day (23 times the clinical dose) produced 100% embryofetal lethality. Structural abnormalities observed in rabbit fetuses included anomalies of the great vessels and aortic arch vessels, domed head, sternebral and vertebral skeletal anomalies, limb hyperextension and malrotation, abdominal distension and edema. Latanoprostene bunod was not teratogenic in the rat when administered IV at 150 mcg/kg/day (87 times the clinical dose) [see Data].

The background risk of major birth defects and miscarriage for the indicated population is unknown. However, the background risk in the U.S. general population of major birth defects is 2 to 4%, and of miscarriage is 15 to 20%, of clinically recognized pregnancies.

Data

Animal Data

Embryofetal studies were conducted in pregnant rabbits administered latanoprostene bunod daily by intravenous injection on gestation days 7 through 19, to target the period of organogenesis. The doses administered ranged from 0.24 mcg/kg/day. Abortions occurred at doses \geq 0.24 mcg/kg/day latanoprostene bunod (0.28 times the clinical dose, on a body surface area basis, assuming 100% absorption). Embryofetal lethality (resorption) was increased in latanoprostene bunod treatment groups, as evidenced by increases in early resorptions at doses \geq 0.24 mcg/kg/day and late resorptions at doses \geq 6 mcg/kg/day (approximately 7 times the clinical dose). No fetuses survived in any rabbit pregnancy at doses of 20 mcg/kg/day (23 times the clinical dose) or greater. Latanoprostene bunod produced structural abnormalities at doses \geq 0.24 mcg/kg/day (0.28 times the clinical dose). Malformations included anomalies of sternum, coarctation of the aorta with pulmonary trunk dilation, retroesophageal subclavian artery with absent brachiocephalic artery, domed head, forepaw hyperextension and hindlimb malrotation, abdominal distention/edema, and missing/fused caudal vertebrae.

An embryofetal study was conducted in pregnant rats administered latanoprostene bunod daily by intravenous injection on gestation days 7 through 17, to target the period of organogenesis. The doses administered ranged from 150 to 1500 mcg/kg/day. Maternal toxicity was produced at 1500 mcg/kg/day (870 times the clinical dose, on a body surface area basis, assuming 100% absorption), as evidenced by reduced maternal weight gain. Embryofetal lethality (resorption and fetal death) and structural anomalies were produced at doses \geq 300 mcg/kg/day (174 times the clinical dose). Malformations included anomalies of the sternum, domed head, forepaw hyperextension and hindlimb malrotation, vertebral anomalies and delayed ossification of distal limb bones. A no observed adverse effect level (NOAEL) was established at 150 mcg/kg/day (87 times the clinical dose) in this study.

8.2 Lactation

Risk Summary

There are no data on the presence of VYZULTA in human milk, the effects on the breastfed infant, or the effects on milk production. The developmental and health benefits of breastfeeding should be considered, along with the mother's clinical need for VYZULTA, and any potential adverse effects on the breastfed infant from VYZULTA.

8.4 Pediatric Use

Use in pediatric patients aged 16 years and younger is not recommended because of potential safety concerns related to increased pigmentation following long-term chronic use.

8.5 Geriatric Use

No overall clinical differences in safety or effectiveness have been observed between elderly and other adult patients.

13 NONCLINICAL TOXICOLOGY

13.1 Carcinogenesis, Mutagenesis, Impairment of Fertility

Latanoprostene bunod was not mutagenic in bacteria and did not induce micronuclei formation in the *in vivo* rat bone marrow micronucleus assay. Chromosomal aberrations were observed *in vitro* with human lymphocytes in the absence of metabolic activation.

Latanoprostene bunod has not been tested for carcinogenic activity in long-term animal studies. Latanoprost acid is a main metabolite of latanoprostene bunod. Exposure of rats and mice to latanoprost acid, resulting from oral dosing with latanoprost in lifetime rodent bioassays, was not carcinogenic.

Fertility studies have not been conducted with latanoprostene bunod. The potential to impact fertility can be partially characterized by exposure to latanoprost acid, a common metabolite of both latanoprostene bunod and latanoprost. Latanoprost acid has not been found to have any effect on male or female fertility in animal studies.

13.2 Animal Toxicology and/or Pharmacology

A 9-month toxicology study administered topical ocular doses of latanoprostene bunod to one eye of cynomolgus monkeys: control (vehicle only), one drop of 0.024% bid, one drop of 0.04% bid and two drops of 0.04% per dose, bid. The systemic exposures are equivalent to 4.2-fold, 7.9-fold, and 13.5-fold the clinical dose, respectively, on a body surface area basis (assuming 100% absorption). Microscopic evaluation of the lungs after 9 months observed pleural/subpleural chronic fibrosis/inflammation in the 0.04% dose male groups, with increasing incidence and severity compared to controls. Lung toxicity was not observed at the 0.024% dose.

Distributed by:

Bausch + Lomb, a division of

Valeant Pharmaceuticals North America LLC

Bridgewater, NJ 08807 USA

U.S. Patent Numbers: 6,211,233; 7,273,946; 7,629,345; 7,910,767; 8,058,467.

VYZULTA is a trademark of Bausch & Lomb Incorporated or its affiliates.

© Bausch & Lomb Incorporated

Based on 9464800 11/2017 VYZ.0055.USA.16 Issued: 11/2017

Brimonidine therapy well tolerated for treatment of dry eye disease

Phase II proof-of-concept study indicates efficacy signals at day 28 and day 84

By **Steve Lenier**; Reviewed by **Parag A. Majmudar, MD**

A PRESERVATIVE-FREE nanoemulsion formulation containing brimonidine tartrate 0.2% (BRI) (OCU310, Ocugen) may be a potential treatment for the relief of signs and symptoms of dry eye disease (DED), according to Parag A. Majmudar, MD. A phase II proof-of-concept study has shown BRI may be a safe, well-tolerated, and effective alternative to existing dry eye therapy.¹

STUDY RESULTS

The results showed tolerability scores were high and similar across treatment groups and study visits, said Dr. Majmudar, who is in private practice, and associate professor of ophthalmology, Rush University, Chicago. There was no statistically significant difference in tolerability between each treatment group and the placebo group at the day 84 visit, which met the pre-specified primary endpoint.

The study was not powered to determine efficacy, but it did demonstrate efficacy signals for BRI, both with and without loteprednol etabonate ophthalmic solution 0.2% (LOT), across several exploratory efficacy endpoints. For both the monotherapy and combination ther-

apy groups there was a statistically significant reduction in ocular discomfort (as measured by the SANDE score), as early as the day 28 visit, and there were strong reductions in lissamine green staining of the conjunctiva and cornea (LGSCC). These results were consistent with the mechanism of action of brimonidine.

There were few adverse events (AEs) in the study, and they were split evenly across the treatment groups. For all three arms the AEs were mild, and consistent with product labels for active, placebo, and preservative (BAK). IOP measurements remained within normal range for all subjects in all treatment groups.

PHASE III STUDIES

The study also determined the formulation, duration, and endpoints for phase III studies. Because no appreciable difference in efficacy was observed between the monotherapy and combination therapy groups, there is no benefit to including LOT or other topical steroids in the BRI formulation to be used in phase III studies.

The study findings support further investigation into BRI monotherapy for the relief

of signs and symptoms of DED. The phase III studies will be performed using:

- A preservative-free, steroid-free nanoemulsion formulation containing BRI (0.2%)
- Primary endpoints to include SANDE (for symptoms) and LGSCC (for signs)
- Day 28 as the primary efficacy assessment visit. ■

Reference

1. Jorgensen D, Zangler N, Majmudar P. A phase II randomized, placebo-controlled, double-masked, proof-of-concept study of brimonidine (BRI) eye drops for the treatment of dry eye disease (DED). Poster presented at: American Academy of Ophthalmology Annual Meeting; 2018 Oct 27–30; Chicago, IL.



PARAG A. MAJMUDAR, MD

E: pamajmudar@chicagoocornea.com

This article was adapted from a poster presentation at the 2018 meeting of the American Academy of Ophthalmology. Dr. Majmudar

was an investigator in the Ocugen-sponsored phase II proof-of-concept study and is a paid consultant for Ocugen.

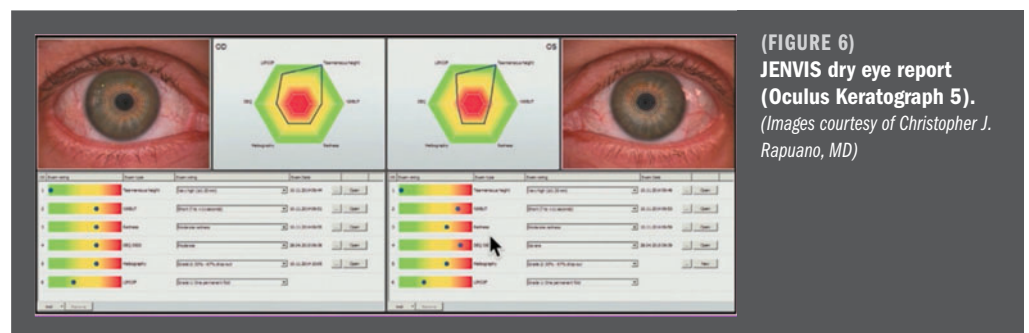IMAGING

(Continued from page 18)

High-resolution anterior-segment optical coherence tomography (Optovue, Cirrus) can objectively evaluate tear film meniscus/tear volume.

SYSTEMIC DISEASE

Traditional testing for Sjögren's syndrome includes blood tests (ESR, RF, CBC, anti-SSA and -SSB and ANA) that can be nonspecific. Bausch + Lomb's Sjo test combines these biomarkers plus novel, proprietary ones, and can reportedly detect disease at an earlier stage. Dr. Rapuano notes he finds this test most helpful as backup



(FIGURE 6) JENVIS dry eye report (Oculus Keratograph 5). (Images courtesy of Christopher J. Rapuano, MD)

when referring a patient to a rheumatologist.

Dry eye can be straightforward to determine the etiology in order to diagnose and treat—but not always. Newer diagnostic tools have improved clinicians' ability to treat and follow patients with DED. ■

CHRISTOPHER J. RAPUANO, MD

E: cjrapuano@willseye.org

This article was adapted from Dr. Rapuano's presentation during Cornea Subspecialty Day at the 2018 meeting of the American Academy of Ophthalmology. He is a consultant to TearLab.

Pinpoint underlying blepharitis, dry eye causes for best outcomes

First treat pre-existing conditions, such as medication toxicity, eyelid disease

By Lynda Charters; Reviewed by Bennie H. Jeng, MD

DRY EYE DISEASE delivers a powerful punch worldwide, with from 5% to 30% of individuals affected, and the majority are women.

Moderate-to-severe forms of the disease can result in a 60% decrease in patient quality of life, which is on par with conditions such as severe angina, dialysis and hip fractures, and it is associated with high rates of anxiety and depression.

The annual cost to the U.S. healthcare system is almost \$4 billion. Dry eye results from a number of different etiologies and exhibits different types and subtypes, making treatment challenging, according to Bennie H. Jeng, MD.



Dr. Jeng

“When we treat dry eye, we don’t want to treat just the end result of dryness, but also the root causes if possible,” said Dr. Jeng, professor and chairman, Department of Ophthalmology and Visual Sciences, University of Maryland School of Medicine, Baltimore. “This is why it is important to understand the intricate and complicated mechanisms of dry eye.

“If you just prescribe artificial tears, the root of the problem is often ignored,” Dr. Jeng said. He advises correcting the underlying conditions, such as medication toxicity, corneal exposure from nocturnal lagophthalmos, eyelid disease, and stem cell deficiency.

A LOOK AT DRY EYE TREATMENT

After addressing the underlying conditions, lubrication with preservative-free artificial tears and punctal occlusion are appropriate.

“Punctal occlusion should be done after the ocular surface has been optimized because inserting plugs in a patient with poor-quality tears does not help the eye,” he noted.

If the plugs do work, but they keep falling out, punctal cautery can be considered.

Aside from artificial tears, another product that improves lubrication is autologous serum/plasma.

“Because few randomized controlled trials of autologous eye drops have been performed, the meta-analyses have stated that no definitive conclusions can be reached about the benefits of the treatment,” he said. “However, for those of us who use them, we find anecdotally that they really work for the right patients.”

In addition, tear evaporation can be ameliorated by reminding patients to blink frequently and avoid air streams from forced air heating and cooling systems conditioners. Sometimes, wrap-around glasses or goggles can also be effective.

For patients who do not respond adequately to standard treatments, clinicians can dig deeper into their bag of potential therapies.

The inflammatory cascade in dry eye can be treated with steroids (loteprednol, prednisolone, dexamethasone, and fluorometholone) and cyclosporine which is available commercially in a 0.05% concentration, with newer concentrations coming, and it can also be compounded in other concentrations such as 0.5% or 1%, he said.

Lifitegrast 5% is a newer steroid-sparing drug that can also be used.

Steroids play an important role, especially when treatment is first initiated before transitioning patients to cyclosporine or lifitegrast. The steroid-sparing agents tend to be more suitable for mild to moderate dry eye cases but may not work as well in more severe cases,

he noted.

“Treatment with amniotic membrane also has been suggested,” Dr. Jeng commented, but he has no personal experience with it.

Scleral lenses, while not new, have recently become more popular for treating various types of ocular surface diseases, and they should be considered for treating dry eyes. These lenses

range from mini-scleral lenses 13 to 16 mm in diameter to regular ones that are 17.5 mm or larger. These lenses provide a fluid reservoir, are comfortable for most patients, and provide better vision. Most of the time, fitting these

‘If you just prescribe artificial tears, the root of the problem is often ignored.’ — Bennie H. Jeng, MD

requires a collaboration between ophthalmologists and optometrists. The Mayo Clinic (Schornack et al. *Ophthalmology* 2014;121:1398-405) reported that the commercially available scleral lenses provide significant and immediate improvement in the ocular surface and vision.

The PROSE lens (BostonSight), which can range from 17.5 to 24.0 mm in diameter, also works well. This is custom manufactured, and so subsequently more expensive and requires specific fitting expertise, he noted.

NEW, DEVELOPING DRY EYE TREATMENTS

“This is a very exciting time in the development of new products,” Dr. Jeng said.

Some of the newer products include intranasal tear neurostimulation (TrueTear, Allergan), which is FDA approved, and provides a temporary increase in tear production, and amniotic membrane extract.

Crosslinked hyaluronic acid drops are being developed for wound healing and managing punctate epitheliopathy.

MEIBOMIAN GLAND DISEASE

Almost one-half of ophthalmic patients have blepharitis, which also significantly impacts quality of life. The condition is characterized by chronic eyelid inflammation and is asso-

take-home

► Dry eye and blepharitis have myriad causes and require individualized therapy.

Special Report) UPDATE IN TREATMENT OF **DRY EYE & OCULAR ALLERGY**

OT OphthalmologyTimes.com
Online Exclusive

'REELING IN THE SHARK'

GROWING UP IN LOUISIANA, "I was once taken fishing for small sharks on the Gulf Coast," writes Melissa Toyos, MD. "As I stood on the beach, I remember experiencing the sudden revelation that if I succeeded in hooking a shark, the next step would be to reel it in to me. By my own efforts, I would go from being happy on the beach to being face to teeth with a dangerous shark."

Go to OphthalmologyTimes.com/Shark

ciated frequently with symptoms of ocular surface irritation and dry eye. Just as with dry eye, blepharitis has many causes.

Importantly, Dr. Jeng cautioned, there is no single approach that works in managing blepharitis and he cautions patients that there is no cure.

"For me, the endpoint is patient comfort," he said. "In many cases, the eyes will look the same over an extended period, but if patients start to feel better, that is what matters."

The first step in management is removing punctal plugs if they are present, as the tear film might not be optimized. Dr. Jeng may culture the lids to identify bacteria that is aggravating the ocular surface and eyelids.

He advises patients to use more than warm washcloth compresses on the lids and suggests microwaving rice in a sock, bean bags, and gel packs to achieve sufficient warmth. Eyelid wipes are now available for use in conjunction with standard washcloth compresses.

Medical treatment includes topical antibiotics, metronidazole and azithromycin; topical steroids; and oral doxycycline, all of which are effective. Oral azithromycin at doses of 1 gram weekly for 3 weeks or 500 mg daily for 3 days and dietary supplementation with omega-3s, fish oil, or flaxseed oil also provide relief.

Blepharitis in children is a serious condition as it can result in corneal scarring and visual loss. As such, it must be treated aggressively both topically and systemically, Dr. Jeng cautioned.

Topical therapy consists of brief bursts of steroids, but the mainstay of treatment centers around oral therapy with doxycycline (if older than 7 years) or erythromycin (if younger than 7 years).

Other treatments include meibomian gland probing, thermal pulsation, intense pulsed-light therapy, and topical testosterone.

A newer therapy (TearCare System, Sight Sciences) provides thermal energy to the meibomian glands to stimulate oil expression.

Demodex is an often overlooked because of blepharitis that should be looked for, and it can be treated with tea tree oil, metronidazole gel, and even oral ivermectin (Stromectol, Merck). ■

BENNIE H. JENG, MD

E: bjeng@som.umaryland.edu

This article was adapted from Dr. Jeng's presentation at the 2018 meeting of the American Academy of Ophthalmology. Dr. Jeng has no relevant financial interest in any aspect of this report.

The One and Only Indicator of MMP-9 for Dry Eye Inflammation



InflammADry



InflammADry is the only test that detects elevated levels of MMP-9, a key inflammatory marker for dry eye. This rapid, point-of-care test produces results in 10 minutes allowing patients to be tested and treated in the same office visit. The test is easy to perform, is minimally invasive and requires no additional equipment. InflammADry utilizes innovative patented technology, is CE marked, and CLIA waived.

Quidel is a long-standing leader in the manufacture and sale of rapid, point-of-care diagnostics. Contact your Quidel Account Manager today at **800.874.1517** to learn more about how InflammADry can help improve the health of your dry eye patients.

Visit us at **ASCRS San Diego**
Booth 643, May 3-7

quideleyehealth.com

Special Report) UPDATE IN TREATMENT OF DRY EYE & OCULAR ALLERGY

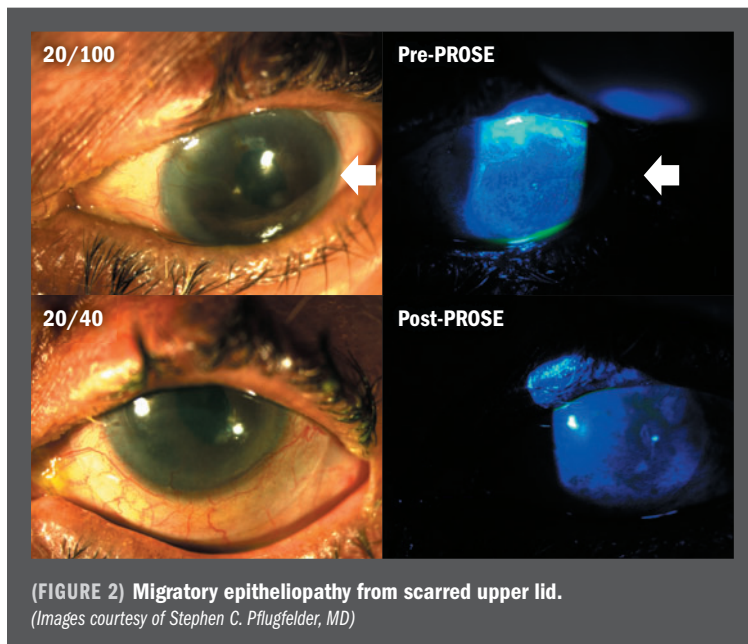
OCULAR SURFACE

(Continued from page 1)

These improvements, in turn, expanded therapeutic indications to encompass vision correction for irregular corneas as well as protection and hydration in various eye diseases, according to Dr. Pflugfelder.

More recent advances include:

- ▶ greater array of materials with Dk values ranging from 80 to 143 and increased wettability of the coatings;
- ▶ more options for pre-fabricated lenses;
- ▶ innovative custom designs; and
- ▶ expanded therapeutic indications, such as extended wear for non-healing epithelial defects and neurotrophic ulcers and use of these devices to deliver antibiotics, corticosteroids, and blood products.



(FIGURE 2) Migratory epitheliopathy from scarred upper lid. (Images courtesy of Stephen C. Pflugfelder, MD)

COMPLEX CORNEAL CASES

One advance in prosthetic scleral device technology—prosthetic replacement of the ocular surface ecosystem (BostonSight PROSE)—has changed the management of many ocular surface diseases, Dr. Pflugfelder said.

He highlighted several cases in which the treatment was effectively used, such as a patient with congenital seventh nerve palsy and exposure keratopathy, and another patient with a non-healing neurotrophic epithelial defect following herpes zoster that recurred despite three amniotic membrane transplants but healed in about 1 month after the patient began wearing a scleral contact lens and has remained healed.

Other cases include that of a patient with

probable trachoma with superior tarsal scarring and limbal stem cell dysfunction. After the eye was fitted with a scleral lens, the migratory epitheliopathy from the scarred upper lid was replaced with a smooth corneal epithelium, and acuity improved from 20/100 to 20/40.

In a fourth case, an international patient with a cicatricial disease and hand-motion visual acuity bilaterally began wearing a scleral device filled with autologous platelet-rich plasma. In just 9 months, his corneas cleared significantly and the patient now has functional visual acuity.

Another new technology uses a three-dimensional model of the eye to fabricate a lens that matches the contours of the patient's cornea and sclera (EyePrintPRO, EyePrint Prosthetics).

“We now have the ability . . . to fit difficult eyes like those with filtering blebs,” he said.

Dr. Pflugfelder turned to this transparent prosthetic scleral device for a patient who had monocular vision following a chemical injury. Treatment had included a tube shunt and a scleral patch graft inferiorly, but the epithelium kept breaking down. Ultimately, this device was successfully placed over the scleral patch.

The prosthetic scleral cover was also utilized in a patient with Stevens-Johnson syndrome who had undergone therapeutic penetrating keratoplasty and implantation of a superior tube shunt. When a scleral lens impinged on the temporal conjunctiva, a colleague of Dr. Pflugfelder's fitted the

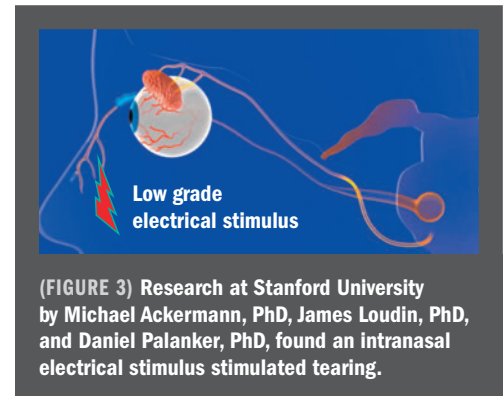
prosthetic scleral cover over the tube shunt, resulting in a much more comfortable outcome.

NEUROSTIMULATION

Nasal neurostimulation is one of the newest strategies for managing dry eye, Dr. Pflugfelder said.

“It's been known that Schirmer test combined with nasal stimulation can stimulate reflex tearing, and if we anesthetize the nostrils there's about a 34% decrease in tear production in normal subjects,” he said.

Neural signaling of tear secretion may be disrupted in dry eye by corneal anesthesia, anticholinergic medications, autoantibodies to acetylcholine receptors, inflammatory cytokines, and lymphocytic infiltration of the



lacrimal gland, and reflex tearing may be lost due to conditions such as Sjögren's syndrome, Stevens-Johnson syndrome, graft versus host disease, and trigeminal nerve damage.

Searching for ways to stimulate natural tear production, Stanford University researchers found that a low-grade intranasal electrical stimulus could initiate the reflex loop and cause lacrimal secretion. This finding led to the development

of what is now known as the TrueTear device (Allergan), included in the company's 2015 acquisition of Oculeve.

By inserting the disposable silicone nasal prongs on this small rechargeable device, patients can temporarily increase tear production in the inferior tear meniscus.

This approach also gives patients more control of their therapy, Dr. Pflugfelder said

Evidence supporting the concept of nasal stimulation includes an open-label pilot study

of 40 patients who used the nasal stimulator 4 times a day for 180 days. Improvement in clinical signs and symptoms, such as increased tear production and decreased irritation symptoms, continued up to six months.

Dr. Pflugfelder also noted that in addition to stimulating aqueous tear production, the neurostimulation device increases conjunctival goblet cell degranulation. ■

STEPHEN C. PFLUGFELDER, MD

P: 713/798-4732 E: stevenp@bcm.edu

This article was adapted from Dr. Pflugfelder's presentation during Cornea Subspecialty Day at the 2018 meeting of the American Academy of Ophthalmology. Dr. Pflugfelder is a consultant/advisor to Allergan, Senju, and Shire. He has also received grant support from Shire.

take-home

▶ New devices and technology continue to flow from the lab to the ophthalmology practice, radically changing the management or conceal of ocular surface diseases. Nasal neurostimulation is among the newest strategies and has been shown to increase production of natural tears.

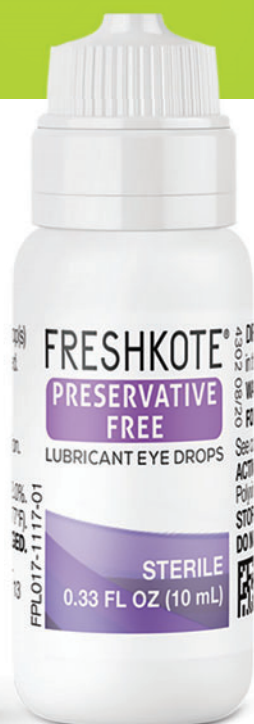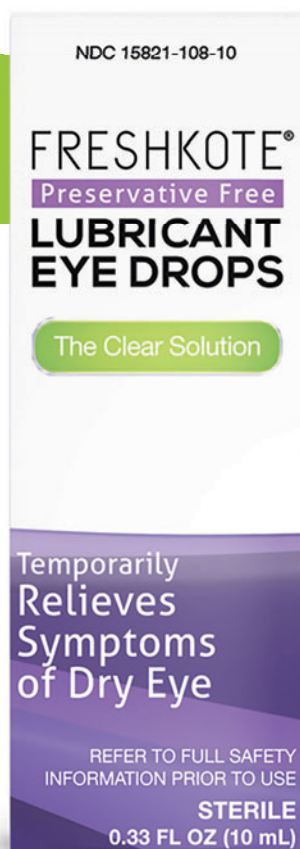
FRESHKOTE®

Preservative Free
LUBRICANT EYE DROPS

**NEW and
IMPROVED**

FRESHKOTE® PF is now available— preservative-free in a multidose bottle

- ✓ For temporary relief of dry eye symptoms¹
- ✓ Unique phospholipid blend combats tear evaporation¹
- ✓ Gentle, preservative-free drops can be used with contact lenses^{1,2}
- ✓ Exclusive patented formulation
- ✓ State-of-the-art Novelia® multidose bottle dispenses drops with precision³



For more information,
visit **FRESHKOTEPF.com**

References: **1.** FRESHKOTE Drug Facts. Eyeavance Pharmaceuticals LLC; 2018. **2.** Fuller DG, Connor CG. Safety and efficacy of FRESHKOTE® used as a rewetting agent in Lotrafilcon-A® contact lens wearers. Poster presented at: American Academy of Optometry Annual Meeting; November 17-20, 2010; San Francisco, CA. **3.** Nemera. Novelia®. <https://nemera.net/products/ophthalmic-novelias-eyedropper/>. Accessed December 4, 2018.

NOW AVAILABLE
FROM

eyeavance[™]
pharmaceuticals

© 2019 Eyeavance Pharmaceuticals LLC. All rights reserved.
FRESHKOTE® is a registered trademark of Eyeavance Pharmaceuticals LLC.
Novelia is a registered trademark of Nemera Development.
FRE-009 02/2019

Phase II study shows potential for first-in-class dry eye treatment

BRM421 safe, well tolerated in controlled adverse environment model

By Vanessa Caceres

IN A PHASE II STUDY, BRM421 significantly improved signs and symptoms in patients with moderate to severe dry eye, said Uma Prabhakar, PhD.

The 29-amino acid synthetic peptide is derived from pigment epithelium-derived factor, according to Dr. Prabhakar, independent consultant, Blue Bell, PA.

The secreted glycoprotein has several known biologic effects, including promotion of tissue regeneration at the ocular surface.

This kind of derivative has been shown to promote growth and expansion of limbal epithelial stem cells after wounds in both mice and rabbits, Dr. Prabhakar noted.

Both toxicology studies and in vitro research with BRM421 has had encouraging results. When used in rabbits and dogs, no ocular or systemic effects were seen after 28 days with use of the planned clinical dose.

“Essentially, the cornea, conjunctiva, and sclera were normal,” Dr. Prabhakar said. The agent also was not observed in systemic circulation.

The phase II multicenter, double-masked, clinical study with BRM421 included 157 subjects with dry eye. All subjects used a controlled adverse environment model. For one week, patients were given a placebo, and then they were randomly assigned to receive BRM421 or a placebo control for three times a day bilaterally for 28 days. Researchers monitored signs and symptoms at days 1, 8, 15, and 29.

“The number of adverse events between treatment and placebo were very similar,” Dr. Prabhakar said. “There were no significant adverse events and no withdrawals due to adverse events associated with administration.”

DIVING DEEPER

There were changes in pre- and post-Ocular Surface Disease Index scores, but they were not significant.

“However, with respect to secondary endpoints, almost all were numerically in favor of BRM421, and some were statistically significant,” Dr. Prabhakar said.

At visit five—about 50 days into treatment—BRM421 prolonged tear break-up time and re-

lieved burning and dryness. There also was improved visual function for reading and working with a computer observed as early as visit three.

The results appear to indicate early onset of action, Dr. Prabhakar said.

When focusing on a subanalysis of moderate to severe patients, mean changes in staining significantly improved after BRM421 use ($p = 0.0248$). This occurred at 10 to 12 days post-treatment.

“In the same population, we also saw that BRM421 relieved dryness, and this again was as early as visit three,” she said.

BRM421 is a first-in-class potential dry eye treatment and has early onset of action for corneal healing and tear film break-up time improvement. The therapy has potential to control damage-associated molecular pattern-induced inflammation and subsequent tissue edema, Dr. Prabhakar concluded. ■

take-home

► In a phase II study, treatment with BRM421 was safe and could potentially treat visual function fluctuation among dry eye patients.

UMA PRABHAKAR, PHD

This article was adapted from Dr. Prabhakar's presentation at the 2018 meeting of the American Academy of Ophthalmology. Dr. Prabhakar is an independent consultant at Uma Prabhakar Consulting LLC, Philadelphia. She did not indicate any relevant financial disclosures.

Study: Significant results through 12 months with eyelid technology

A NEWLY published single-center, prospective clinical study (*Clinical Ophthalmology*. 2019;13:189-198) provides preliminary evidence that re-treatment with a novel technology (TearCare System, Sight Sciences) is a safe and effective treatment for dry eye disease, according to a prepared statement issued by the company.

The wearable, open eye, and fully customizable eyelid technology provides targeted adjustable thermal energy to the meibomian glands, according to the company.

The system is indicated for use in meibomian gland dysfunction, dry eye, and blepharitis,

but is not yet cleared by FDA for the treatment of the signs and symptoms of dry eye disease.

A large, prospective, multicenter, randomized controlled trial will begin enrolling in the first quarter of 2019.

In this continuation of the initial 6 month, single-center, pilot clinical trial that was published in 2017, twelve patients were re-treated after the 6-month follow-up, and continued to experience a significant improvement in all dry eye signs (tear breakup time (TBUT), corneal and conjunctival staining, and meibomian gland scores) and symptoms (SPEED, OSDI, and SANDE) through 12 months.

At a one-month clinic visit following re-treatment, the primary signs endpoint (TBUT) increased by 12.4 (± 3.3) seconds ($p < 0.001$) over baseline.

On dry eye symptoms, subjects had a reduction in SPEED scores after the second TearCare treatment from a baseline score of 15.7 \pm 5.2 to a final score of 7.9 \pm 6.7 ($p = 0.004$ compared with day 0) six months later.

The study findings concluded TearCare provided long-term improvement in the signs and symptoms of dry eye disease, according to the statement. ■

Topical hematopoietic therapy viable option for ocular surface disease

Study and use of platelet preparation, other biologics viewed as next frontier

By Cheryl Guttman Krader; Reviewed by Victor L. Perez, MD

TOPICAL HEMATOPOIETIC therapy has been shown to be a safe, effective modality for the treatment of severe ocular surface disease (OSD) and may become an option for a broader group of patients through future innovations that could improve accessibility, said Victor L. Perez, MD.

“Hematopoietic therapy with autologous serum tears has been moving up the ladder in the stepwise treatment algorithm for OSD, but the indications are still somewhat limited,” said Dr. Perez, professor of ophthalmology, and director, Foster Center for Ocular Immunology, Duke University School of Medicine, Durham, NC. “Increased use of this or another blood-derived biologic modality will depend on developments that make it more physician- and patient-friendly.”

The study and use of platelet preparation and other biologics are our next frontier for achieving this goal, he added.

The use of serum to treat OSD was first described in 1975 by Ralph et al., and in 1984, Fox et al. first reported on the efficacy of autologous serum tears as a tear substitute. The

understood,” Dr. Perez said. “As another advantage, there are no preservatives in autologous serum tears.”

Evidence from a growing number of publications allay concerns about potential risks accompanying the use of autologous serum tears when the product is prepared correctly.

“In addition, we showed in a recently published study that while the biochemical composition of serum in patients with systemic autoimmune diseases may be altered, autologous serum tears was a safe and effective adjunctive treatment in this patient population,” Dr. Perez said.

NAVIGATING ROADBLOCKS

Accessibility, cost, and local regulatory and legislative restrictions remain barriers for greater use of autologous serum tears.

However, sources for preparation of autologous serum tears are increasing, and although the product is not covered by insurance, Dr. Perez proposed the idea that closed systems could be developed to enable in-office preparation.

“If the ophthalmologist could control the

“Lack of standardization of the preparation procedure remains a problem in the United States,” Dr. Perez said. “It has been achieved in South Korea, however, where allogeneic serum tears are now covered by government insurance, and allogeneic blood-derived products are being successfully used in Denmark.”

take-home

▶ **Autologous serum tears are safe and effective for treating ocular surface disorders and may become more accessible in the future.**

LOOKING AHEAD

Fractions and components in blood other than serum and its contents might also be used to develop a hematopoietic therapy for OSD.

Platelet-rich plasma (PRP), which contains numerous growth factors, has been used for over a decade to facilitate healing by multiple surgical specialties, including orthopedic, oral and maxillofacial, reconstructive, cardiovascular, and plastic surgery.

“PRP has only been used more recently in ophthalmology, but the results are very promising,” Dr. Perez said. “Compared with autologous serum, PRP has a higher content of vitamins and growth factors, anti-inflammatory and wound healing components.”

In addition, the platelets can secrete growth factors and adhere to the ocular surface, forming a clot. Therefore, PRP can facilitate healing by both biomechanical and biological mechanisms, he added.

As an example, Dr. Perez and his colleagues have used the fibrin clot derived from plasma rich in growth factors to promote epithelial wound healing of the cornea in a patient with partial limbal stem cell deficiency.

“The future is bright for the development of hematopoietic products for patients with OSD,” Dr. Perez concluded. ■



Dr. Perez

‘If ophthalmologists could control the cost, autologous serum tears might become an option for more patients.’ – Victor L. Perez, MD

therapeutic benefit of autologous serum tears is explained by the fact that serum contains a host of epitheliotropic factors, including growth factors, immunoglobulins, vitamins, and substance P.

“There are probably other elements in autologous serum tears that benefit the ocular surface through mechanisms that are not yet

cost, autologous serum tears might become an option for more patients,” he said.

Preparation of serum tears from allogeneic sources offers another alternative for increasing availability of hematopoietic therapy, but a standardized method for production is needed to reduce risks and for obtaining insurance coverage.

VICTOR L. PEREZ, MD

P: 919/681-3937

This article was adapted from Dr. Perez's presentation during Cornea Subspecialty Day at the 2018 meeting of the American Academy of Ophthalmology. Dr. Perez disclosed financial interests in Cambium Medical Technologies and OBT Inc.

For Products & Services and Recruitment advertising information, contact:
Joanna Shippoli at 800-225-4569, ext 2615 • Fax 440-756-5271 • Email: joanna.shippoli@ubm.com

PRODUCTS & SERVICES

BILLING SERVICES

Exclusive Ophthalmology Billers
 Expert Ophthalmology Billers
 Excellent Ophthalmology Billers
 Triple E = Everything gets paid



P.M. Medical Billing Corp
 EXCLUSIVE OPHTHALMOLOGY BILLING AND CONSULTING

100%

On Shore

Ophthalmology & Optometry Billing.

The First Original Exclusive Ophthalmology and Optometry National Billing and Consulting Company.

With 28 years of experience and over 45 medical billers plus who are certified Ophthalmic Techs, Ophthalmic assistants, Fundus photographers who also dual certified ophthalmic coders and billers. Proud to be an Executive of American Academy of Ophthalmology. Our clinical background and knowledge in Ophthalmology billing is second to none. That equates into a dramatic increase in your revenue. No more Bundling down coding, or denials.

We do not outsource your billing overseas. All billing done in our office in the U.S.A.

- Our In house Credentialing and Re-Credentialing Dept. Another added benefit as well as patient billing to increase revenue included in our services.
- Experts in Forensic Billing and old A/R clean up.
- Totally HIPA Compliant.
- We can offer you our own Practice Management software at no cost to you or we can VPN into your system if that's what you prefer.

Practice Management we work on:

NexTech, NexGen, MD Office, Medisoft, Advanced MD, Azalea, Cerner, Office Mate, TCMS, Revolution, Management Plus, QRS, Medware, Dr. Chrono, Centricity, Intergy, Echo, Care Cloud, eclinical, Allscripts, ADS and many more...

Our collection rate is consistently much higher than our competitors that results in a much higher revenue stream for your practice.

All of our clients are receiving the Mips bonus for the year.

Fee schedule analysis.

Our staff has years of Attendance at the AAO and ASCRS and attends all ongoing Ophthalmology billing and Practice Management continuing education classes. We are always knowledgeable and prepared for all government and commercial changes.

Call for free on site consultation. We will travel to you anytime to evaluate you're A/R and show you how we can increase your revenue.

Our Prestigious National Ophthalmology Clients reference list will be provided at your request.

PM Medical Billing will keep an EYE on your Billing so you can keep an EYE on your patients.

Call toll free at **1-888-PM-BILLING (1-888-762-4554)**

Email: info@pmbiller.com • Web: www.pmbiller.com • 24 hours: **516-830-1500** or **516-780-2895**



FOCUSED MEDICAL BILLING
 A FULL SERVICE MEDICAL BILLING FIRM SPECIALIZING IN OPHTHALMOLOGY

Focused Medical Billing is a full service medical billing firm servicing all specialties of Ophthalmology. With our firm our focus is to maximize our client's revenue and dramatically decrease denials by utilizing over 20 years of Ophthalmology billing/coding experience and expertise. Our firm provides accurate clean claim submissions on first submissions with relentless A/R follow up to obtain a 98% collection rate that so many of our clients enjoy.

Services Include:

- Expert Coders: Billing to Primary, Secondary & Tertiary insurance companies
 - A/R Clean Up and analysis
 - Patient Billing
- Posting of all Explanation of benefits
- Credentialing & Re-Credentialing
 - Eligibility
- Fee Schedule Analysis
 - Monthly Reports
- No long term commitment or contract required
 - 100% HIPAA Compliant
 - Stellar letters of reference

Call us today for your free, no obligation consultation

Ph: 855-EYE-BILL ext. 802

Email: amay@focusedmedicalbilling.com • Web: www.focusedmedicalbilling.com

"You're focused on your patients, we're focused on you"

PRACTICE FOR SALE

Ophthalmology Practice for Sale

Located in Eastern PA
 Equidistant between Phila and NYC
 Area with colleges and local theater
 Contact **Practice Administrator**
 Phone: **610-275-4065**

Email: centurybusinessservicesinc501@gmail.com

Narrow your candidate
 search **to the best.**

Place a recruitment ad in
Ophthalmology Times —
 in print or online.

Joanna Shippoli

Account Manager | 440-891-2615
joanna.shippoli@ubm.com

Ophthalmology Times

Recruitment Advertising Can Work For You!

Reach highly-targeted, market-specific business professionals, industry experts and prospects by placing your ad here!

PRODUCTS & SERVICES

BILLING SERVICES

ECBC
EYE CARE BILLING CONSULTANTS

SEE YOUR PROFITS MORE CLEARLY

Ophthalmology & Optometry Billing Only
New York City based
25 years of experience

eyecarebillingconsultants.com
contact@eyecarebillingconsultants.com
(646) 828-8889

ADVERTISE NOW!

Combine
Ophthalmology Times
Marketplace
print advertising with
our online offerings
to open up unlimited
potential.



Narrow your candidate search
to the best.

Place a recruitment ad in *Ophthalmology Times* —
in print or online.

Joanna Shippoli
Account Manager | 440-891-2615
joanna.shippoli@ubm.com

Ophthalmology Times

Swept-source OCT provides clinical advantages

SS-OCT can scan entire posterior segment in seconds, provide high-fidelity image

By Netan Choudhry, MD; Victor H. Gonzalez MD; and David Pelayes, MD Special to Ophthalmology Times

It is imperative that retinal specialists keep abreast of the latest advances in clinical and diagnostic technology. One key area is optical coherence tomography (OCT), where the relatively recent advent of swept-source OCT (SS-OCT) technology affords us the opportunity to image the retina and choroid faster and in greater detail.

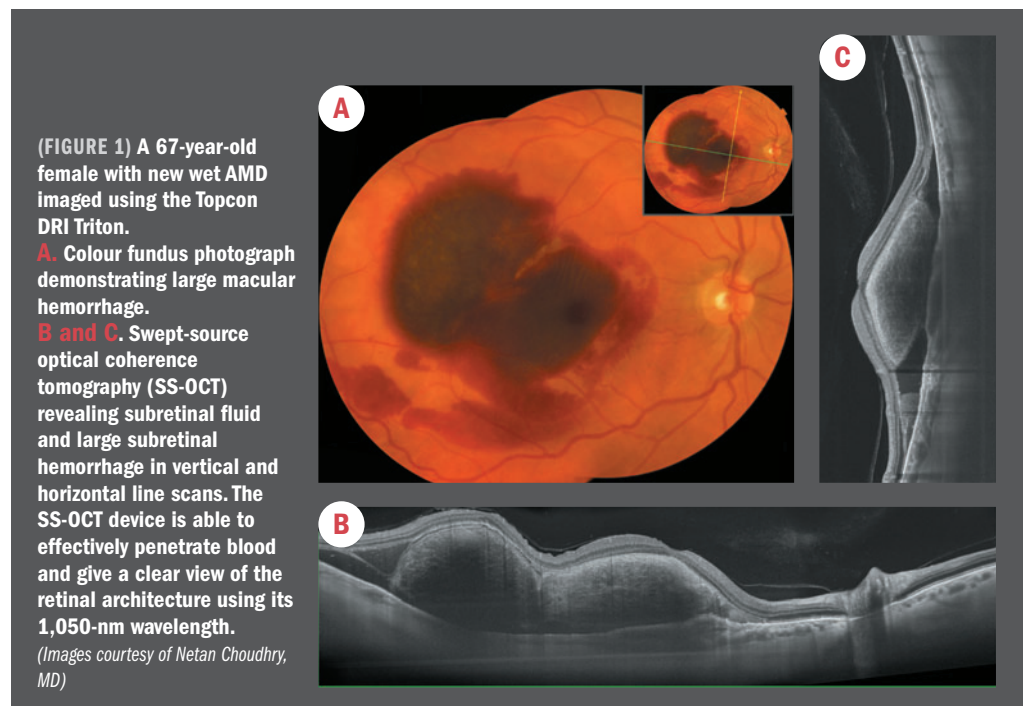
Unlike spectral-domain OCT, SS-OCT can scan the entire posterior segment in seconds and provide an extremely high-fidelity image. Certain anatomical elements of the eye—such as the sclera, choroid, and Bruch's membrane—are now possible to visualize in high definition, giving us more insight into the complex factors at play when retinal disease is present.

SS-OCT devices produce high-quality images even in the presence of challenging media, such as blood from a neovascular hemorrhage. This allows for more specificity prior to diagnosis, especially when imaging patients whose disease manifestation tends to be serious, such as diabetic patients, or patients with cataracts or macular holes.¹

A recent study assessed the utility of SS-OCT in visualizing macular hole closure through gas-filled eyes, determining that swept source facilitated consistent early visualization of foveal architecture for assessment of hole closure in gas-filled eyes.²

Another potential benefit is in patients with peripheral retinal disease, who are difficult to diagnose due to lack of compliance during imaging. By using a subvisible 1,050-nm wavelength, SS-OCT helps improve patient comfort, reduce noncompliance and achieve a higher quality image. Patients with diabetic disease, who frequently present with higher incidences of moderate to severe disease and often progress quickly, may also benefit.³

SS-OCT produces an image of very high quality in almost any situation where it would not have been possible using older technology. It is very useful in the diabetic population, where



serious disease, rapid progressions and complications are prevalent.

SS-OCT devices reduce the physical footprint required to establish an imaging suite in-office considerably, and improve the patient experience. Our device of choice (DRI OCT Triton, Topcon Medical Systems) is comfortable for patients and integrates with our electronic medical records.

If you see a large volume of patients who present with significant or challenging posterior segment disease, it is worth considering updating your OCT system to a swept-source model. ■

References

1. Choudhry, Netan et al. Seeing through walls: Subhyaloid hemorrhage. *Ophthalmology*. 2016;123: 6:1172.
2. Li, Daniel & Choudhry, Netan. Swept-Source OCT visualization of macular hole closure in gas-filled eyes. *Ophthalmic Surgery, Lasers and Imaging Retina*. 2017;48:392-398.

3. Van Leiden HA, Dekker JM, Moll AC, Nijpels G, Heine RJ, Bouter LM, et al. Risk factors for incident retinopathy in a diabetic and nondiabetic population: the Hoorn study. *Arch Ophthalmol*. 2003;121:245-251.

NETAN CHOUDHRY, MD, FSCRC

E: netan.choudhry@vrmto.com

Dr. Choudhry is the founder and medical director of the Vitreous Retina Macula Specialists of Toronto and is an active researcher and publisher in the area retinal imaging and the diagnosis of rare retinal disorders. Dr Choudhry did not indicate any proprietary interest in the subject matter.

VICTOR GONZALEZ, MD

E: ysalinas@vribx.com


Dr. Gonzalez founded Gulf Coast Eye Institute in 2007, where he continues to practice and serve the Rio Grande Valley in Texas. He is an active clinical researcher and frequently publishes in ophthalmic medical journals. Dr Gonzalez did not indicate any proprietary interest in the subject matter.

DAVID PELAYES, MD

E: davidpelayes@gmail.com

Dr. Pelayes is a professor of ophthalmology at Buenos Aires University in Argentina, associate professor of ophthalmology at Maimonides University, Argentina, and professor ESASO, Lugano University, Switzerland. Dr Pelayes did not indicate any proprietary interest in the subject matter.

Let Us Be Your *Eyes and Ears*



Introducing EyePod: Podcasts from *Ophthalmology Times*

This new audible resource from *Ophthalmology Times* engages with key opinion leaders in interviews about the latest innovations in the areas of surgery, clinical diagnosis, pharmaceutical advancements, research, and technology, plus practice management.

Hear the voices of ophthalmic innovation.

OphthalmologyTimes.com/EyePod

Community-based screening programs promising for glaucoma

Early disease detection could reduce vision loss, especially in underserved populations

By Laird Harrison

SCREENING IN COMMUNITY venues could reduce the vision-loss associated with glaucoma, according to L. Jay Katz, MD.

“It really can be an effective way of identifying patients with glaucoma and other sight-threatening diseases,” said Dr. Katz, chief of the Wills Eye Glaucoma Service, Philadelphia.

“As our population is aging there has been reference to the tsunami of chronic disease that’s going to hit us, and part of that is glaucoma,” said Dr. Katz, citing a projected 40% increase in glaucoma prevalence in the next decade.

Glaucoma is particularly common in underserved populations, and is the leading cause of blindness among African-American and Hispanic people in the United States, he added.

Early detection could significantly reduce this vision loss, he said, and could save money because the disease is less expensive to manage in its early stages.

“Historically, screening for glaucoma has been met with very little success,” he said.

He offered the example of a program in the 1950s that screened about 10,000 factory workers. Only about 2% were identified as glaucoma suspects. Not only have the screening programs failed to find much glaucoma, they have not been able to treat most of the cases identified.

As a result, in 2013 the U.S. Preventative Services Task Force (USPSTF), reviewing the track record of glaucoma screening found that “the overall certainty of the evidence is low, and the USPSTF is unable to determine the balance of benefits and harms of screening for glaucoma in asymptomatic adults.” It also warned of a risk of overtreatment.

DIVING DEEPER

The American Academy of Ophthalmology issued a rebuttal, arguing among its other points that everyone with the disease should be treated to prevent severe consequences in a minority, and pointed out that vision loss affects daily activities and quality of life. Previous screening efforts have fallen short of their objectives

largely because they have not reached high-risk populations, he said.

He also cited other barriers to glaucoma care including patients’ lack of knowledge about the risk, lack of trust, lack of access to eye-care providers, need for multiple follow-ups once treatment is initiated, poor adherence to glaucoma medication, language, transportation, and lack of insurance and other funds to pay for care.

To test approaches for overcoming these barriers, the U.S. Centers for Disease Control and Prevention (CDC) and Wills Eye have conducted two initiatives to reach underserved populations in Philadelphia, one using mobile eye care and the other using telemedicine.

MOBILE PROGRAM

The mobile program sought to identify and engage African Americans 50 years of age and older, and other residents of underserved communities aged 60 years and older who were most vulnerable to glaucoma, and to provide educational workshops, eye examinations, and follow-up treatments at community sites.

Transporting their equipment in a van, the providers gave 30-minute presentations including a 10-minute video and the offer to review brochures in Spanish, Mandarin, and Russian. They also offered glaucoma-screening appointments. Surveys showed that the presentations increased participants’ knowledge about glaucoma.

The education program was successful and as word spread, more people came for screenings than had attended the education sessions. Of the 1,506 scheduled initially, 1,081 attended and an additional 598 walked in.

Examinations included slit-lamp exams, IOP measurement, visual field testing, and optic nerve/fundus photos. The clinicians diagnosed new glaucoma in 4%, existing glaucoma in 6.6%, suspected glaucoma in 21.4% and ana-

tomically narrow angles in 12%. Another 4% had cataracts, age-related macular degeneration, diabetic retinopathy, or dry eye.

The clinicians recommended eye drops or laser therapy for glaucoma, and laser therapy for anatomically narrow angles. They recommended follow-ups for suspected glaucoma and referred everyone else to local eye doctors. Follow-up adherence to these recommendations was 61.2%.

In the telemedicine project, 7,200 people were identified by electronic records as being in high risk populations and invited to a screening at their primary care offices. Five hundred forty of these patients, along with 365-walk-in patients underwent fundus photography of the optic nerve and macula and tests of visual acuity and IOP, and provided their medical and family histories in primary-care offices.

Of the 905 people screened, 540 had abnormal or unreadable images, or ocular hypertension and were referred to full eye exams, also in the primary-care offices, or fast tracked to local ophthalmologists. Four hundred nineteen participated in these follow-up appointments, with 338 of them continuing into the second phase of the study.

Of the 338, 80.5% were diagnosed with an eye condition, including 161 with suspected glaucoma, 35 with glaucoma, and the others with narrow angles, ocular hypertension, diabetic retinopathy, neuropathology, and other pathologies.

Overall the screening exam agreed with the follow-up exams in 86.3% of cases. The program was cost-effective, since researchers estimated the costs per patient at \$9.77, Dr. Katz said. ■

TAKE-HOME

► **Screening in community venues could reduce the vision loss associated with glaucoma, and is an effective way of identifying patients with glaucoma and other sight-threatening diseases.**

L. JAY KATZ, MD

E: ljaykatz@gmail.com

This article was adapted from Dr. Katz’s presentation at the 2019 Glaucoma 360 meeting of the Glaucoma Research Foundation. He did not indicate any financial interests relevant to the subject matter.

Weigh what's best for practice when selling to private equity

Practice buy-outs are on the rise; for some, can be alluring option with diligent research

By Laird Harrison

Ophthalmologists face difficult decisions when approached by private equity firms, according to Ruth D. Williams, MD. Selling to these firms has both advantages and disadvantages, said Dr. Williams, chief executive officer of Wheaton Eye Clinic based in Wheaton, IL.

She gave an overview of the thinking of 12 ophthalmologist friends in eight states who are mulling private equity buy-outs.

"There is a lot of money outside the stock market and not enough places to put it," she said.

Wealthy private investors, pension funds, and college endowments are among those entities hoping for a 20% return through private equity funds, she said.

Such investors have increasingly looked to physicians' practices, often hoping to slash the practice's costs, consolidate with other practices and resell the new practice at a profit, Dr. Williams said.

Private equity is rapidly spreading in medicine, she said.

Dermatology practices were among the first purchased and often the new investors often cut costs by replacing dermatologists with physician assistants.

About 26% of ophthalmologists are in solo practices, making them attractive targets for such investors, Dr. Williams said.

The number of firms investing in ophthalmology increased from 1 in 2012 to 13 in 2017, she said. In 2018, 20 firms invested in ophthalmology by October.

The managers appointed by private equity firms value practices on the basis of earnings before interest, taxes, depreciation, and amortization (EBITA). They are likely to put profits ahead of quality, she said.

But if that makes a private equity sale sound unattractive, ophthalmologists should think hard before ruling out the possibility, said Dr. Williams, who has herself received a offer of a private equity buy-out.

It can appeal to ophthalmologists who are concerned about getting cash out of their own practices, particularly when it comes time to retire.

"People want cash," she said. "They want a buy-out at the end of one's career."

Sometimes junior partners are not able or not willing to buy out the senior partners, or to invest in growth, she said.

Private equity can also appeal to ophthalmologists interested in growing their practices.

"The assumption we're making in today's healthcare environment is that bigger is better," Dr. Williams said.

Ophthalmologists may also want help from managers who can focus on the administrative side of the practice, allowing the ophthalmologists to focus on treating patients.

"I've been the machine behind this practice for nearly 30 years," one of Dr. Williams' friends told her. "I'm tired. Let someone else steer this ship."

But the ophthalmologists she surveyed also worry that the culture of their practices would change, and that new management would not treat long-time employees well. They worry also that partners will become less committed if they no longer own a

stake, and that the practices will become less attractive to talented candidates.

Dr. Williams also asked her friends how younger partners are reacting to the possibility of a sale to private equity.

'People want cash. They want a buy-out at the end of one's career.' — Ruth D. Williams, MD

The younger partners face a much bigger impact from these sales, she said, and they are also divided in their thinking.

They, too, are intrigued by the possibility of being able to focus on ophthalmology rather than management, especially as the health care environment becomes more complex, Dr. Williams' friends reported. But the junior partners also do not want to give up control or equity, and fear that the practice's core values won't be respected.

Anyone contemplating such an offer should study it closely and talk to multiple firms, Dr. Williams concluded.

"Once you start to drill down into these deals, they are all different," one of her friends told her. ■

TAKE-HOME

► **Ophthalmologists face difficult decisions when approached by private equity firms. Ruth D. Williams, MD, explains why selling to these firms has both advantages and disadvantages.**

RUTH D. WILLIAMS, MD

E: ruthwilliamsx@wheaton.com

This article was adapted from Dr. Williams' presentation at the 2019 Glaucoma 360 meeting of the Glaucoma Research Foundation. She did not indicate any proprietary interest relevant to the subject matter.

Chin up, don't let the Yelpers get you down!



“You’re a great doctor! You can’t let one 2-star Yelp review get you down.”

Artwork by Jon Carter

in case you missed it

Insights on laser cataract surgery **PAGE 11**

New treatments in dry eye and blepharitis **PAGE 22**

Swept-source OCT provides advantages **PAGE 31**

Should you sell to a private equity firm? **PAGE 33**

+ Laser cataract surgery uses expand
OPHTHALMOLOGYTIMES.COM/LASER

7 pearls for pediatric keratoplasty
OPHTHALMOLOGYTIMES.COM/KERATOPLASTYPEARLS

Advertiser Index

Advertiser	Page
ALCON LABORATORIES www.alcon.com 800/862-5266	12-13
BAUSCH + LOMB www.bausch.com 800/227-1427	19-20
EYEVANCE www.eyevance.com 817/677-6120	25
IMPRIMIS PHARMACEUTICALS www.imprimisrx.com 844/446-6979	CV3
JOHNSON & JOHNSON VISION www.vision.abbott	CV2
NUSIGHT	CV4
OCUSOFT www.ocusoft.com 800/233-5469	15
OMEROS CORP. www.omeross.com	5
QUIDEL www.quidel.com 800/874-1517	23
SHIRE OPHTHALMIC www.shire-eyes.com 800/828-2088	7-9
SIGHT SCIENCES	17

This index is provided as an additional service. The publisher does not assume any liability for errors or omissions.

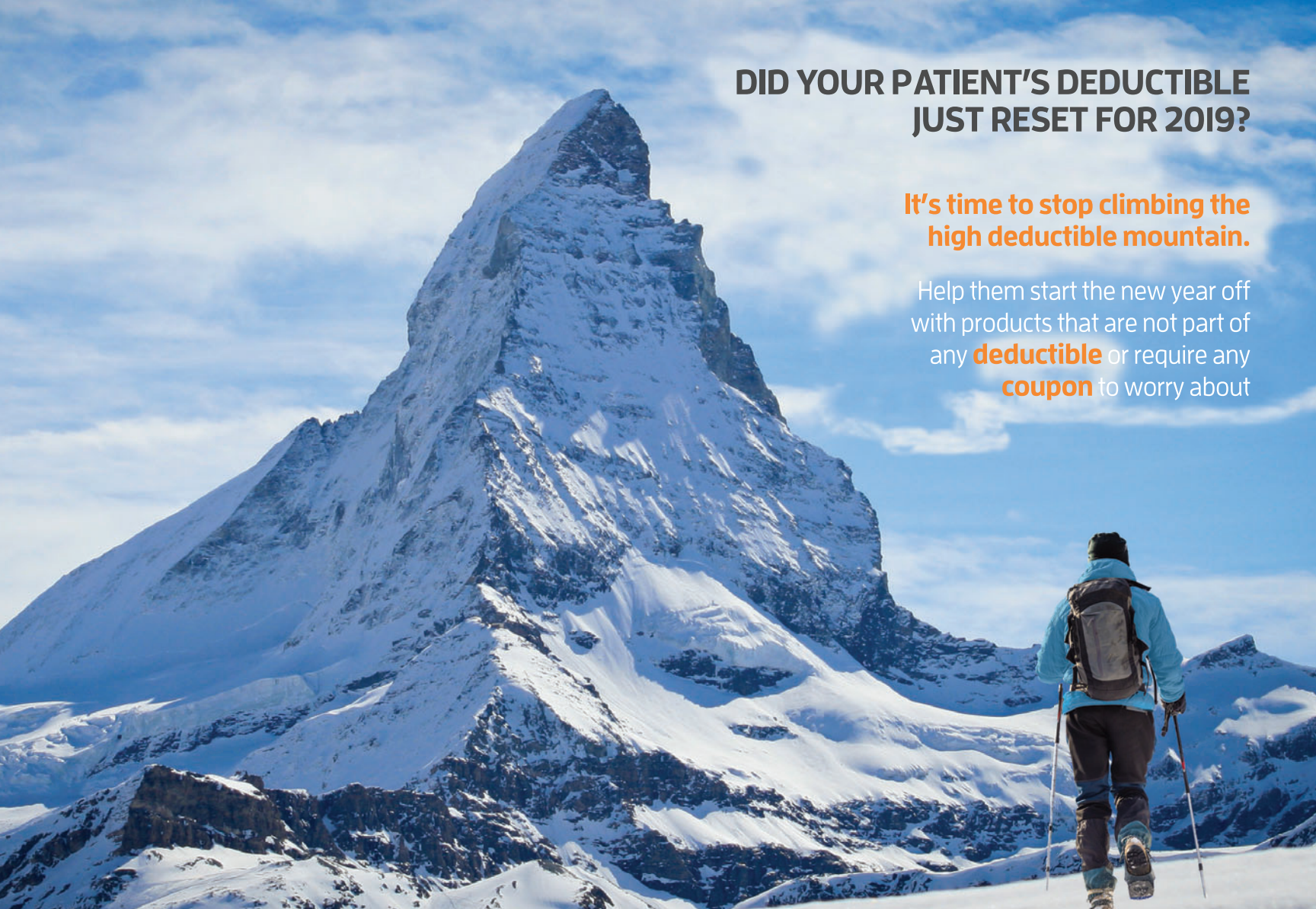
OPHTHALMOLOGY TIMES (Print ISSN 0193-032X, Digital ISSN 2150-7333) is published semimonthly except for one issue in Jan, May, Aug and Dec (20 issues yearly) by UBM LLC 325 W 1st St STE 300 Duluth MN 55802. Subscription rates: \$200 for one year in the United States & Possessions, Canada and Mexico; all other countries \$263 for one year. Pricing includes air-expedited service. Single copies (prepaid only): \$13 in the United States & Possessions, Canada and Mexico; \$20 all other countries. Back issues, if available are \$25 in the U.S. \$ Possessions; \$30 in Canada and Mexico; \$35 in all other countries. Include \$6.50 per order plus \$2 per additional copy for U.S. postage and handling. If shipping outside the U.S., include an additional \$10 per order plus \$5 per additional copy. **Periodicals postage paid** at Duluth, MN 55806 and additional mailing offices. **POSTMASTER:** Please send address changes to OPHTHALMOLOGY TIMES, P.O. Box 6009, Duluth, MN 55806-6009. Canadian G.S.T. number: R-124213133RT001, Publications Mail Agreement Number 40612608. Return undeliverable Canadian addresses to: IMEX Global Solutions, PO Box 25542 London, ON N6C 6B2 CANADA. Printed in the U.S.A.

© 2019 UBM. All rights reserved. No part of this publication may be reproduced or transmitted in any form or by any means, electronic or mechanical including by photocopy, recording, or information storage and retrieval without permission in writing from the publisher. Authorization to photocopy items for internal/educational or personal use, or the internal/educational or personal use of specific clients is granted by UBM for libraries and other users registered with the Copyright Clearance Center, 222 Rosewood Dr. Danvers, MA 01923, 978-750-8400 fax 978-646-8700 or visit <http://www.copyright.com> online. For uses beyond those listed above, please direct your written request to Permission Dept. fax 732-647-1104 or email: Jillyn.Frommer@ubm.com

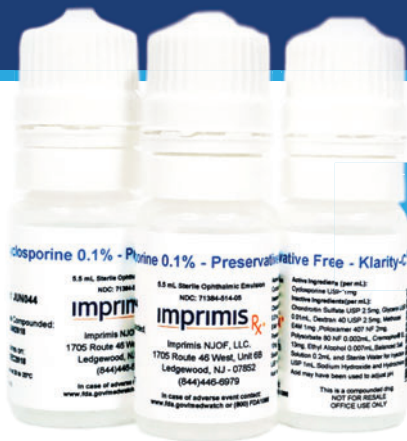DID YOUR PATIENT'S DEDUCTIBLE JUST RESET FOR 2019?

It's time to stop climbing the high deductible mountain.

Help them start the new year off with products that are not part of any **deductible** or require any **coupon** to worry about



ONE LOW MONTHLY PAYMENT*



\$50 a month!*
(ships in packs of 3)

TOTALTEARS®

Klarity-C Drops™
Cyclosporine 0.1% / Chondroitin Sulfate Ophthalmic Emulsion**
(preservative-free) 5.5mL Bottles

No Prior Authorizations | No Coupons | No Pharmacy Call Backs

[CLICK HERE TO ORDER](#)

*Automatic refill setup required to enroll in our monthly payment program. Monthly pricing listed above is based on a single bottle. Monthly payment plan is not a discount program. Patient is responsible for the full cost of the medication, paid in monthly increments, reflecting single bottle price.

**For professional use only. Imprimis Pharmaceuticals specializes in customizing medications to meet unique patient and practitioner needs. Imprimis Pharmaceuticals dispenses only to individually identified patients with valid prescriptions. No compounded medication is reviewed by the FDA for safety or efficacy. Imprimis Pharmaceuticals does not compound copies of commercially available products. References available upon request. Total Tears, Klarity-C Drops, ImprimisRx are trademarks of Imprimis Pharmaceuticals, Inc. ©2018 Imprimis Pharmaceuticals, Inc. All Rights Reserved. IMP00349 01/19 As of 01.09.2019

imprimis Rx®
844.446.6979



NuLids™ – transformational dry eye therapy



Transforms your patients' lives

Finally... A doctor-directed at-home treatment for dry eye disease that is safe, effective and easy to use.

A multi-center study¹ showed:

- 50% decrease in dry eye symptoms
- 65% improvement in TBUT
- 80% increase in meibomian glands yielding liquid secretions.

¹ Schanzlin, Olkowski, Coble, Gross. NuLids II Study, April 2018



Transforms your practice

The NuLids System helps reduce patient out-of-pocket expenses while creating an additional revenue stream for the practice – all without impacting overhead costs or disrupting other in-office treatments.

A multi-center study¹ showed 95% were satisfied or very satisfied with the treatment.

For more information visit www.NuSightMedical.com or call us at 833-468-5437



NuLids™

Doctor prescribed, at-home dry eye relief

