

Clear Corneal Incision Architecture Imaging after Torsional Phacoemulsification of Hard Nuclear Cataract through a 2.2 mm and a 3.0 mm Large Tunnel

Xixia Ding^{1,2}, Pingjun Chang^{1,2}, Giacomo Savini³, Jinhai Huang^{1,2}, Qinmei Wang^{1,2}, Huayou Lin^{1,2}, Qian Zheng^{1,2}, Yinying Zhao^{1,2} and Yun'e Zhao^{1,2}

¹School of Optometry and Ophthalmology and Eye Hospital, Wenzhou Medical College, Wenzhou, Zhejiang, China

²Key Laboratory of Vision Science, Ministry of Health P.R. China, Wenzhou, Zhejiang, China

³G.B. Bietti Foundation IRCCS, Rome, Italy

Abstract

Purpose: To compare the morphological characteristics and the wound edema degree of clear-cornea microincisions and small-incisions for hard cataract removal.

Setting: The Eye Hospital of Wenzhou Medical College.

Design: Prospective randomized study.

Methods: Fifty eyes from 36 consecutive patients with hard cataract were included. They were randomized to have phacoemulsification through a clear-cornea microincision (2.2 mm, n=25) or small-incision (3.0 mm, n=25). Anterior segment optical coherence tomography evaluation was performed preoperatively and postoperatively, including wound architecture and incisional corneal thickness (ICT).

Results: Endothelial gaping was more common in the 2.2 mm group than in the 3.0 mm group at 2 hours (48 vs 12%) and 1 week (28 vs 12%) postoperatively, although the statistical difference was significant only at 2 hours. There was no statistically significant difference between the two groups in the incidence of epithelial gaping, local detachment of Descemet's membrane, loss of coaptation, and posterior wound retraction. At 2 hours and 1 week after surgery, the mean ICT_a was slightly higher in 3.0 mm group (52.1±12.5% and 46.4±12.3%, respectively) than in 2.2 mm group (51.4±11.6% and 40.6±15.1%, respectively), with no statistically significant differences. On the contrary, the ICT_s was statistically higher in 3.0 mm group than 2.2 mm group at 1 month (16.8±10.0% vs 10.2±5.8%, P = 0.007) and 3 months (12.1±8.1% vs 6.0±4.5%, P = 0.002).

Conclusion: In hard cataract phacoemulsification, microincisions increase the risk of endothelial gaping in the early postoperative period, compared to small incisions. However, they induce a lower amount of corneal edema.

Keywords: Optical coherence tomography; Torsional phacoemulsification; Hard nuclear cataract; Microincision; Small-incision; Wound architecture; Edema

Introduction

Clear corneal incisions (CCIs), first introduced by Fine^a in 1992, and are commonly used during phacoemulsification. Gaping and leaking of the main wound were found during retrospective analysis of CCIs in cases of postoperative endophthalmitis [1,2]. Hard nucleus removal may further increase the risk of wound damage, since it requires more ultrasound energy and time than usual cases [3]. In order to reduce wound and corneal endothelial injury, the torsional mode has been introduced [3]. The system uses a dedicated hand piece to produce side-to-side rotary oscillations of the phaco tip [3]. Compared to the jackhammer motion in conventional phaco, the torsional oscillation shears the lens material with virtually no repulsion and reduces chatter of lens material and thereby improve the efficiency and safety of the procedure [4-6]. A previous study has shown that it can reduce the ultrasound time (UST) and cumulative dissipated energy (CDE) [3]. When combined to the Ozil IP software of the Infinity Vision System (Alcon Laboratories, Inc.), the torsional mode has been reported to require less occlusion time and balanced salt solution, particularly with denser cataracts [7]. This might also reduce the damage to the corneal wound.

^aFine IH (1992) Self-Sealing Corneal Tunnel Incision for Small-Incision Cataract Surgery. Ocular Surgery News May 1, pages 38-39.

Coaxial microincision cataract surgery (MICS) has become very popular in recent years. Smaller incisions lead to less iatrogenic astigmatism, less intraoperative and postoperative inflammation, and less time for visual recovery [8]. Moreover, they also result in greater wound stability, and corneal aberrations reduction [9]. However, the smaller incision technique may increase the likelihood of the undesirable thermal and mechanical effects of the phaco tip on the incision site [10], due to the higher friction between the tip and the incision. For the same reason, with a larger incision relative to the tip size, there is a greater tendency for leakage around the tip, which produces some cooling effect [11].

The availability of anterior segment optical coherence tomography (AS-OCT) allows noninvasive assessment and visualization of CCIs

*Corresponding author: Yun'e Zhao, MD, Eye Hospital of Wenzhou Medical College, 270, West Xueyuan Road, Lucheng District, Wenzhou, Zhejiang, China, Tel: +86 577 88068859; Fax: +86 577 88832083; E-mail: zye@mail.eye.ac.cn

Received April 23, 2013; Accepted May 18, 2013; Published May 22, 2013

Citation: Ding X, Chang P, Savini G, Huang J, Wang Q, et al. (2013) Clear Corneal Incision Architecture Imaging after Torsional Phacoemulsification of Hard Nuclear Cataract through a 2.2 mm and a 3.0 mm Large Tunnel. J Clin Exp Ophthalmol 4: 279. doi:10.4172/2155-9570.1000279

Copyright: © 2013 Ding X, et al. This is an open-access article distributed under the terms of the Creative Commons Attribution License, which permits unrestricted use, distribution, and reproduction in any medium, provided the original author and source are credited.

architecture and has been used for this purpose by many studies [2,10,12-14]. Using this technology, CCI edema after hard nucleus cataract removal through micro- (1.8 and 2.2 mm) and small-incision (3.0 mm) has been previously assessed, but the authors of the study in question used the conventional ultrasound (US) mode and did not evaluate torsional phacoemulsification. Nor did they assess the architectural integrity of the corneal wound [15].

The goal of this paper was to investigate by means of AS-OCT whether the different size of CCIs affects the postoperative wound architecture integrity and edema in eyes that underwent phacoemulsification for hard nucleus cataract using the torsional mode and the Ozil IP system.

Patients and Methods

Patients

This prospective study was approved by the Research Review Board at Wenzhou medical College. Practices and research were in accordance with the tenets of the Declaration of Helsinki, and informed consents were obtained from all the patients after explanation.

This was a prospective randomized study of cataract surgery with intraocular lens (IOL) implantation from March, 2010 to April, 2011. All cases were examined and underwent surgery at the Eye Hospital of Wenzhou Medical College (Zhejiang Wenzhou, China). This study included 50 eyes (36 consecutive patients) with nuclear cataract harder than grade 4 according to the Lens Opacities Classification System III [16]. All eyes were randomly assigned (using a list of computer-generated random numbers at the time of arranging the surgical date) to receive MICS (2.2 mm, Group 1) or small-incision coaxial cataract surgery (3.0mm, Group 2).

Eyes were excluded in the presence of any corneal pathology, glaucoma, uveitis, retinal detachment and diabetic retinopathy, ocular trauma and in case of previous surgery. Further exclusion criteria were preoperative center endothelial cell density (CECD) < 1800/mm², corneal astigmatism more than 1.5D, any intraoperative complication (such as posterior capsular rupture), and postoperative infection. In addition, patients who did not cooperate during any examination or failed to follow up within 3 months were all excluded.

Surgical technique

All eyes had phacoemulsification and IOL implantation through a CCI. The whole surgical procedure was performed by the same experienced surgeon (Y.E.Z) using topical anesthesia. The main CCI, single-plane, was made along the 120 degrees meridian (at 11 o'clock position, in the supero-temporal quadrant of the right eye, and in the supero-nasal quadrant of the left eye). Then the side port incision was created along the 0 degree meridian (at 3 o'clock position, on the nasal side of the right eye, and on the temporal side of the left eye). The Infiniti Vision System with the Ozil IP software (Alcon Laboratories Inc, Fort Worth, TX) was used for phacoemulsification. This software requires torsional modality only. In case of a significant vacuum rise caused by occlusion, the software automatically applies a series of alternating torsional and longitudinal pulses to clear the occlusion. The system will return to all torsional after the vacuum level drop [7].

Table 1 shows the surgical instruments and phacoemulsification setting for both groups. A 1-piece acrylic foldable IOL (Acrysof, Alcon Laboratories, Inc) was implanted into the capsular bag without incision enlargement. At the end of the surgery, the incision was sealed by stromal hydration without sutures. The values of UST and CDE were

recorded from the screen of the phaco system. UST, in seconds, is defined as the total time that U/S (or Ozil) is used. CDE is related to the total amount of energy. In the conventional mode, CDE it is calculated as follows: CDE=average U/S power×U/S time. In the torsional mode, CDE is calculated as follows: Torsional amplitude×Torsional time×0.4 [3]. Therefore, in the torsional mode with IP software, it is calculated as follows:

$$CDE = (\text{average U/S power} \times \text{U/S time}) + (\text{Torsional amplitude} \times \text{Torsional time} \times 0.4).$$

Surgical settings for the 2 groups were different (Table 1).

Patient examination

Before surgery, all eyes underwent the following examinations: uncorrected distant visual acuity, slit-lamp microscopy, intraocular pressure by non-contact tonometer (Canon TX-F, Japan), dilated fundus examination and lens nucleus hardness grading, axial length measurement by contact A-scan (Axis II PR,) or IOL-Master 5.0 (Carl Zeiss, Germany), corneal astigmatism measurement by IOL-Master 5.0 (Carl Zeiss, Germany), B-scan echography to exclude retinal detachment, CECD by noncontact specular microscope (SP-3000P, Topcon, Japan), and anterior segment optical coherence tomography (AS-OCT, Visante, Carl Zeiss, Germany) in order to measure the incisional corneal thickness (ICT) and visualize the wound architecture.

After surgery, IOP measurement and AS-OCT scanning were performed at 2 hours, 1 week, 1 month and 3 months. ICT and wound architecture were assessed by AS-OCT, whose axial resolution is 18 μm. During the scanning, patients were asked to keep their eyes on the internal target. OCT scanning was taken three times for each eye at the same meridian of the incision in the mode of high-resolution corneal scan. The following parameters were obtained through the OCT images:

Wound architectures: Endothelial gaping (i.e., the existence of a gap on the endothelial side of the incision), epithelial gaping (i.e., the existence of a gap on the epithelial side of the incision), local

Parameter	Group 1 (n=25)	Group 2 (n=25)
System	Infiniti system (Alcon Laboratories, Inc.)	Infiniti system (Alcon Laboratories, Inc.)
Keratome	Diamond cutter 2.2 mm	Diamond cutter 3.0 mm
OVD	Duoviscoat (Alcon Laboratories, Inc.)	Duoviscoat (Alcon Laboratories, Inc.)
Implant system	Monarch® D cartridge	Monarch® C cartridge
Phaco Tip	45-degree, mini-flare, ABS, Kelman	45-degree, mini-flare, ABS, Kelman
MicroSmooth Sleeve	Micro-coaxial	Standard
Fluidic Management System	Intrepid FMS	Standard FMS
Phacoemulsification Setup		
Vacuum (mmHg)	360-400 linear	360-400 linear
Power (%)	Ozil continuous (torsional linear 50-100; phaco=0)	Ozil continuous (torsional linear 50-100; phaco=0)
Aspiration Rate	35 cc/min	35 cc/min
With IP software	Yes	Yes
Bottle Height (cm)	100	100

OVD: Ophthalmic Viscosurgical Device

Table 1: Surgical settings.

detachment of Descemet's membrane, loss of coaptation, and posterior wound retraction (Figure 1).

ICT: This was defined as the corneal thickness measured at the endothelial side of the main CCI (Figure 2). This measurement was taken manually using the caliper provided by the AS-OCT software. The postoperative change of ICT (ICT_d) was calculated as follows:

$$ICT_d = \frac{[\text{postoperative ICT} - \text{preoperative ICT}]}{\text{preoperative ICT}} \times 100\%$$

Since the location of the CCI, i.e. its distance from the corneal center, could not be identified preoperatively, it was determined at 3 months after surgery on the basis of the postoperative location.

Statistical analysis

The SPSS software package (version 19.0; SPSS Inc, Chicago, Illinois, USA) was used for statistical analysis. Ages, UST, CDE, AL, CECD, IOP, ICT, and ICT_d were compared using the independent samples t test. Fisher's exact test was used to compare the rate of wound architecture alterations. All statistical tests were 2-tailed with $\alpha=0.05$. A P value less than 0.05 was considered statistically significant.

Results

This study enrolled 50 eyes of 36 patients. There were 25 eyes for Group 1 and 25 eyes for Group 2. There were no significant differences between the 2 groups in the preoperative and intraoperative parameters before or during the surgery (Table 2).

Endothelial gapping

At 2 hours after surgery, endothelial gapping was seen more frequently in the 2.2 mm incision group (12 eyes, 48.0%) than in the 3.0 mm group (3 eyes, 12.0%, $P=0.012$) (Figure 3). At 1 week and one month the rate of endothelial gapping decreased to 28.0 and 8.0% in group 1 and to 12.0 and 8.0% in group 2. No statistically significant differences between the two groups were found at these time points. There was still 1 incision maintaining endothelial gapping 3 months postoperatively in 3.0 mm group, but not in the 2.2 mm group (Figure

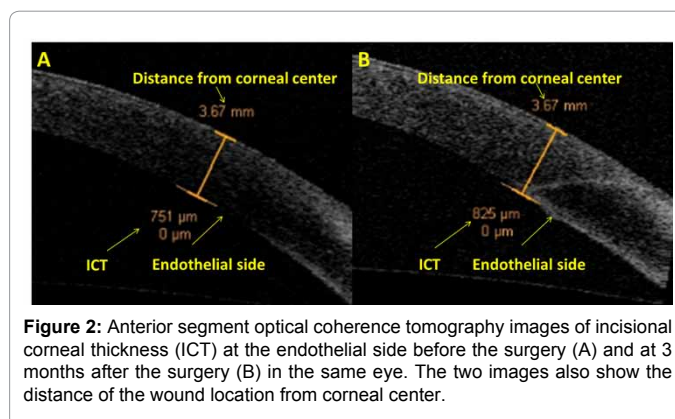


Figure 2: Anterior segment optical coherence tomography images of incisional corneal thickness (ICT) at the endothelial side before the surgery (A) and at 3 months after the surgery (B) in the same eye. The two images also show the distance of the wound location from corneal center.

Parameter	Group 1 (n=25)	Group 2 (n=25)	P Value
Mean age (years)±SD	71±11	75±8	0.133 ^a
Mean AL (mm) ±SD	24.04±1.59	23.89±1.18	0.561 ^a
Mean IOP (mmHg)±SD	14.5±3.5	12.8±3.3	0.100 ^a
Mean CECD (cells/mm ²)±SD	2365.2±159.1	2304.3±335.7	0.418 ^a
Mean UST (s)±SD	75.6±31.4	76.8±29.5	0.890 ^a
Mean CDE (%)±SD	22.5±12.4	25.1±12.9	0.944 ^a

AL: Axial Length; IOP: Intraocular pressure; UST: Ultrasound time; CECD: Center Endothelial Cell Density; CDE: Cumulative Dissipated Energy
^aIndependent samples t test
^bFisher's exact test

Table 2: Preoperative and intraoperative patient parameters.

3). For all cases, the mean IOP at 2 hours was lower in the eyes with endothelial gapping than in those without, although the difference between the 2 groups was not statistically significant (13.5 ± 8.0 mmHg vs 15.9 ± 4.9 mmHg, $P > .05$) (Table 3).

Epithelial gapping

At 2 hours after surgery, epithelial gapping was seen in 4 eyes (16.0%) in the 2.2 mm incision group and in 3 eyes (12.0%) in the 3.0 mm incision group (Figure 3); there were no statistically significant differences between the two groups. Epithelial gapping had recovered within 1 month after surgery in all eyes of both groups (Figure 3). There were no statistically significant differences in the mean IOP of 2 hours postoperatively between the eyes with and without epithelial gapping (Table 3).

Local detachment of Descemet's membrane

At 2 hours after surgery, local detachment of Descemet's membrane was observed in 18 eyes (72.0%) in both groups (Figure 3). At 1 week and one month the rate of Descemet's detachment decreased to 60.0 and 20.0% in group 1 and to 48.0 and 4.0% in group 2. At 3 months after surgery, it had recovered in the small-incision group, but could still be visualized in 1 eye in the microincision group (Figure 3). There was no statistically significant difference in the mean IOP at 2 hours postoperatively between the eyes with and without local detachment of Descemet's membrane (Table 3).

Loss of coaptation

Loss of coaptation could be observed in 4 eyes (16.0%) of both groups 2 hours postoperatively (Figure 3). Loss of coaptation had recovered within 1 week postoperatively in all eyes of the 2.2 mm incision group, but could still be seen in 1 eye belonging to the 3.0mm incision group (Figure 3). There were no statistically significant

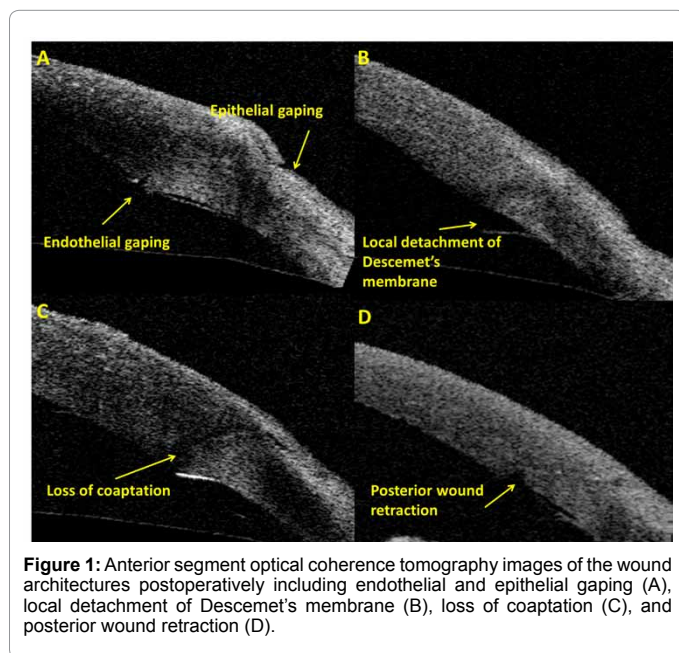


Figure 1: Anterior segment optical coherence tomography images of the wound architectures postoperatively including endothelial and epithelial gapping (A), local detachment of Descemet's membrane (B), loss of coaptation (C), and posterior wound retraction (D).

differences of the mean IOP at 2 hours postoperatively between the eyes with and without loss of coaptation (Table 3).

Posterior wound retraction

In the 2.2 mm incision group, posterior wound retraction was seen in 1 eye (4.0%) and in 3 eyes (12.0%) (Figure 3) at 2 hours and 1 week postoperatively; there was no eye with posterior wound retraction at 1 month and 3 months postoperatively. In the 3.0 mm incision group, there were no cases of posterior wound retraction at 2 hours and 2 eyes (8.0%) at 1 week after the surgery; posterior wound retraction could be seen in 1 eye (4.0%) at both 1 and 3 months after the surgery.

Incisional corneal thickness

At 2 hours and 1 week after surgery, the mean ICT_d was slightly higher in Group 2 (52.1 ± 12.5% and 46.4 ± 12.3%, respectively) than in Group 1 (51.4 ± 11.6% and 40.6 ± 15.1%, respectively), with no statistically significant differences. On the contrary, the ICT_d was statistically higher in Group 2 than Group 1 at 1 month (16.8 ± 10.0% vs 10.2 ± 5.8%, P = 0.007) and 3 months (12.1 ± 8.1% vs 6.0 ± 4.5%, P = 0.002) (Figure 4).

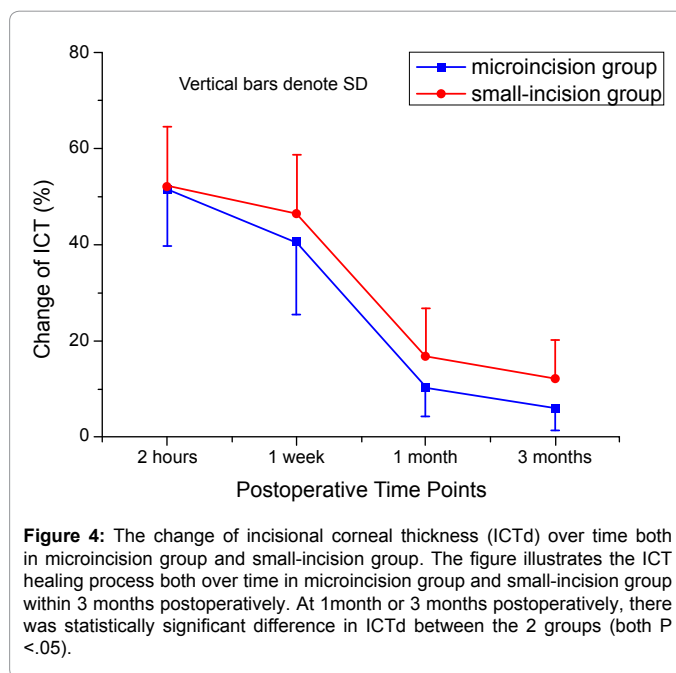


Figure 4: The change of incisional corneal thickness (ICTd) over time both in microincision group and small-incision group. The figure illustrates the ICT healing process both over time in microincision group and small-incision group within 3 months postoperatively. At 1 month or 3 months postoperatively, there was statistically significant difference in ICTd between the 2 groups (both P < .05).

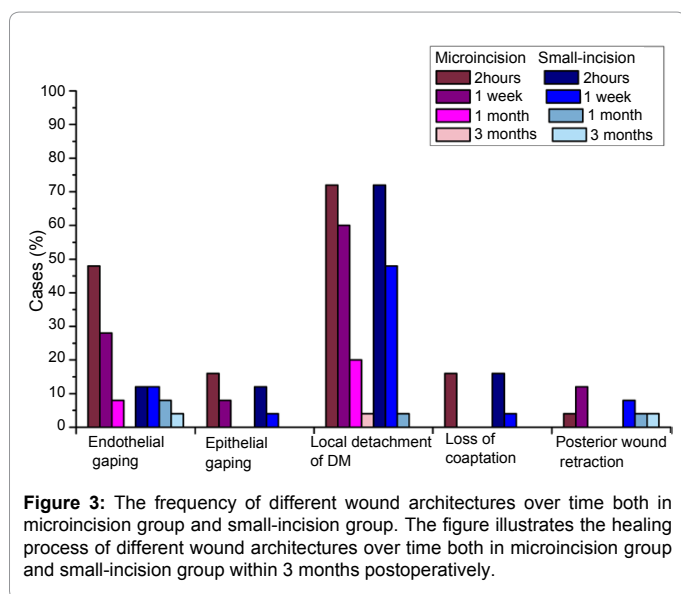


Figure 3: The frequency of different wound architectures over time both in microincision group and small-incision group. The figure illustrates the healing process of different wound architectures over time both in microincision group and small-incision group within 3 months postoperatively.

	Mean IOP at 2 hours ± SD (mmHg)	P Value ^a
Endothelial gapping		
Yes (n = 15)	13.5 ± 8.0	
No (n = 35)	15.9 ± 4.9	0.302
Epithelial gapping		
Yes (n = 7)	12.0 ± 6.7	
No (n = 43)	15.7 ± 5.9	0.132
Local detachment of Descemet's membrane		
Yes (n = 36)	15.6 ± 5.9	
No (n = 14)	14.3 ± 6.6	0.514
Loss of coaptation		
Yes (n = 8)	13.4 ± 4.7	
No (n = 42)	15.5 ± 6.3	0.372

IOP: Intraocular pressure
^aIndependent samples t test

Table 3: Mean IOP at 2 hours postoperatively in eyes with different wound architectures.

Discussion

After phacoemulsification, abnormalities of the wound architectures and increase of corneal thickness have been observed using OCT in several studies [13-15,17-20]. Those changes were also observed in this study, which for the first time evaluated the *in vivo* effect of torsional phacoemulsification through two different size incisions (2.2 and 3.0 mm) in eyes with hard nuclear cataract. Jun et al. [21] previously performed a similar study on human cadaver eyes and did not find any difference between 2.2 and 2.75 mm incisions when simulating torsional phacoemulsification. Their results, however, must be interpreted with caution due to the fact that the crystalline lens was not removed and no intraocular lens was actually implanted.

In our study the dynamic process of healing was recorded during 3 months postoperatively. Epithelial gapping and loss of coaptation recovered within 1 month after the surgery in all eyes, whereas endothelial gapping and local detachment of Descemet's membrane were still both found in CCI at 1 month or even at 3 months postoperatively.

Previous studies frequently reported cases of endothelial gapping, while epithelial gapping was found to be rare or none [13,14,22]. Our study is in good agreement with them, as shown by the higher incidence of endothelial vs epithelial gapping.

Endothelial gapping, which occurred more frequently in the eyes with the 2.2 mm incision, can be caused by thermal and mechanical damage to the incision [10]. The higher incidence in the microincision group is likely to depend on the smaller operating space for the surgical instruments and the subsequent increased risk of the undesirable thermal and mechanical effects of the phaco tip on the incision, as well as the mechanical stretching induced by the cartridge used to insert the intraocular lens. In addition, many studies suggested that a low IOP may play a role in endothelial gapping [14,17,23-26]. It has been hypothesized that the pressure from the lids may cause the CCI to bow inward in eyes with low IOP and lead to gapping at its endothelial side [13]. Accordingly, in this study the mean IOP at 2 hours postoperatively was lower in the group with endothelial gapping than in those without,

although there were no statistically significant differences (Table 3). On the contrary, a high IOP might push the CCI outward and lead to epithelial gaping [13], although Calladine et al. [13] did not find any correlation between the presence of epithelial gaping and IOP (Table 3). Our results agreed with the latter study. The reason might be that the IOP in our study was relatively normal.

Our study revealed that local detachment of Descemet's membrane is very common, a result in good agreement with previous investigations [13,14,17-19]. Such a detachment might be correlated to the stromal hydration performed in all eyes and the subsequent mechanical forces exerted on the Descemet's membrane [14]. No statistically significant difference was found in the rate of occurrence between the groups of microincision and small-incision. Chee et al. [19] also reported that the incision size should not play an important role in the occurrence of Descemet detachment when the phacoemulsification tips are appropriately sized. The detachment might be caused by unintentional stripping during initial construction of the main incision or insertion of the instruments during the procedure [13]. In addition, Calladine et al. [13] found it was more likely to occur in eyes with lower IOP. The possible explanation was that the detached Descemet's membrane could be pushed back onto the exposed corneal surface by higher IOP [13]. Nevertheless, it was not the case in the study by Chee et al. [19]. They found the occurrence of Descemet's detachment was not related to the mean IOP at all time points. Our results also agreed to them and we found no statistically significant differences in the mean IOP between the eyes with and without Descemet's detachment. It was reported that small amounts of Descemet's membrane detachment rarely could lead to extensive spontaneous peeling of the membrane [13]. In our study, we didn't see any extension of detachment over time and no special treatments were required.

We found the same incidence (16.0%) of loss of coaptation in the two groups of eyes (Figure 3). Loss of coaptation, as imaged by OCT, is known to occur in the event of leaking wounds [14]. Calladine et al. [13] reported that loss of coaptation in CCI might influence wound structural integrity and increase the risk of endophthalmitis. They observed that it was more likely to occur in eyes with low postoperative IOP. On the contrary, Agarwal et al. [12] did not observe any statistically significant difference in the mean IOP between the eyes with and without loss of coaptation, a finding similar to our results (Table 3). The reason for the discrepancy between ours and Calladine's et al. results might be that the IOP in this study was relatively normal and was examined at 2 hours after surgery instead of the immediate (30-minute) postoperative period [12,13].

The incidence of wound retraction in our study (0-12.0%) was considerably lower than the corresponding values found in the literature. Wang et al. [18] reported that posterior wound retraction could not be seen within 2 weeks after the surgery, but the rate significantly increased from 33.3% at 2 to 3 weeks to 90.5% at 3 to 15 years. In addition, Cavallini et al. [27] found that the prevalence of posterior wound retraction increased from 23.5% at 2 to 7 months to 30.5% at 8 to 10 months and to 32.3% at 11 to 16 months. The discrepancy between our results and those previously reported might be related to the short-term nature and small sample size of our investigation.

In order to measure the ICT, we had to determine the exact location of the CCI on the endothelial side. Since preoperatively the location of the CCI, i.e. the distance from the corneal center, was unknown, we determined it according to the location of the CCI at 3 months after the surgery (we observed that the CCI location varied over time during the

3 months postoperatively due to the healing process of wound edema). The ICT_d decreased over time within three months in both groups, but the mean values remained statistically higher in the 3.0 mm group at 1 and 3 months (Figure 3). No studies have reported the exact location of the preoperative ICT.

Other authors previously evaluated the effects of incision size on the incisional corneal edema after phacoemulsification for high-density cataracts. At 1 week after surgery, Kim et al. [15] found that the 2.75 mm incision caused less edema than the smaller incisions (1.8 mm or 2.2 mm incisions); the difference was no more statistically significant at 1 and 2 months after surgery. Unfortunately they did not assess earlier changes at 2 hours. Their findings are different compared to ours, since we found a higher edema in eyes with larger incision. Possible explanations of such a difference may include the use of a different technology to remove the lens (torsional phacoemulsification in our study, standard US phacoemulsification in their study), and a different method to measure the ICT (Kim et al. did not clearly mention the method to measure the preoperative ICT).

As a possible limitation, this study did not include a control group of eyes receiving standard longitudinal US phacoemulsification. However, since it has been already shown that US phacoemulsification induces higher CDE, higher incisional edema and higher endothelial cell loss in the first postoperative month [3], we felt that such a control group would have not lead to better results than ours.

In conclusion, we found that torsional phacoemulsification of hard cataracts can be safely performed through a 2.2 mm and a 3.0 mm incision. Although the former increases the risk of endothelial gaping occurrence in the very early stage, and the latter induces a higher degree of incisional corneal edema, the CCI architecture integrity was mainly recovered at one month in both groups.

Acknowledgements

The authors have no proprietary interest in any materials or methods described within this article. This study had non-government support.

References

- Wallin T, Parker J, Jin Y, Kefalopoulos G, Olson RJ (2005) Cohort study of 27 cases of endophthalmitis at a single institution. *J Cataract Refract Surg* 31: 735-741.
- Cooper BA, Holekamp NM, Bohigian G, Thompson PA (2003) Case-control study of endophthalmitis after cataract surgery comparing scleral tunnel and clear corneal wounds. *Am J Ophthalmol* 136: 300-305.
- Zeng M, Liu X, Liu Y, Xia Y, Luo L, et al. (2008) Torsional ultrasound modality for hard nucleus phacoemulsification cataract extraction. *Br J Ophthalmol* 92: 1092-1096.
- Liu Y, Zeng M, Liu X, Luo L, Yuan Z, et al. (2007) Torsional mode versus conventional ultrasound mode phacoemulsification: randomized comparative clinical study. *J Cataract Refract Surg* 33: 287-292.
- de Castro LE, Dimalanta RC, Solomon KD (2010) Bead-flow pattern: quantitation of fluid movement during torsional and longitudinal phacoemulsification. *J Cataract Refract Surg* 36: 1018-1023.
- Davison JA (2008) Cumulative tip travel and implied followability of longitudinal and torsional phacoemulsification. *J Cataract Refract Surg* 34: 986-990.
- Cionni RJ, Crandall AS, Felsted D (2011) Length and frequency of intraoperative occlusive events with new torsional phacoemulsification software. *J Cataract Refract Surg* 37: 1785-1790.
- Linebarger EJ, Hardten DR, Shah GK, Lindstrom RL (1999) Phacoemulsification and modern cataract surgery. *Surv Ophthalmol* 44: 123-147.
- Tong N, He JC, Lu F, Wang Q, Qu J, et al. (2008) Changes in corneal wavefront aberrations in microincision and small-incision cataract surgery. *J Cataract Refract Surg* 34: 2085-2090.

10. Can I, Bayhan HA, Celik H, BostancÄ, Ceran B (2011) Anterior segment optical coherence tomography evaluation and comparison of main clear corneal incisions in microcoaxial and biaxial cataract surgery. *J Cataract Refract Surg* 37: 490-500.
11. Osher RH, Injev VP (2006) Thermal study of bare tips with various system parameters and incision sizes. *J Cataract Refract Surg* 32: 867-872.
12. Agarwal A, Kumar DA, Jacob S, Agarwal A (2008) In vivo analysis of wound architecture in 700 microm microphakonit cataract surgery. *J Cataract Refract Surg* 34: 1554-1560.
13. Calladine D, Packard R (2007) Clear corneal incision architecture in the immediate postoperative period evaluated using optical coherence tomography. *J Cataract Refract Surg* 33: 1429-1435.
14. Calladine D, Tanner V (2009) Optical coherence tomography of the effects of stromal hydration on clear corneal incision architecture. *J Cataract Refract Surg* 35: 1367-1371.
15. Kim EC, Byun YS, Kim MS (2011) Microincision versus small-incision coaxial cataract surgery using different power modes for hard nuclear cataract. *J Cataract Refract Surg* 37: 1799-1805.
16. Chylack LT Jr, Wolfe JK, Singer DM, Leske MC, Bullimore MA, et al. (1993) The Lens Opacities Classification System III. The Longitudinal Study of Cataract Study Group. *Arch Ophthalmol* 111: 831-836.
17. Xia Y, Liu X, Luo L, Zeng Y, Cai X, et al. (2009) Early changes in clear cornea incision after phacoemulsification: an anterior segment optical coherence tomography study. *Acta Ophthalmol* 87: 764-768.
18. Wang L, Dixit L, Weikert MP, Jenkins RB, Koch DD (2012) Healing changes in clear corneal cataract incisions evaluated using Fourier-domain optical coherence tomography. *J Cataract Refract Surg* 38: 660-665.
19. Chee SP, Ti SE, Lim L, Chan AS, Jap A (2010) Anterior segment optical coherence tomography evaluation of the integrity of clear corneal incisions: a comparison between 2.2-mm and 2.65-mm main incisions. *Am J Ophthalmol* 149: 768-776.
20. Li YJ, Kim HJ, Joo CK (2011) Early changes in corneal edema following torsional phacoemulsification using anterior segment optical coherence tomography and Scheimpflug photography. *Jpn J Ophthalmol* 55: 196-204.
21. Jun B, Berdahl JP, Kuo AN, Cummings TJ, Kim T (2010) Corneal wound architecture and integrity after torsional and mixed phacoemulsification: evaluation of standard and microincisional coaxial techniques. *Ophthalmic Surg Lasers Imaging* 41: 128-134.
22. Elkady B, Piñero D, Alió JL (2009) Corneal incision quality: microincision cataract surgery versus microcoaxial phacoemulsification. *J Cataract Refract Surg* 35: 466-474.
23. McDonnell PJ, Taban M, Sarayba M, Rao B, Zhang J, et al. (2003) Dynamic morphology of clear corneal cataract incisions. *Ophthalmology* 110: 2342-2348.
24. Masket S, Belani S (2007) Proper wound construction to prevent short-term ocular hypotony after clear corneal incision cataract surgery. *J Cataract Refract Surg* 33: 383-386.
25. Torres LF, Saez-Espinola F, Colina JM, Retchkiman M, Patel MR, et al. (2006) In vivo architectural analysis of 3.2 mm clear corneal incisions for phacoemulsification using optical coherence tomography. *J Cataract Refract Surg* 32: 1820-1826.
26. Taban M, Rao B, Reznik J, Zhang J, Chen Z, et al. (2004) Dynamic morphology of sutureless cataract wounds--effect of incision angle and location. *Surv Ophthalmol* 49 Suppl 2: S62-72.
27. Cavallini GM, Campi L, Torlai G, Forlini M, Fornasari E (2012) Clear corneal incisions in bimanual microincision cataract surgery: long-term wound-healing architecture. *J Cataract Refract Surg* 38: 1743-1748.

Citation: Ding X, Chang P, Savini G, Huang J, Wang Q, et al. (2013) Clear Corneal Incision Architecture Imaging after Torsional Phacoemulsification of Hard Nuclear Cataract through a 2.2 mm and a 3.0 mm Large Tunnel. *J Clin Exp Ophthalmol* 4: 279. doi:[10.4172/2155-9570.1000279](https://doi.org/10.4172/2155-9570.1000279)

Submit your next manuscript and get advantages of OMICS Group submissions

Unique features:

- User friendly/feasible website-translation of your paper to 50 world's leading languages
- Audio Version of published paper
- Digital articles to share and explore

Special features:

- 250 Open Access Journals
- 20,000 editorial team
- 21 days rapid review process
- Quality and quick editorial, review and publication processing
- Indexing at PubMed (partial), Scopus, DOAJ, EBSCO, Index Copernicus and Google Scholar etc
- Sharing Option: Social Networking Enabled
- Authors, Reviewers and Editors rewarded with online Scientific Credits
- Better discount for your subsequent articles

Submit your manuscript at: www.editorialmanager.com/clinicalgroup

